



Amman, Jordan 2018

XXXII International Academy of Pathology Congress

CARTILAGE LESIONS OF BONE BENIGN OR MALIGNANT?

RICARDO K. KALIL, MD

A C CAMARGO CANCER CENTER

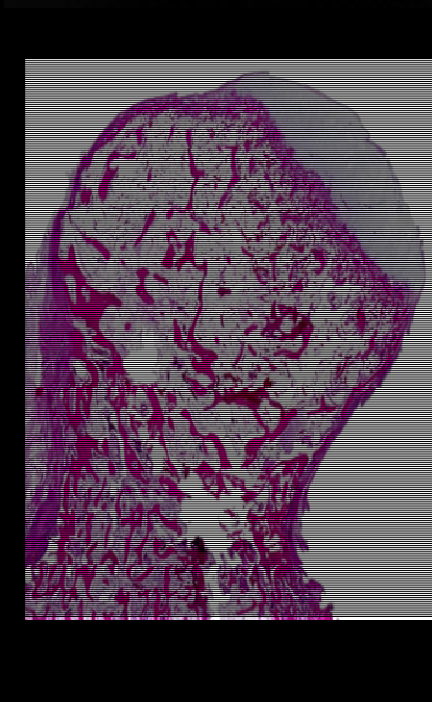
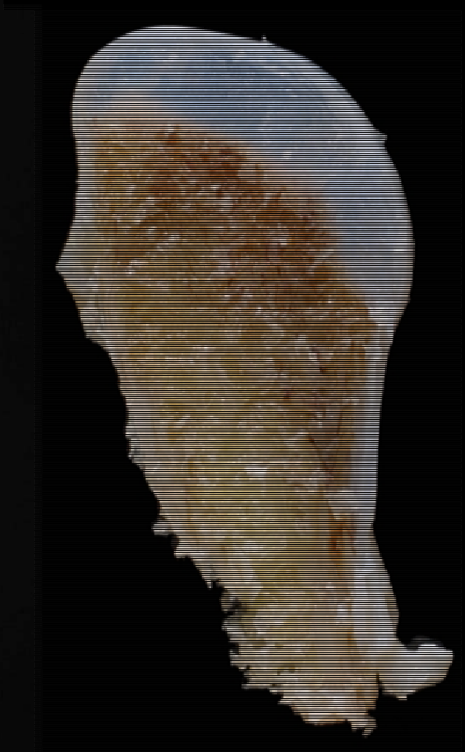
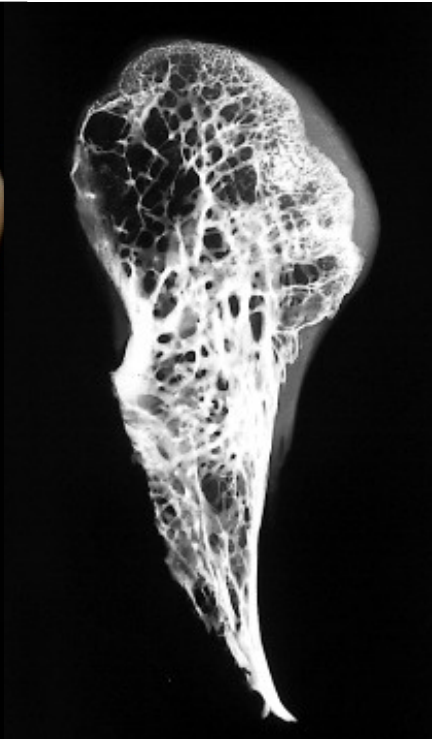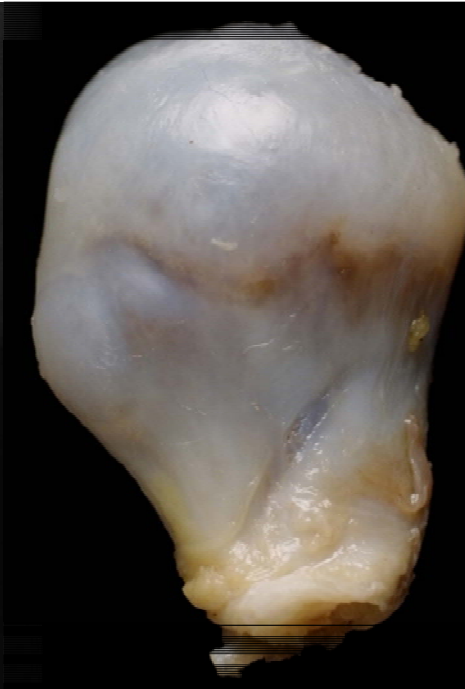
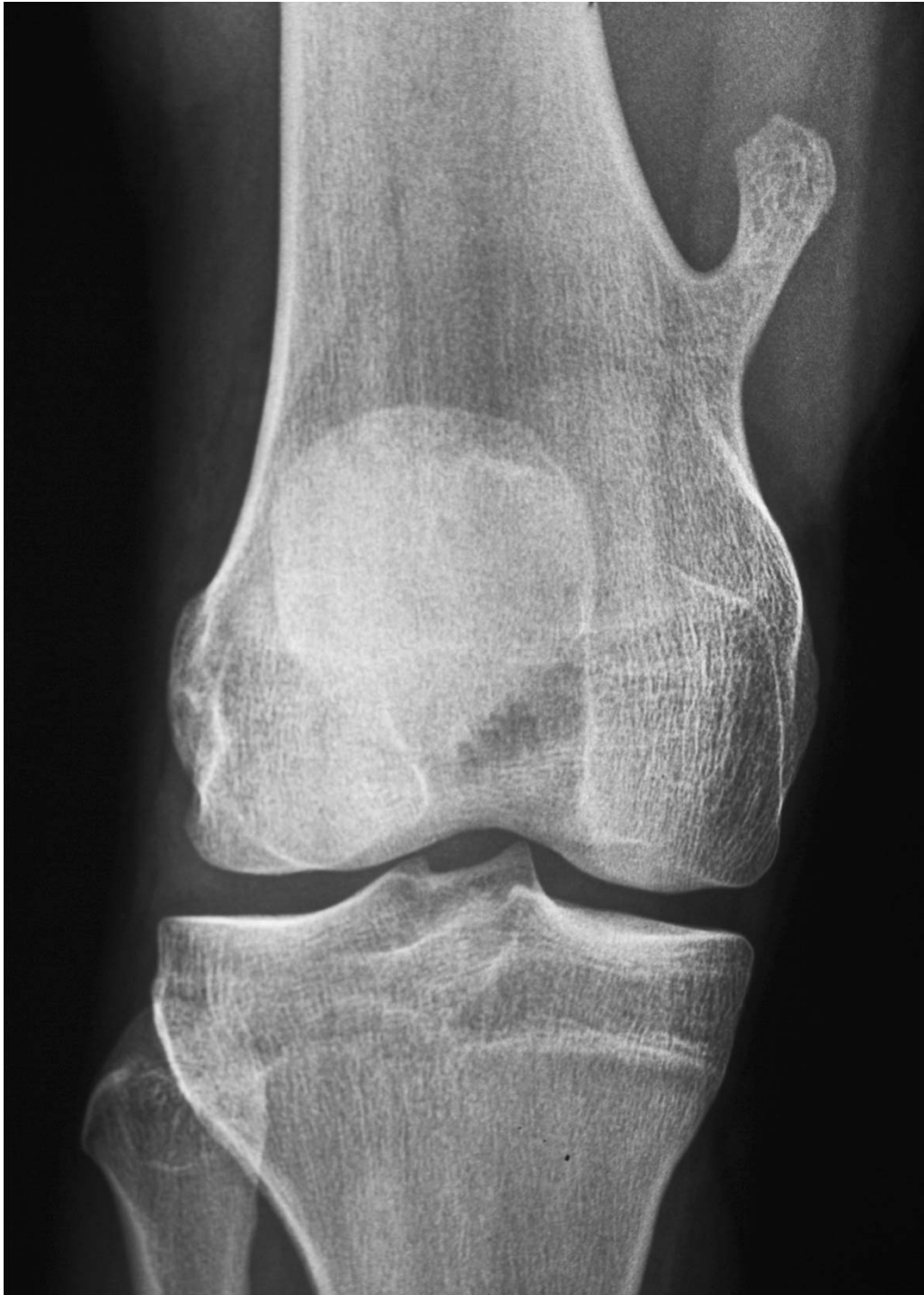SÃO PAULO, BRAZIL

“Chondrosarcoma is one of the most difficult of the malignant tumors of bone for the pathologist to diagnose”



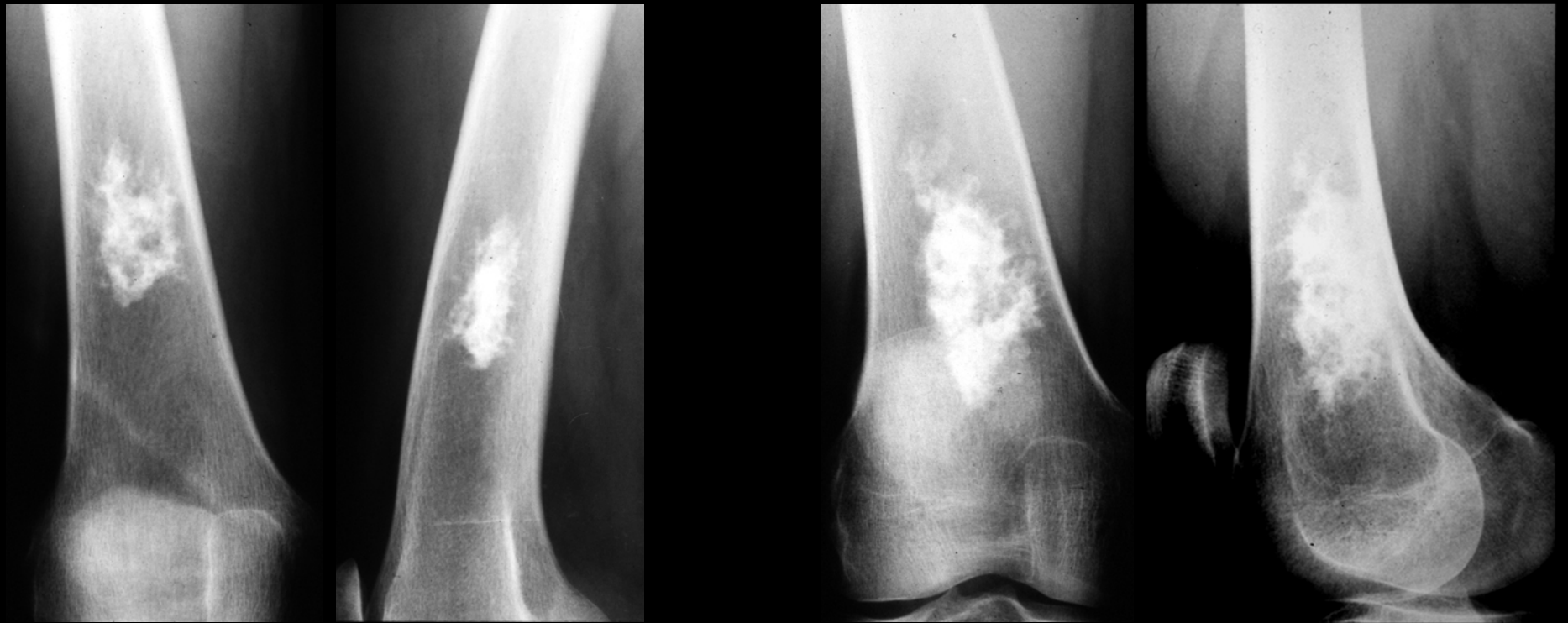K. K. Unni

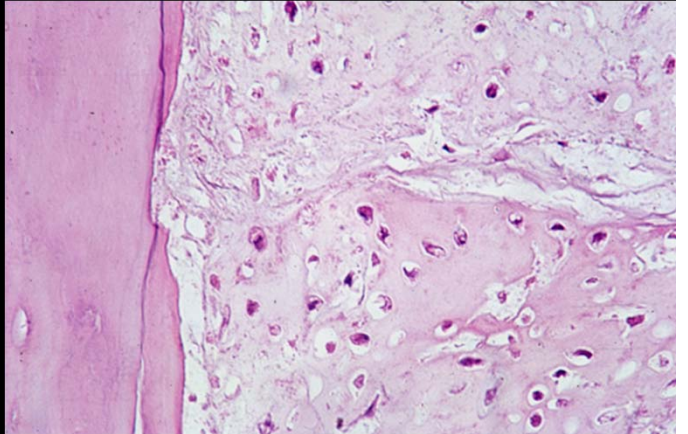
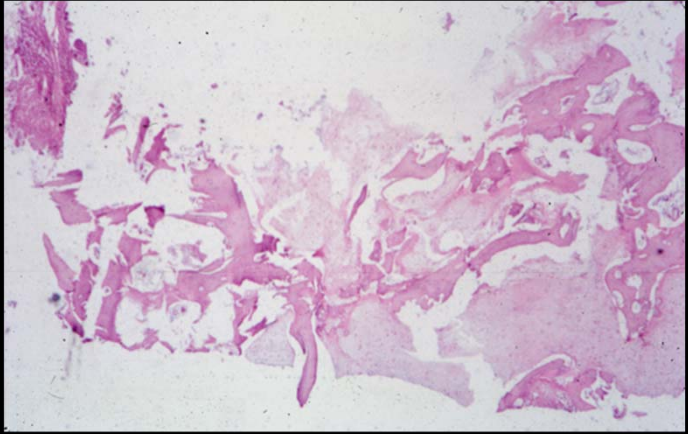
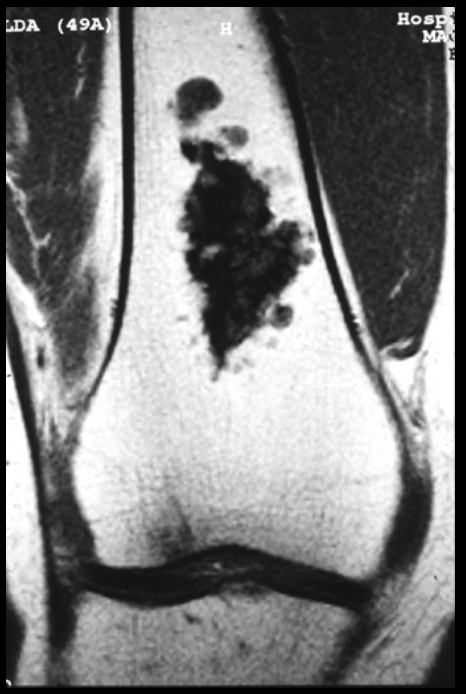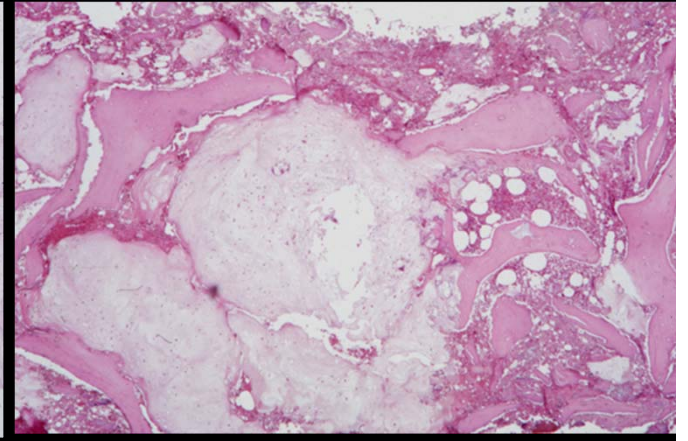
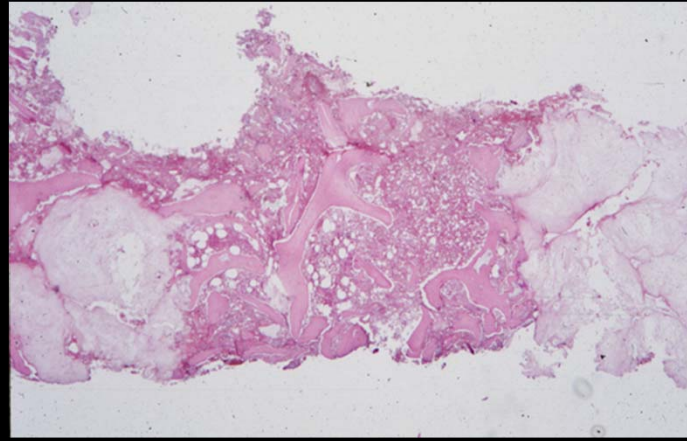
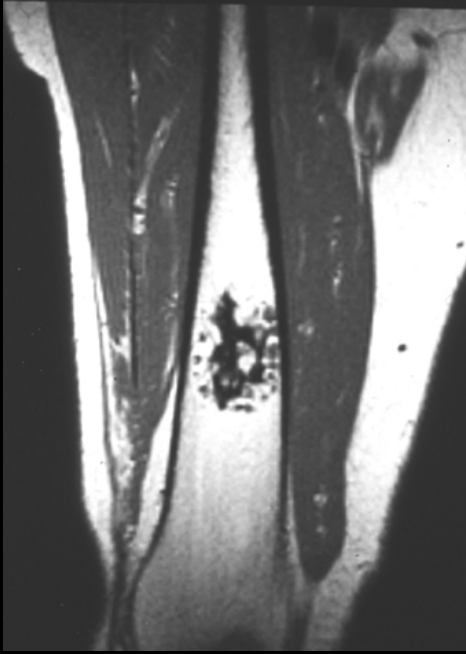
Dahlin's BONE TUMORS - 6th ed





CHONDROMA
X
LOW GRADE CHONDROSARCOMA







 **A.C. Camargo Cancer Center**
Centro Integrado de Diagnóstico, Tratamento, Ensino e Pesquisa

NEXT FRONTIERS TO CURE CANCER

2017

NEXT FRONTIERS
TO CURE CANCER
2017

DR. EDUARDO SANTINI-ARAUJO

"BORDERLINE CARTILAGINOUS NEOPLASIA"

*"CARTILAGINOUS NEOPLASIA OF UNDEFINED
MALIGNANT POTENTIAL*

*THE DIFFERENTIAL DIAGNOSIS IS BETWEEN A
CHONDROMA AND A GRADE I
CHONDROSARCOMA, NOT POSSIBLE TO
DEFINE IN THIS SAMPLE"*

***“WELL-DIFFERENTIATED CARTILAGINOUS
NEOPLASIA”***

*FINAL DIAGNOSIS NEEDS CORRELATION WITH
CLINICAL AND IMAGING DATA.*

CHONDROSARCOMA

CHS CENTRAL, PRIMARY AND SECONDARY

CHS PERIPHERIC, PRIMARY AND SECONDARY

VARIANTS:

CHS DEDIFFERENTIATED

CHS MESENCHYMAL

CHS CLEAR CELL

CONVENTIONAL CHONDROSARCOMA

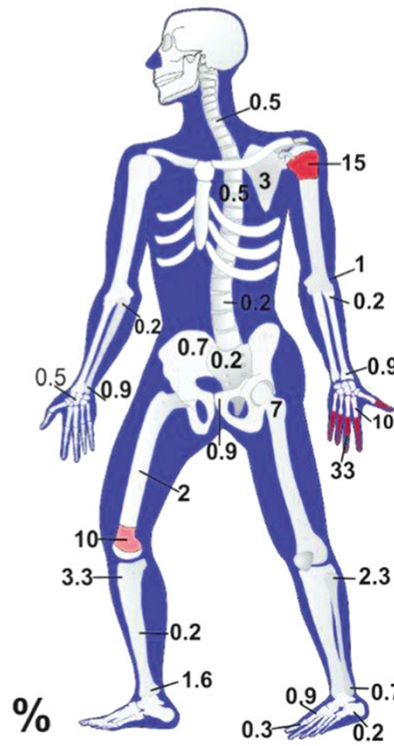
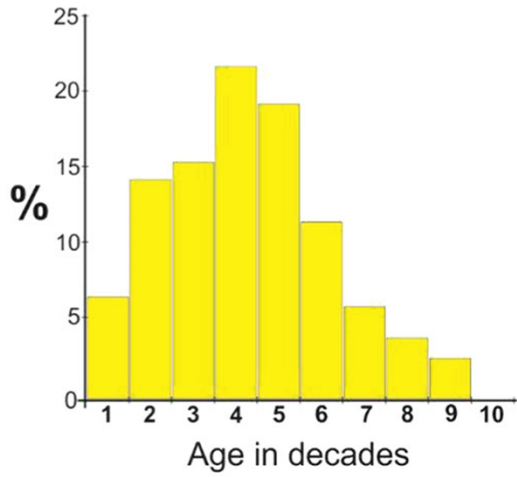
85% OF CHS CASES ARE CONVENTIONAL – MADE OF HYALIN CARTILAGE IN VARIOUS GRADES OF DIFFERENTIATION.

90% - CENTRAL (MEDULLARY)

10% - PERIPHERAL (SURFACE OR PERIOSTEAL)

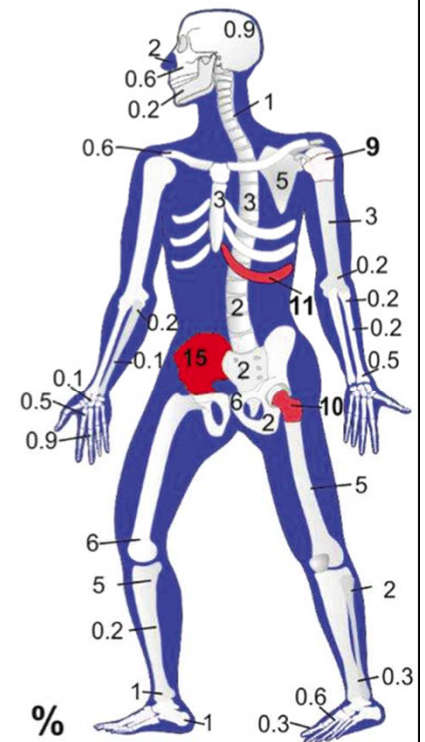
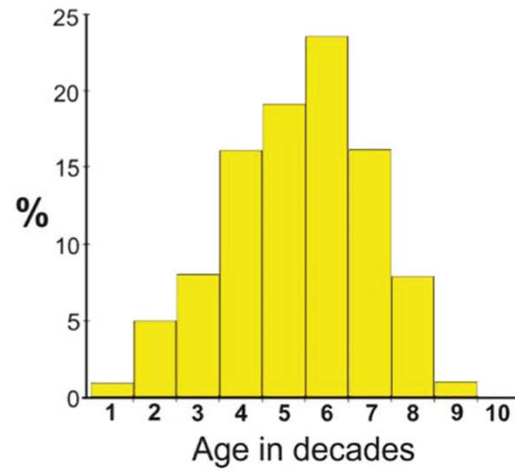
Enchondroma

Sex	%
Male	40
Female	60



Chondrosarcoma

Sex	%
Male	57
Female	43



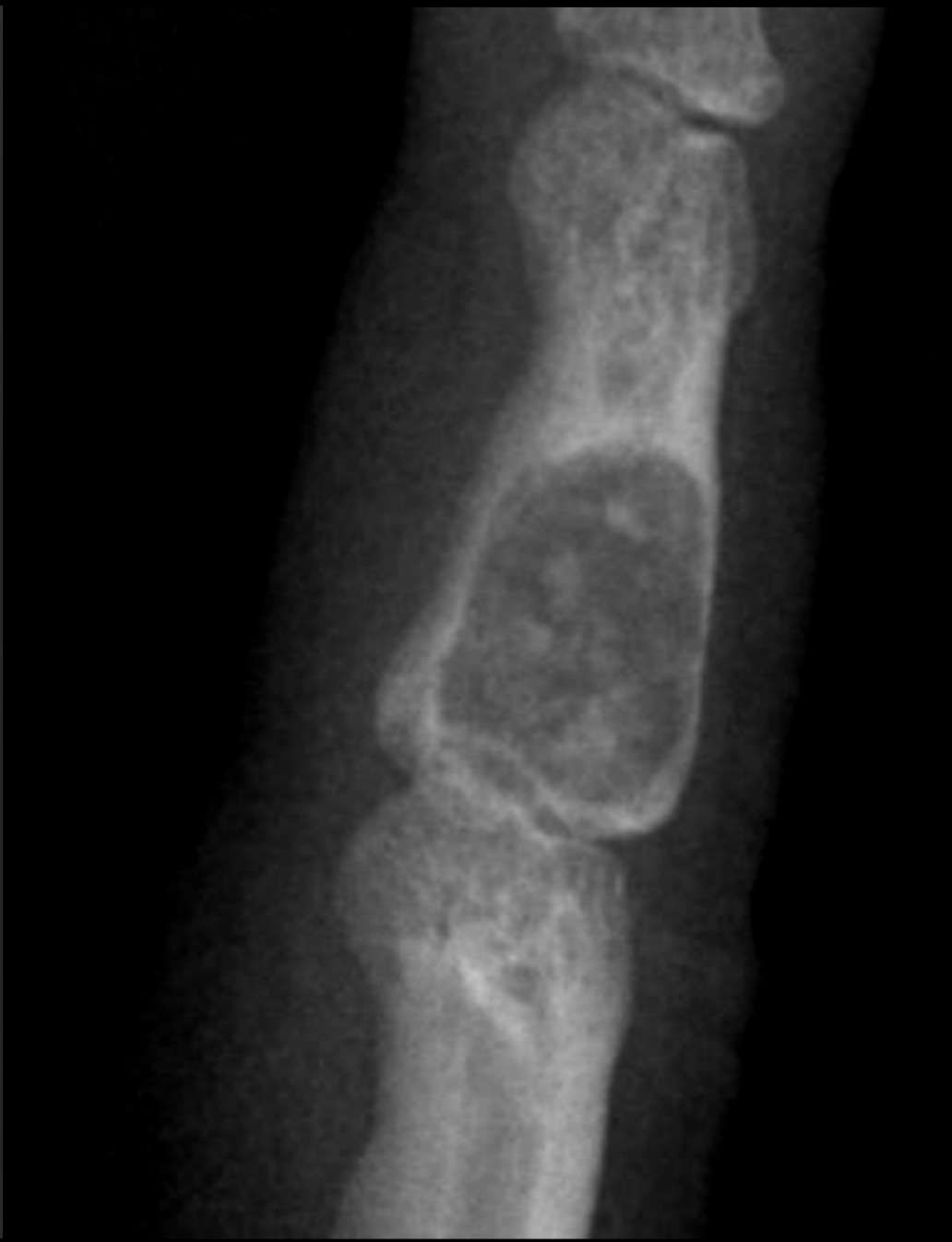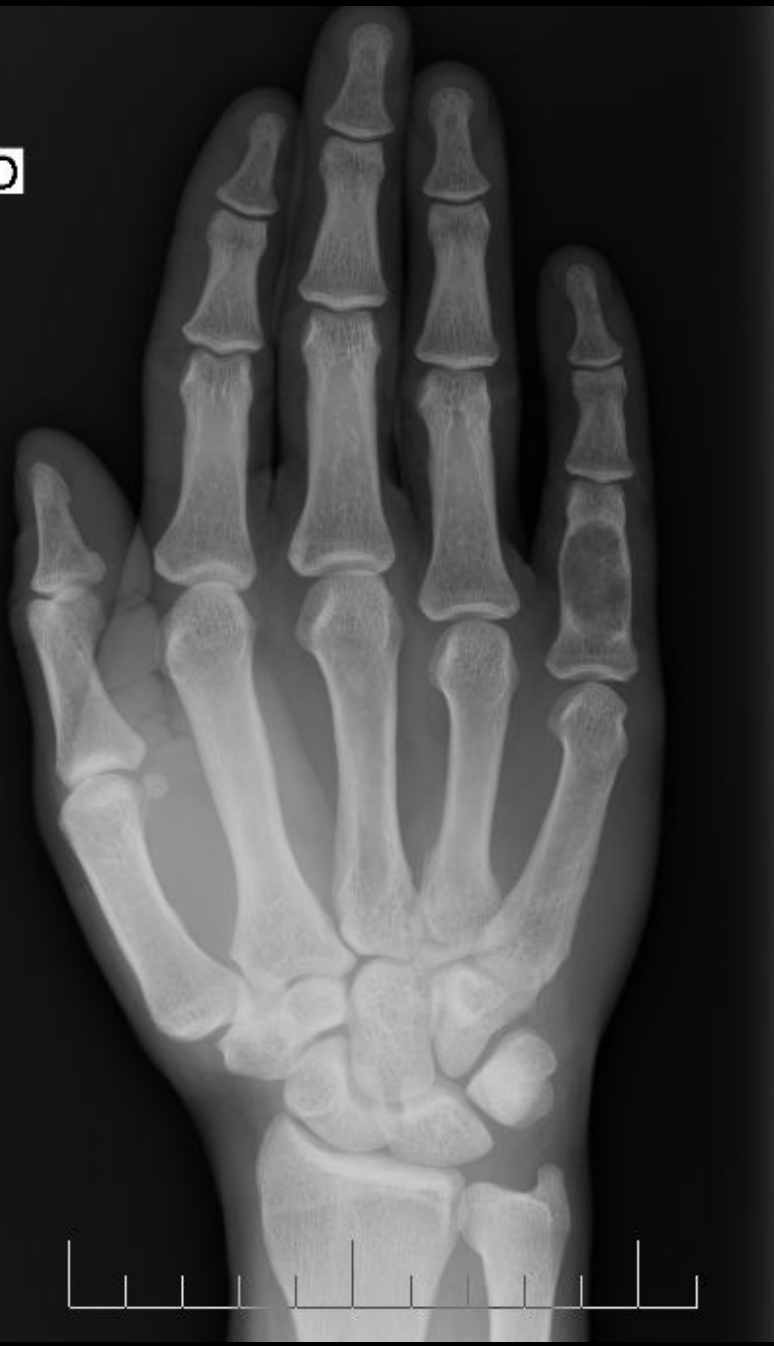CARTILAGINOUS TUMORS

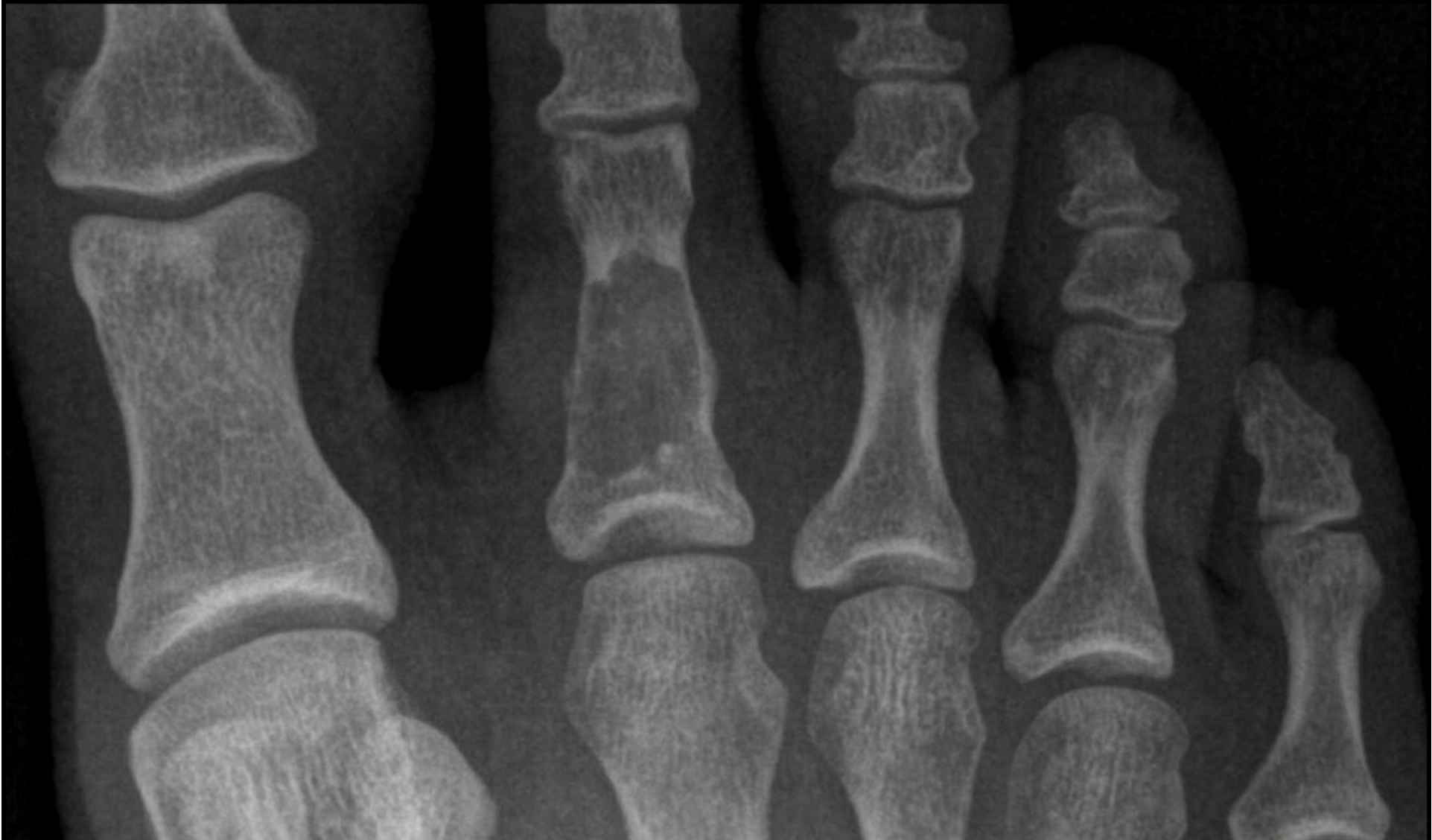- in hands and feet.
- in a subperiosteal location.
- in the lining of capsules of joints.

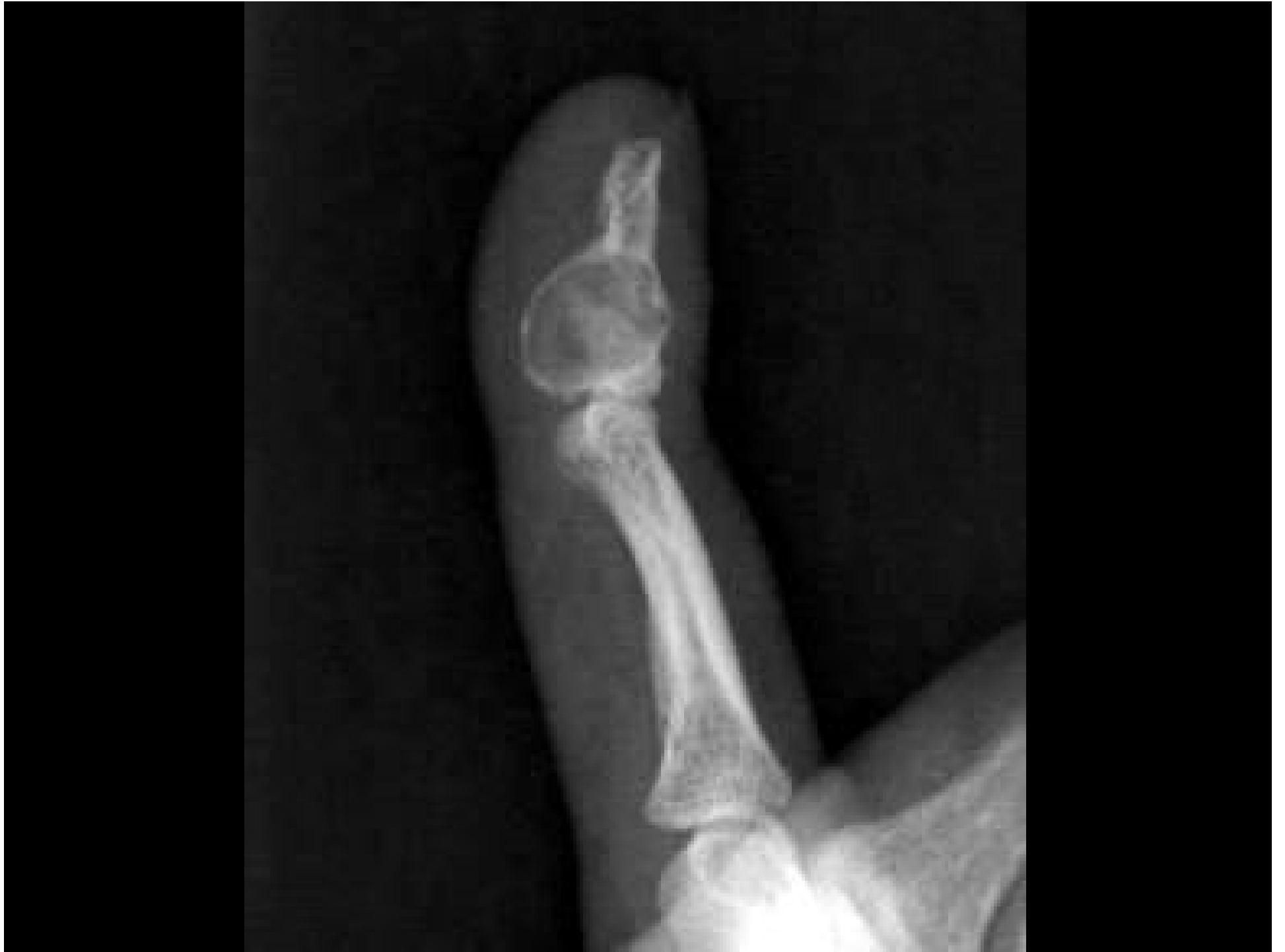**are almost certain to be
clinically benign**

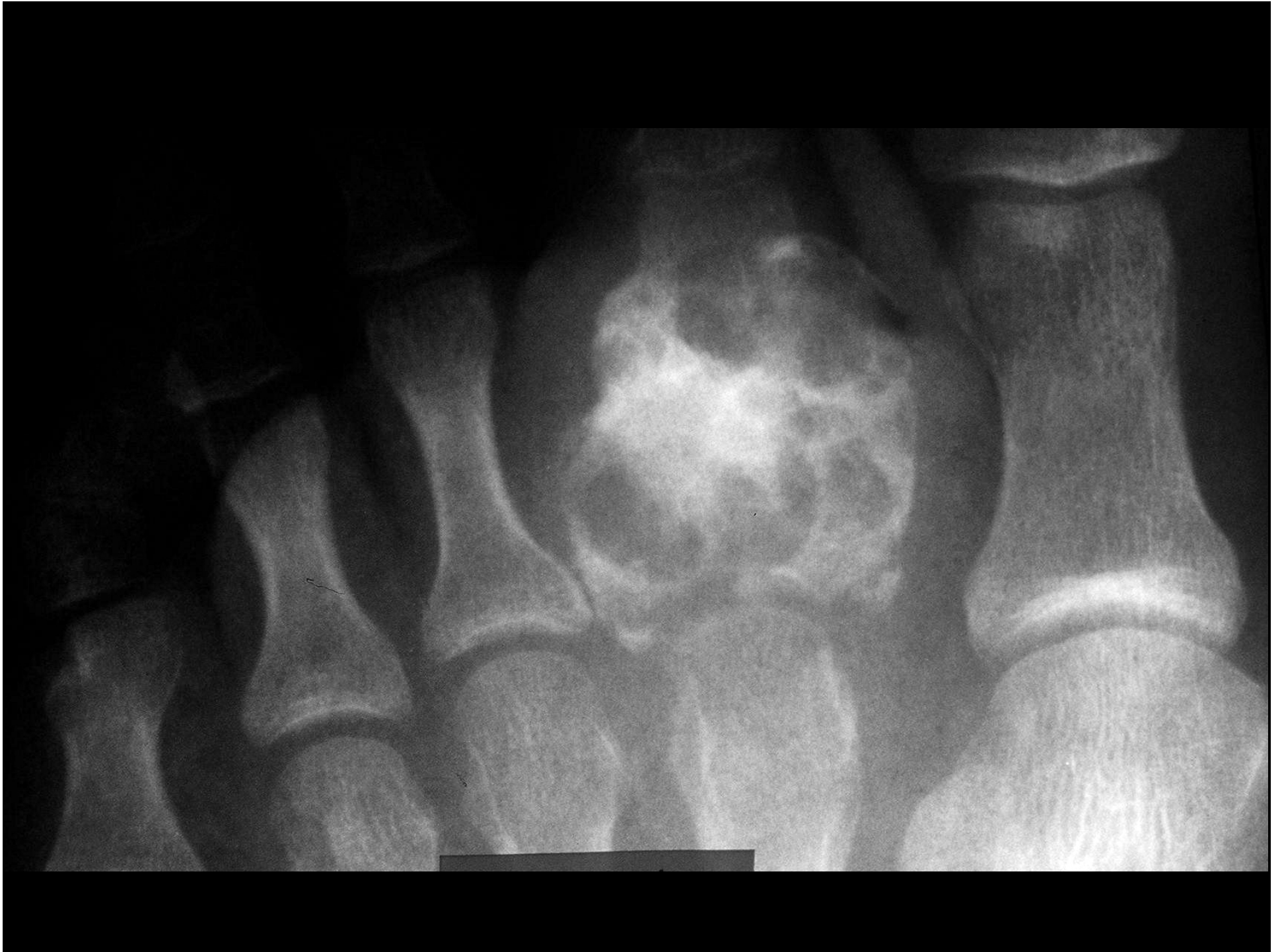ENCHONDROMA

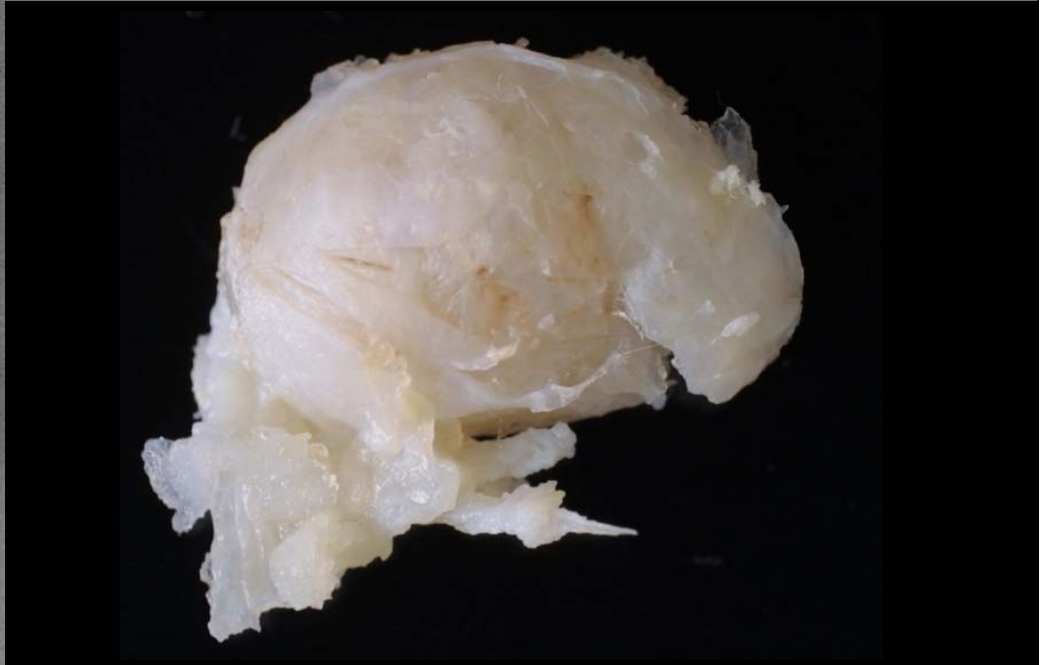
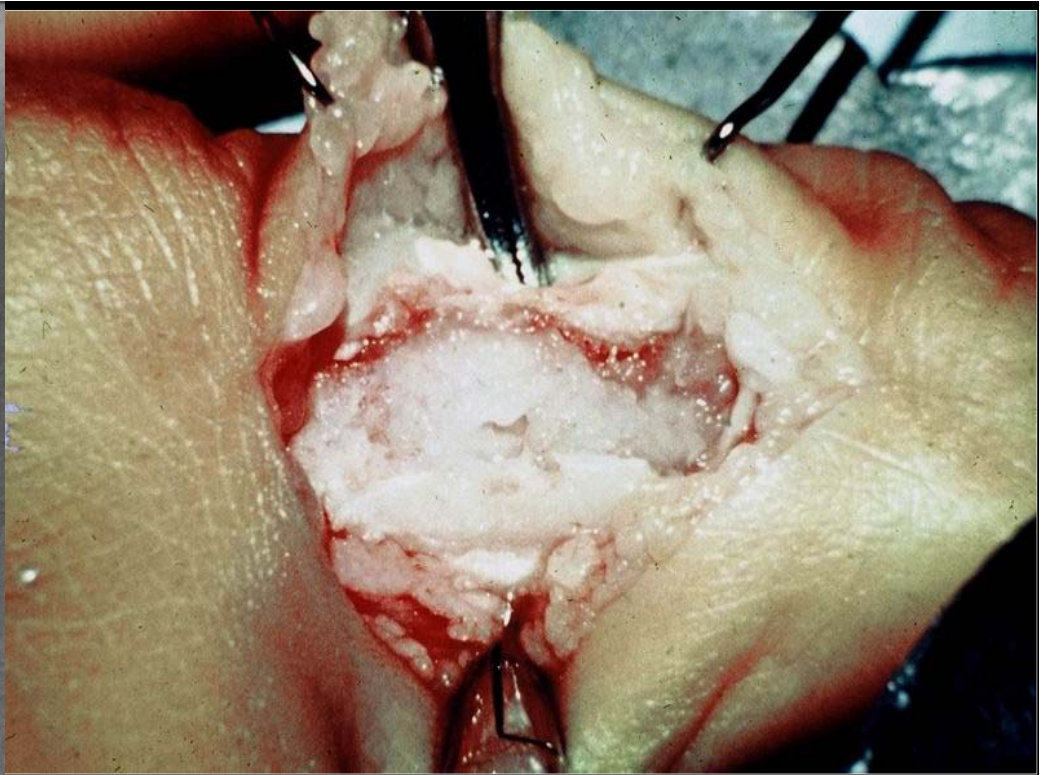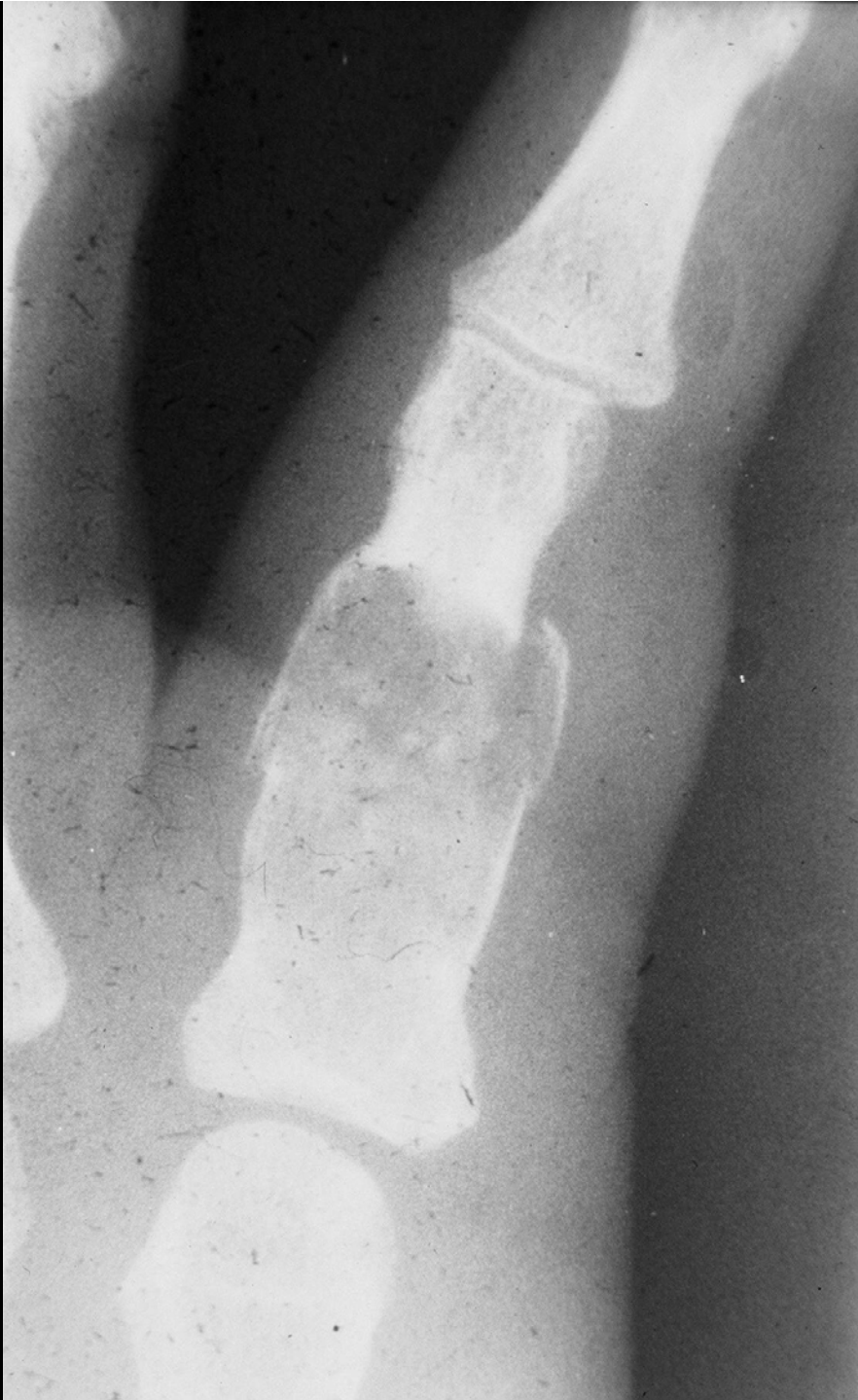D



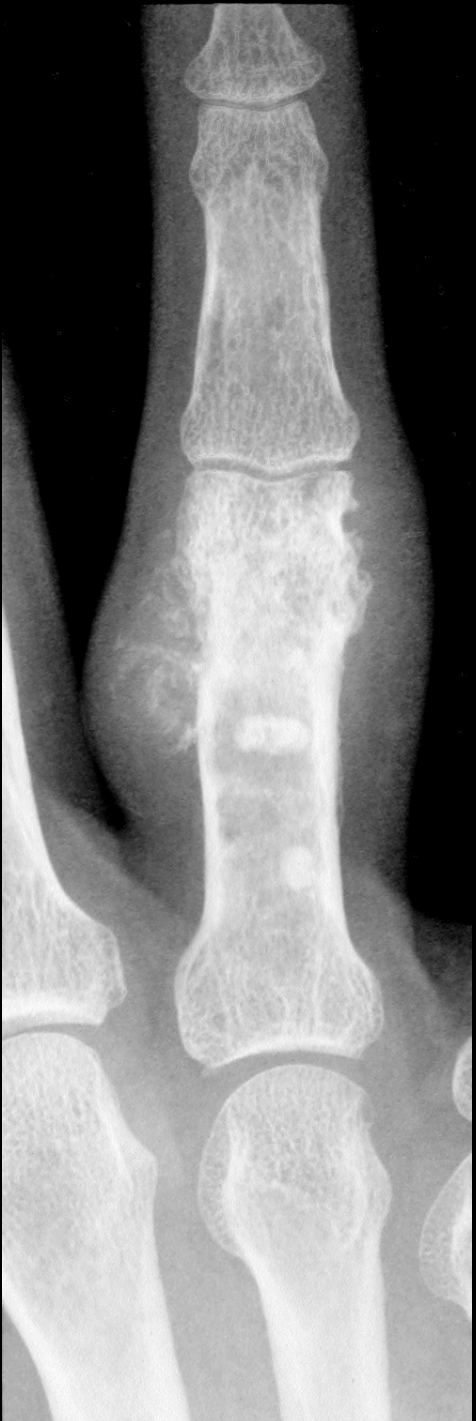
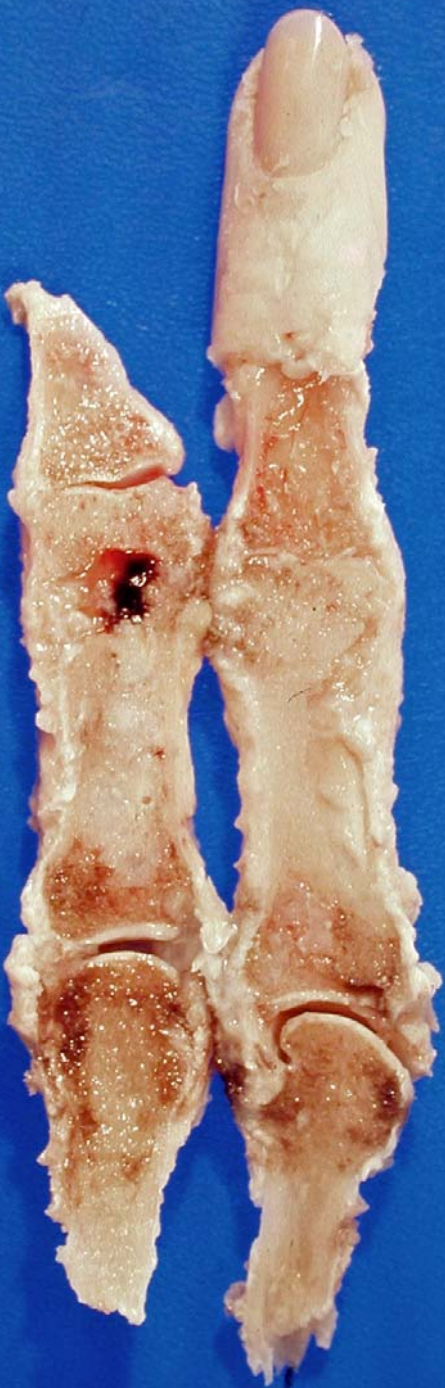
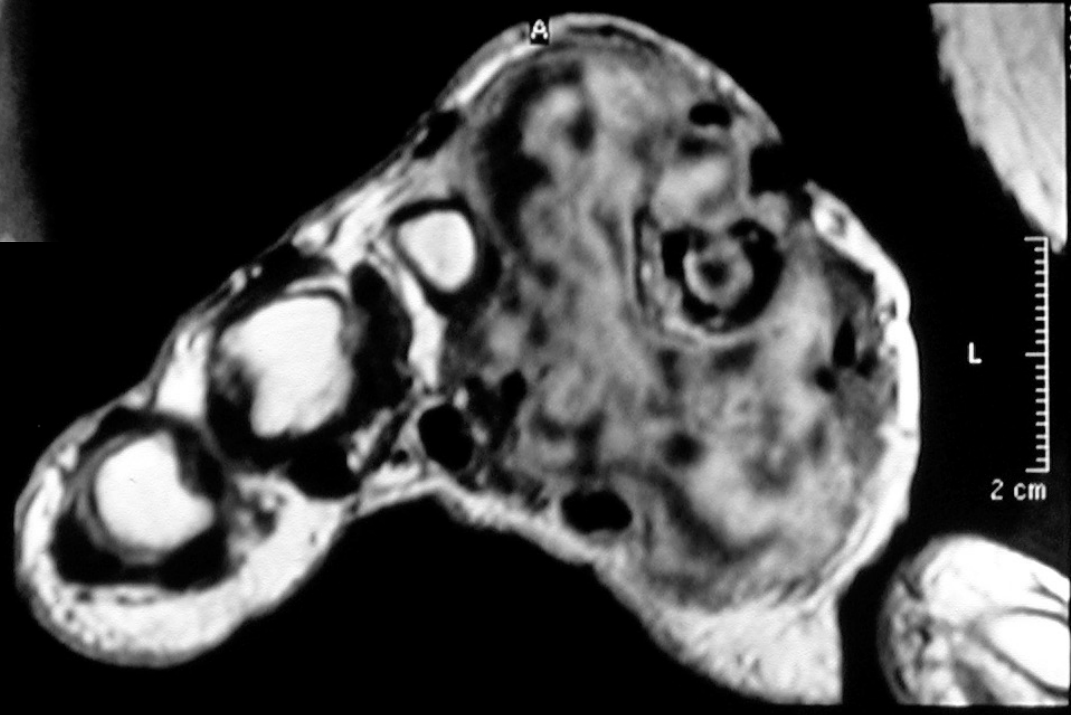


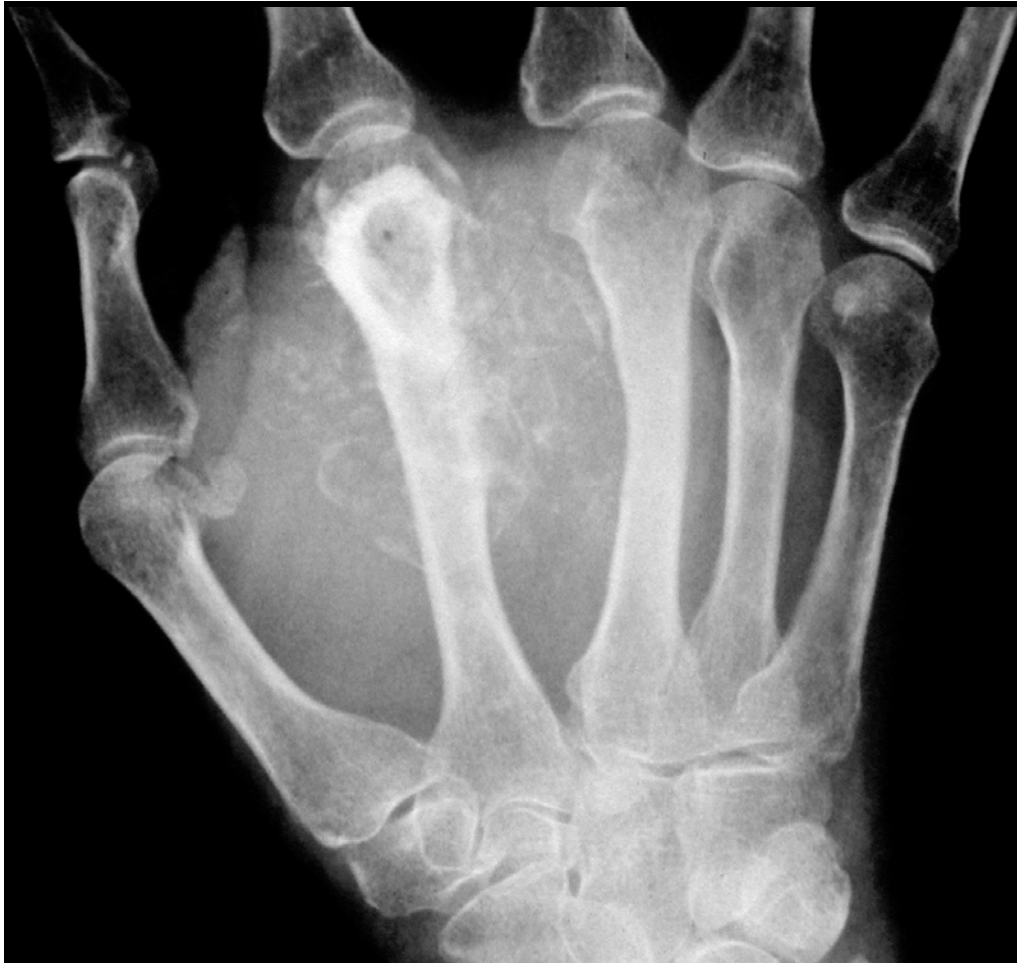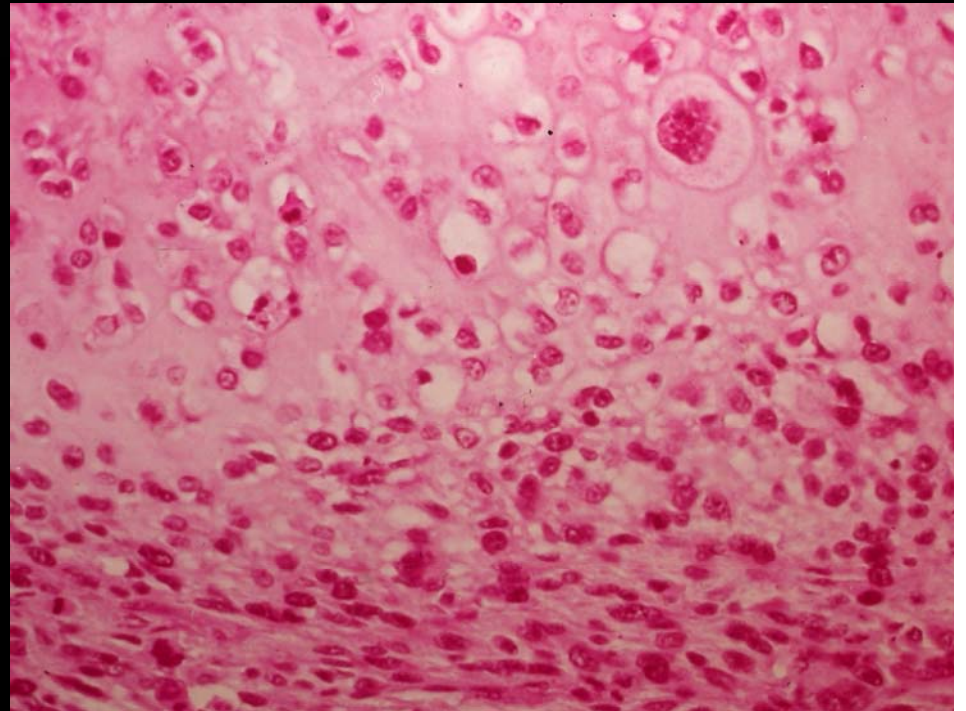
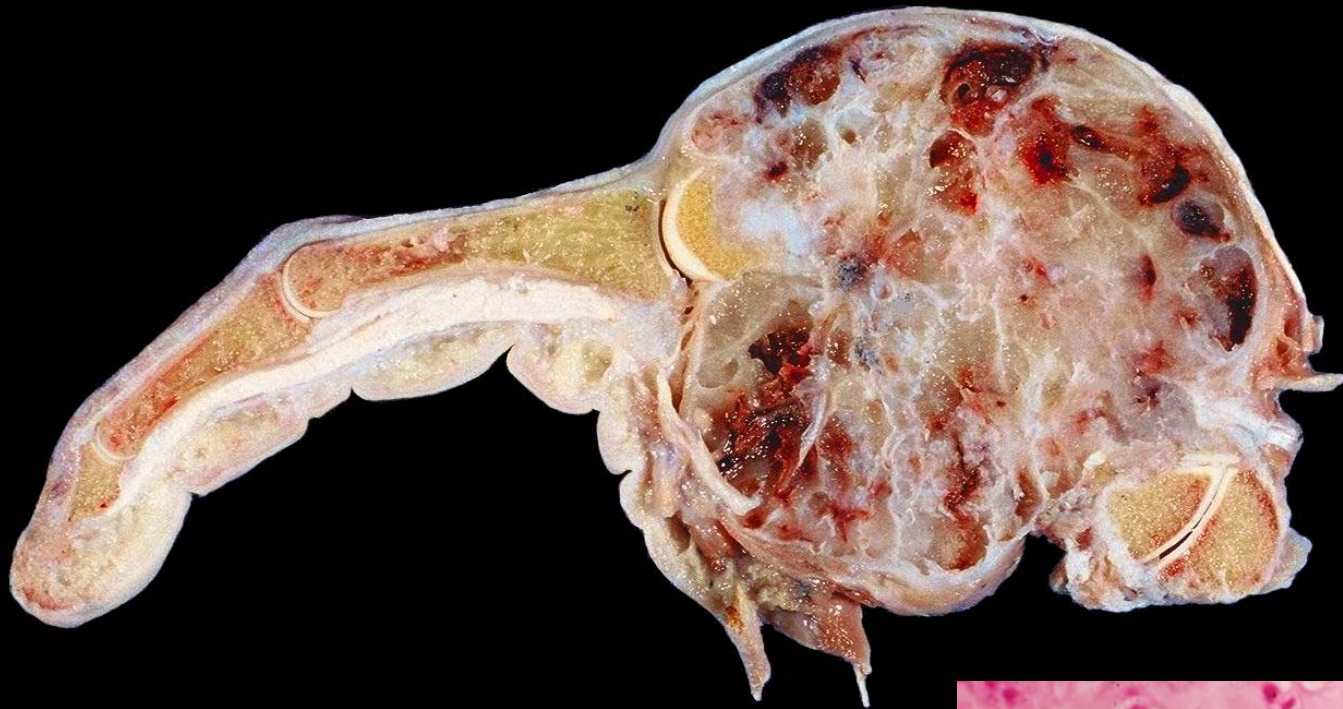




11 12 13 14 15 16 17 18 19 20 21 22 23

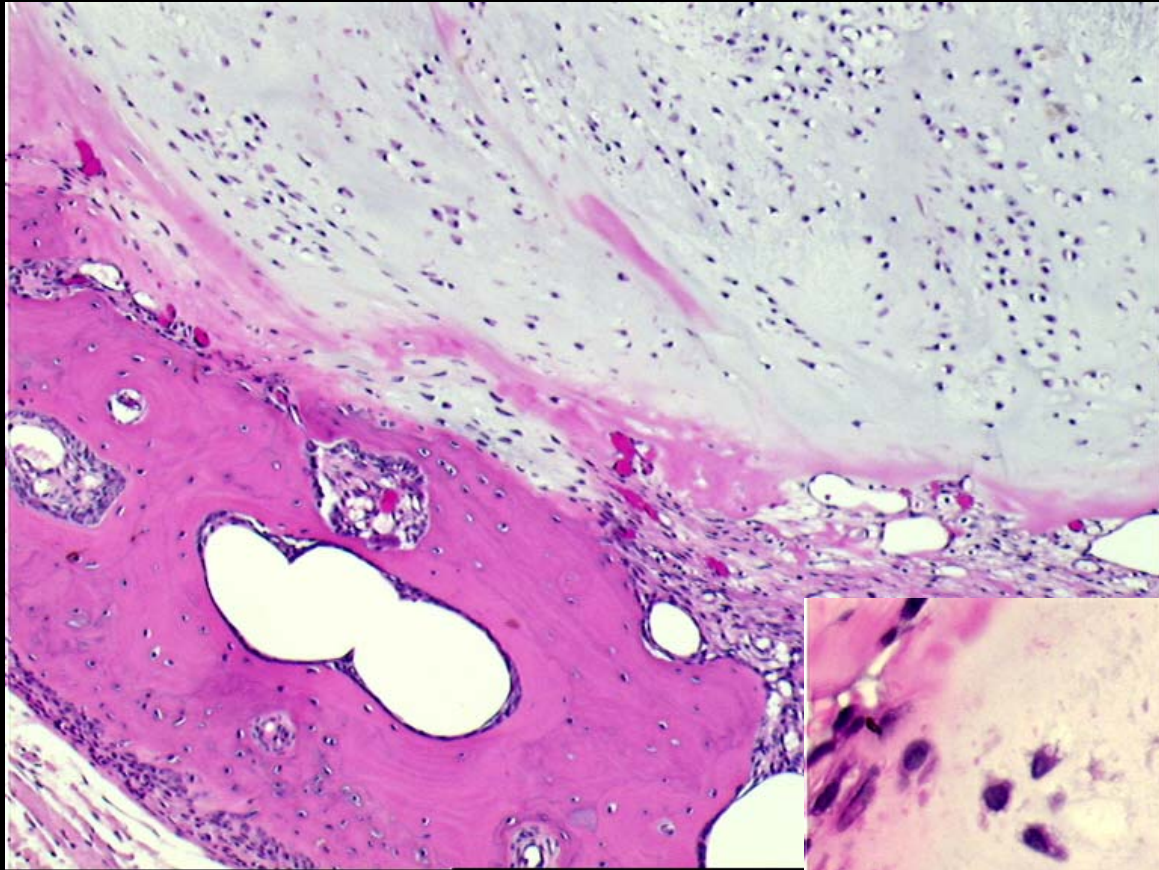




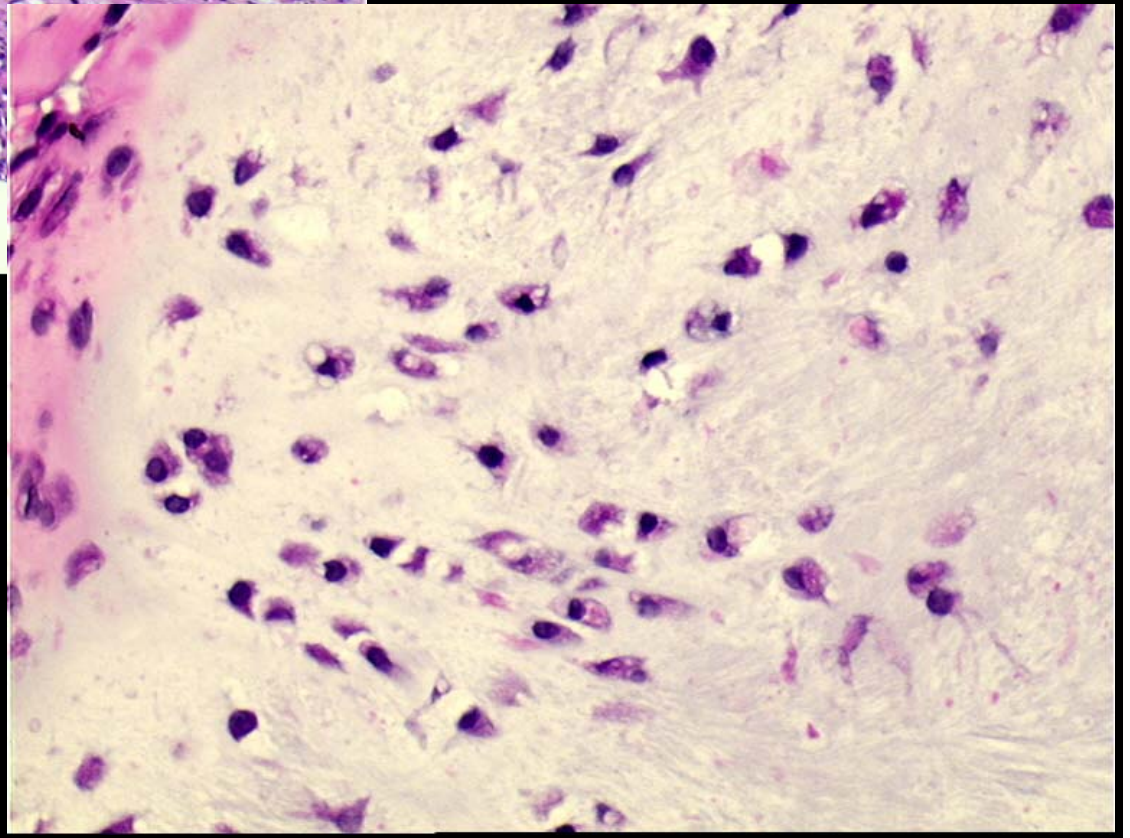


CHONDROMA IN HANDS AND FEET

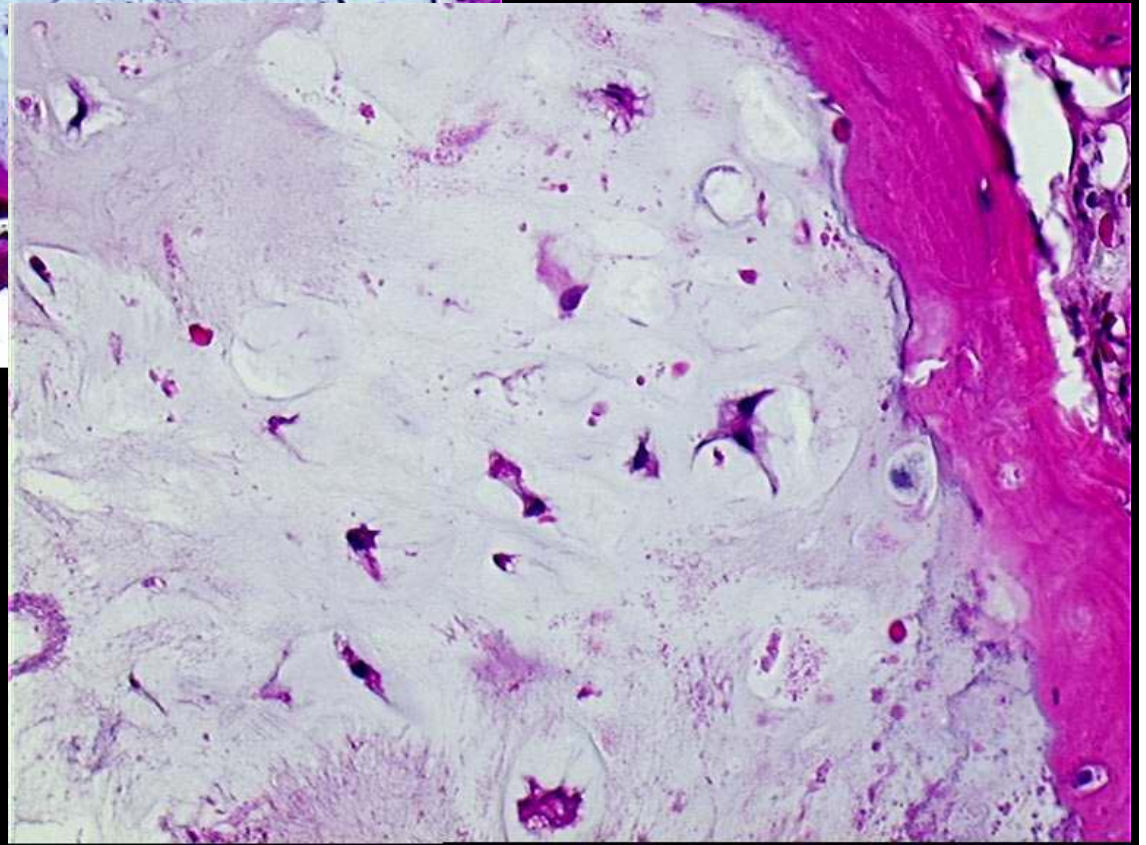
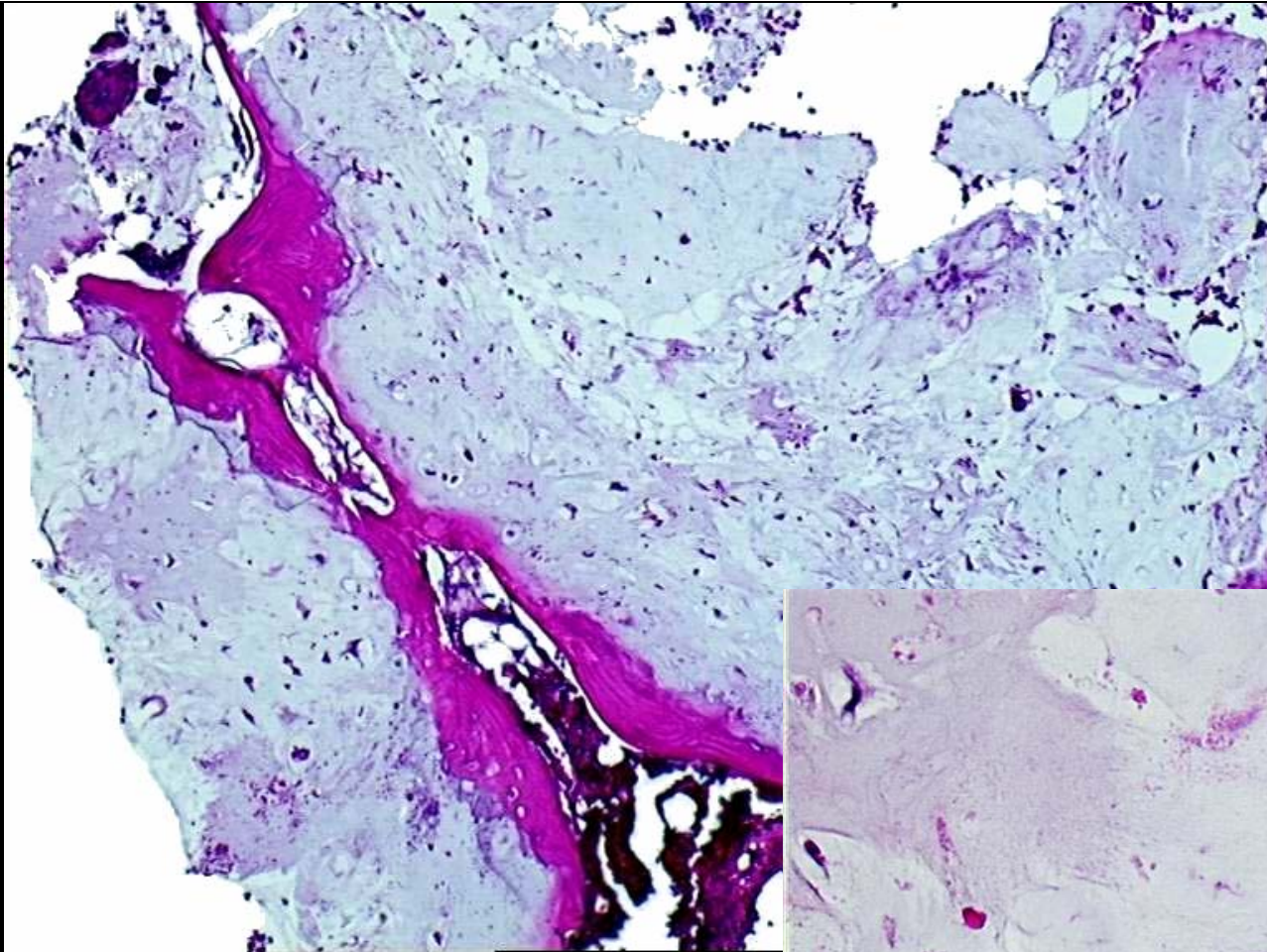
HISTOLOGY



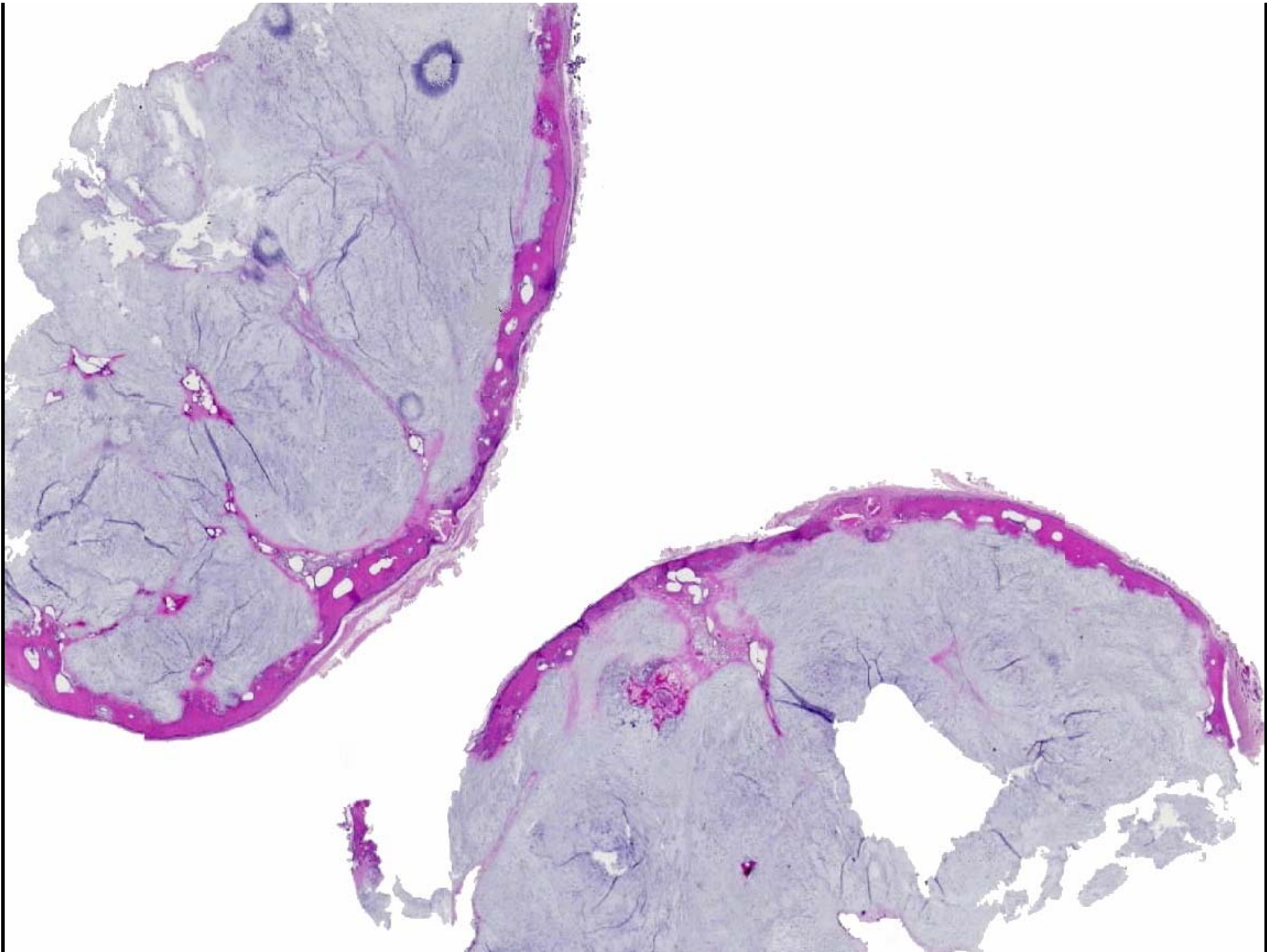
Well-delimited – host bone

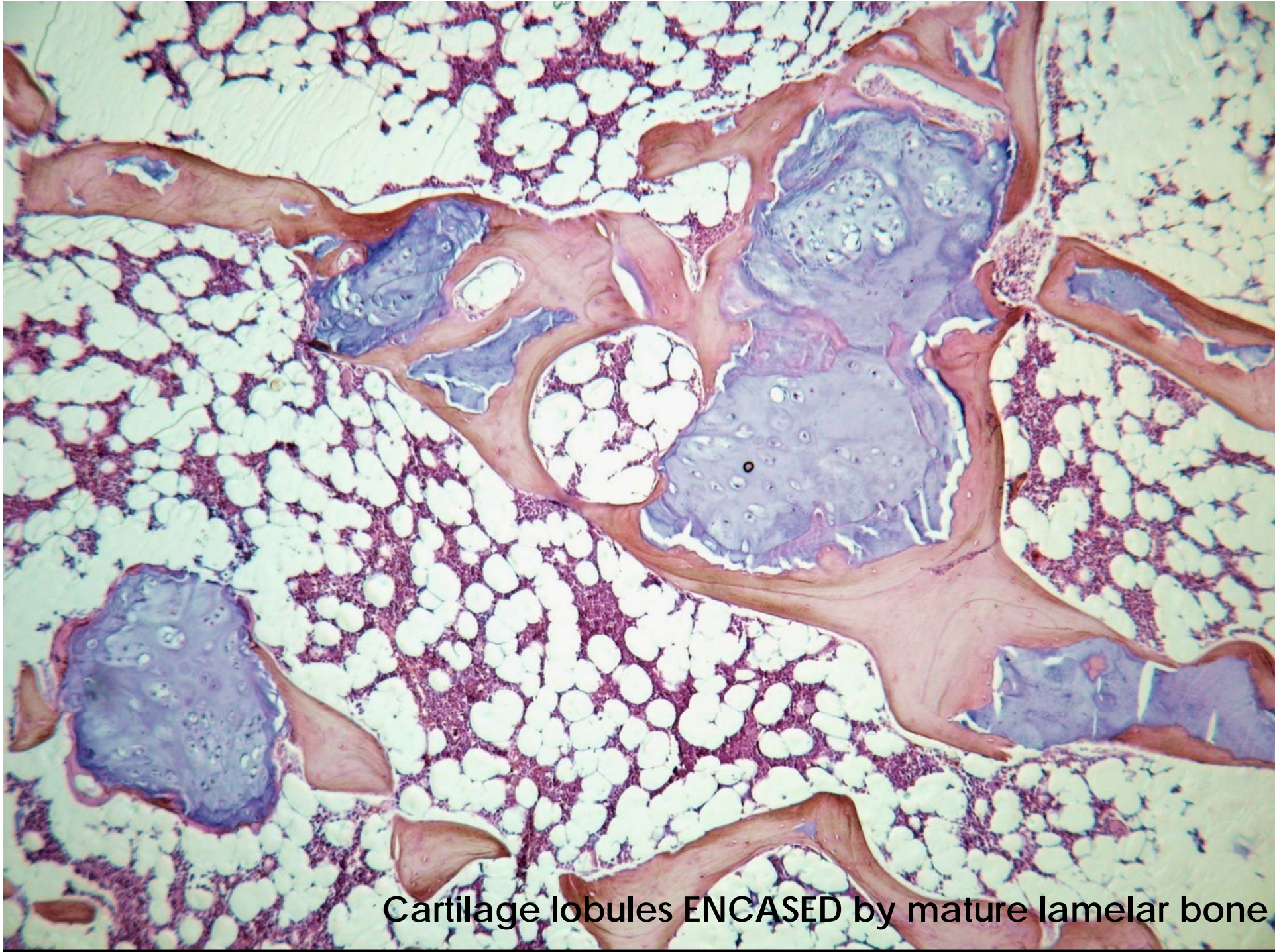


Well-differentiated
High cellularity

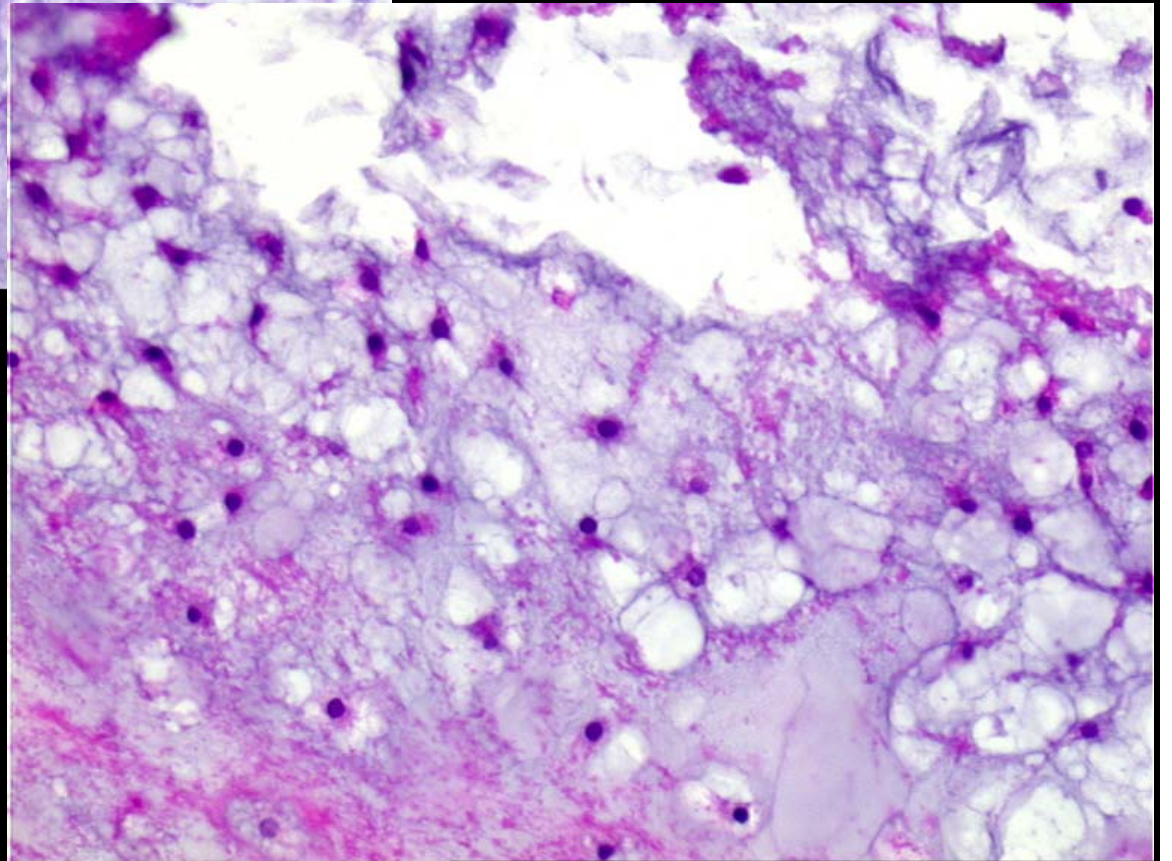
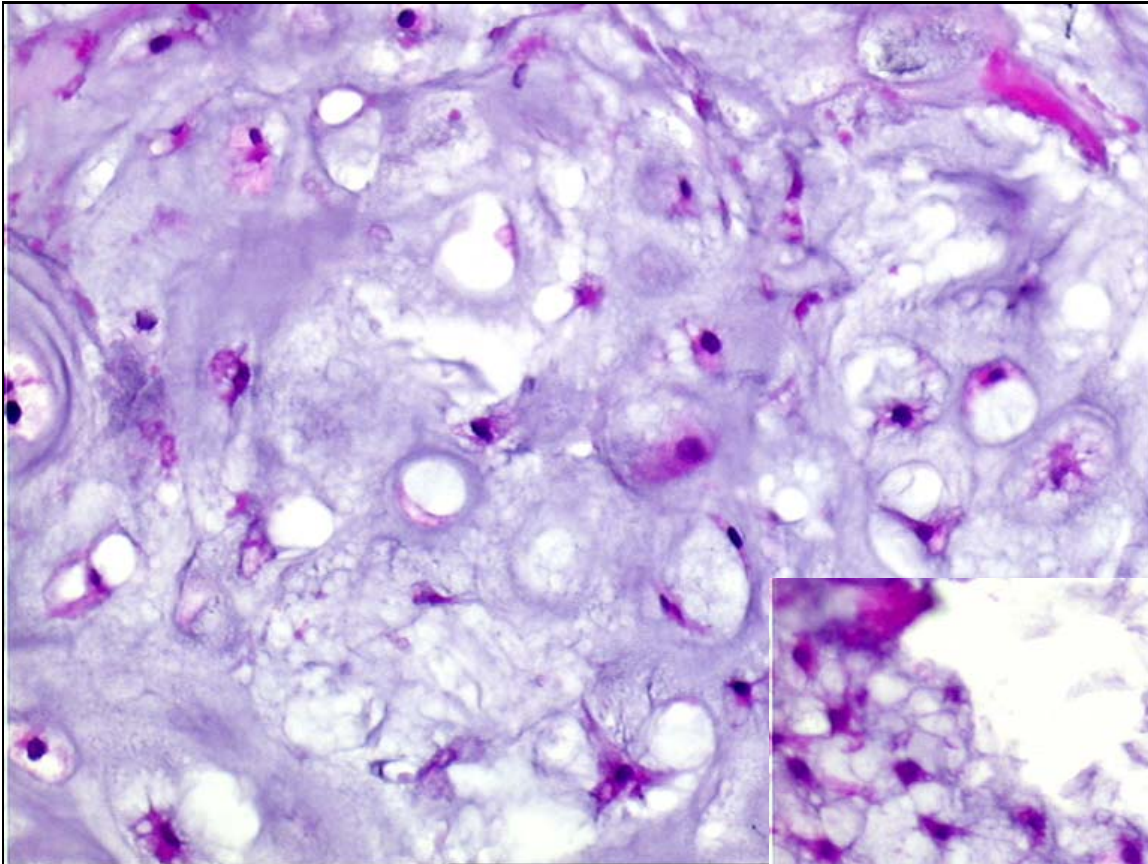


Enchondral Ossification
around chondroid
lobules

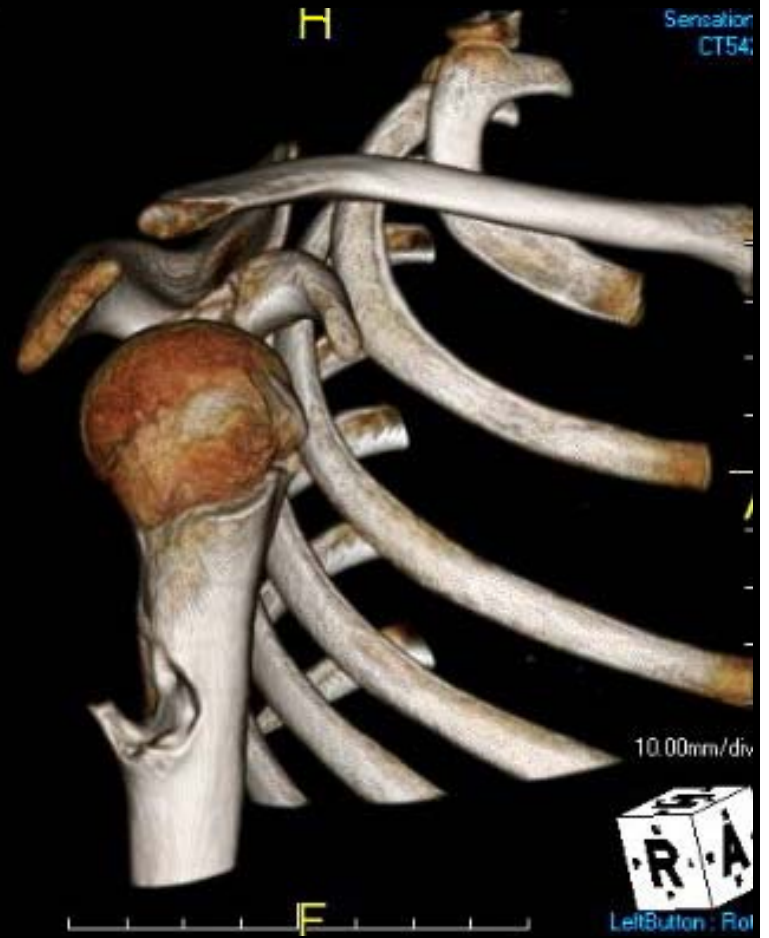
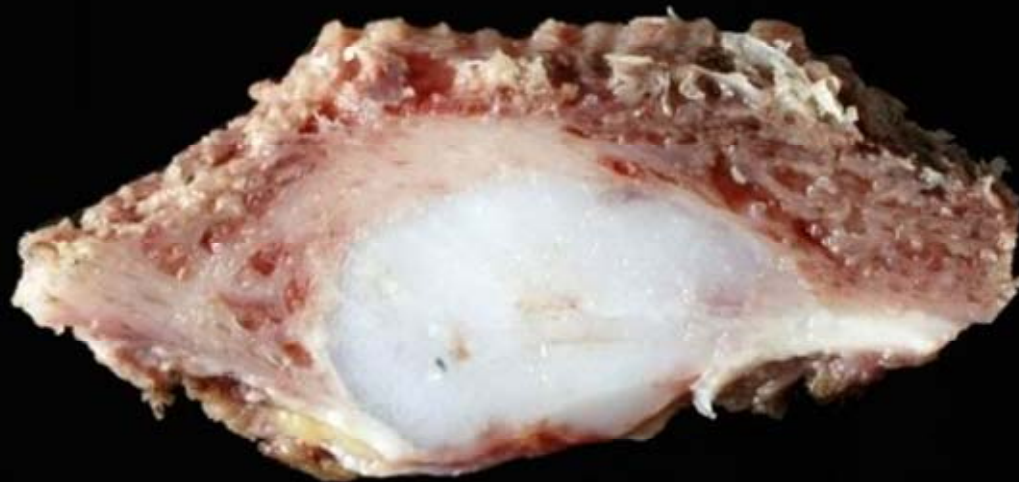
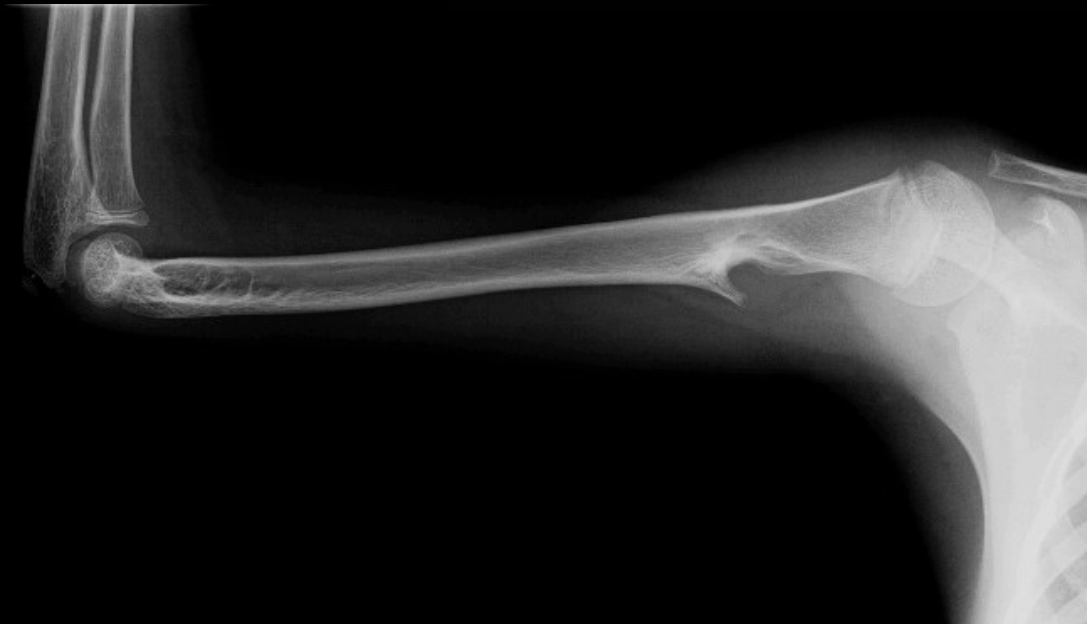


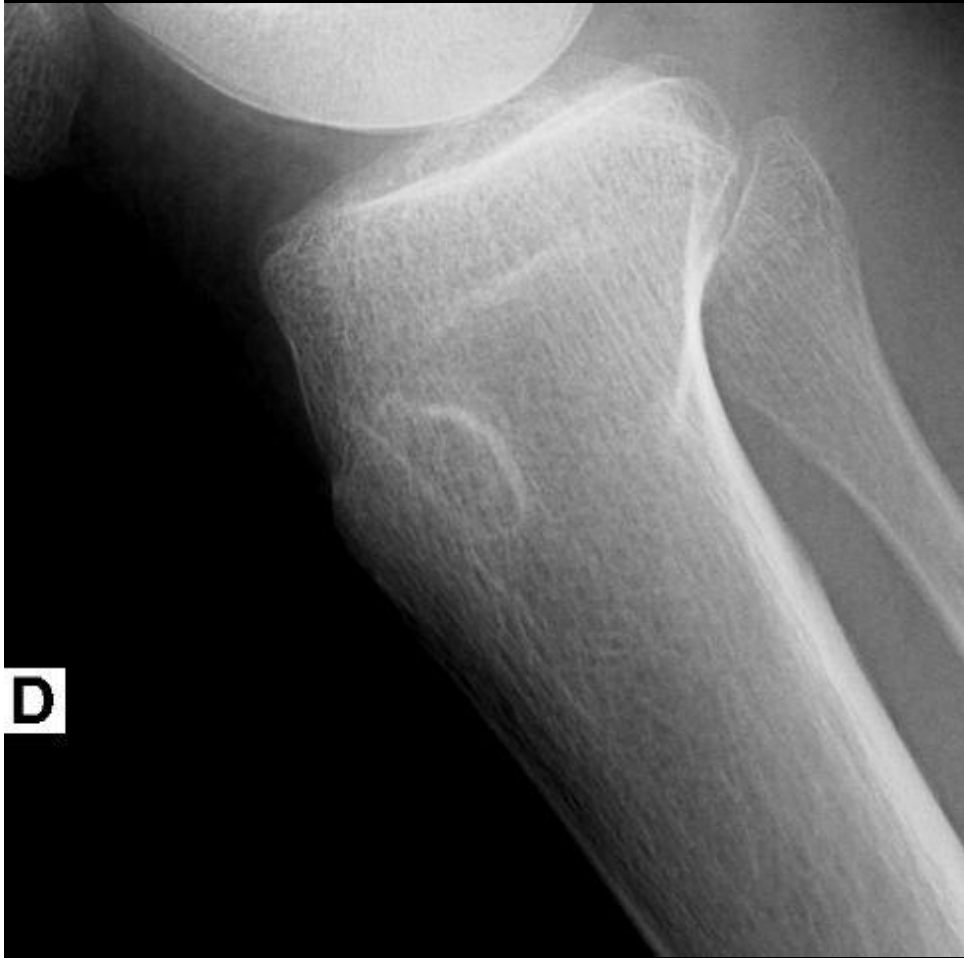
Cartilage lobules ENCASED by mature lamellar bone



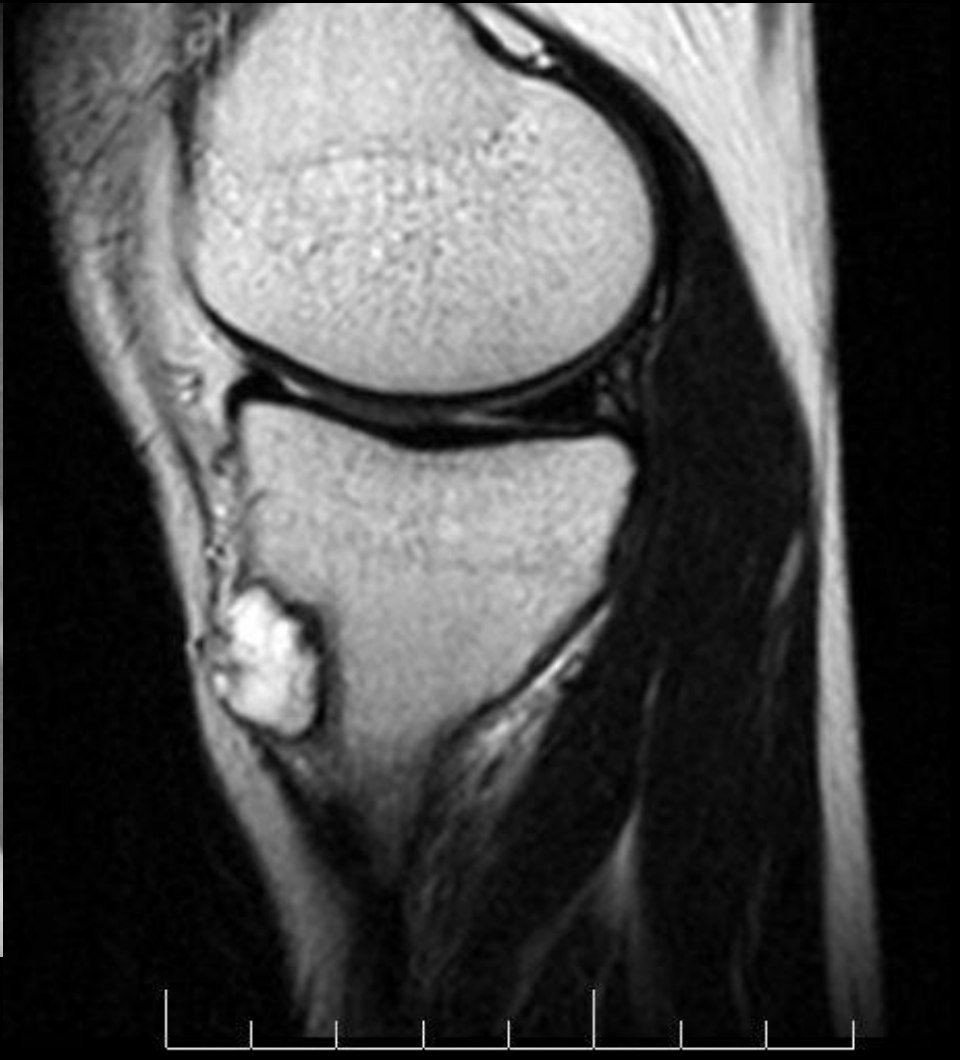PERIOSTEAL CHONDROMA

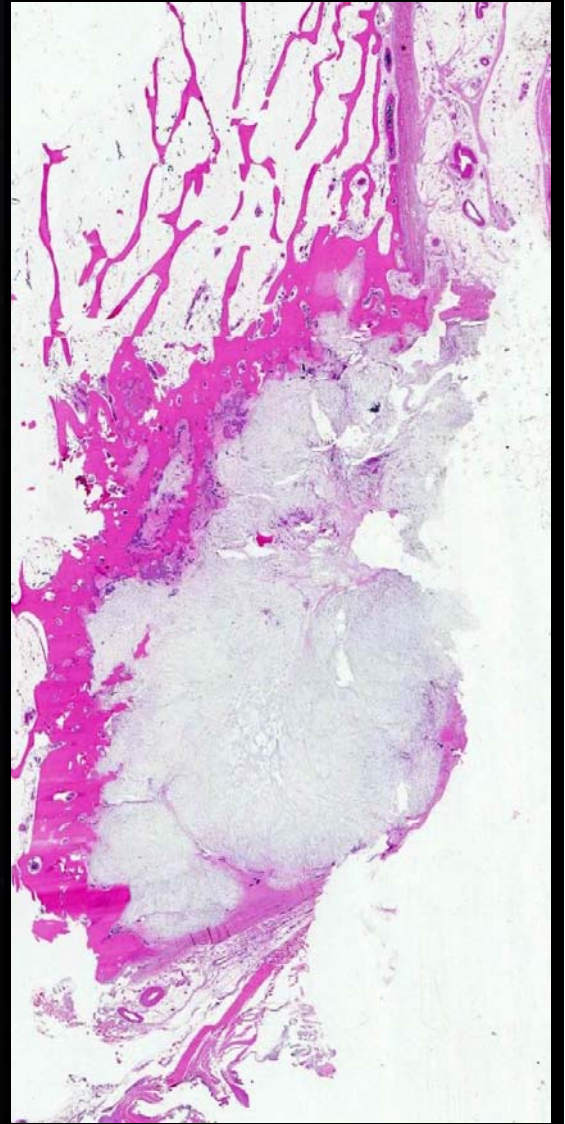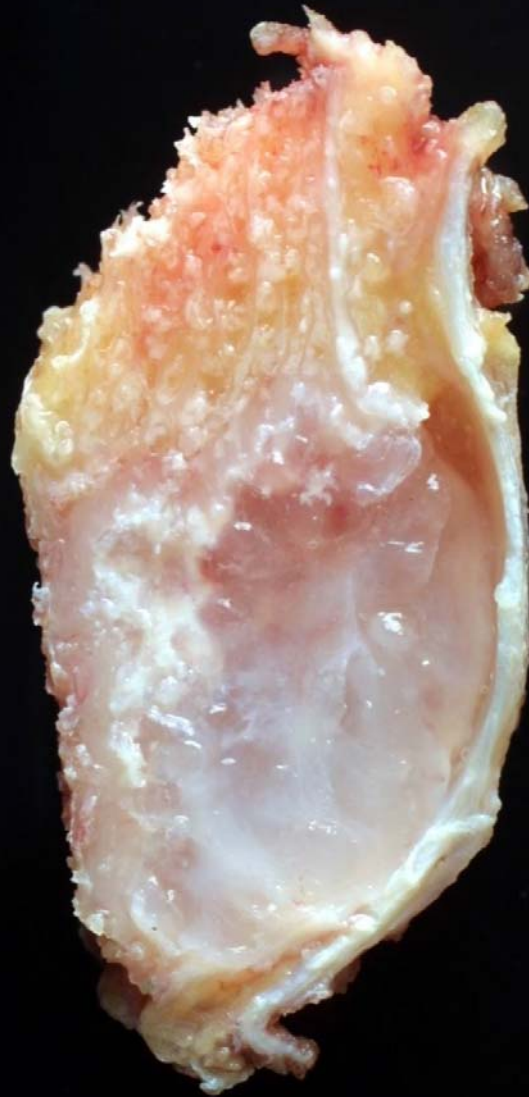
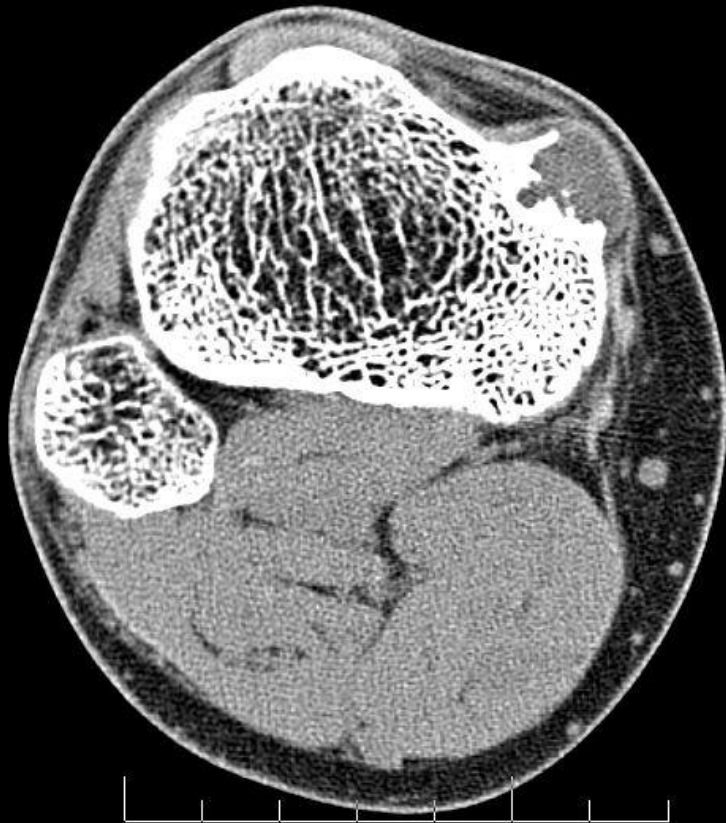


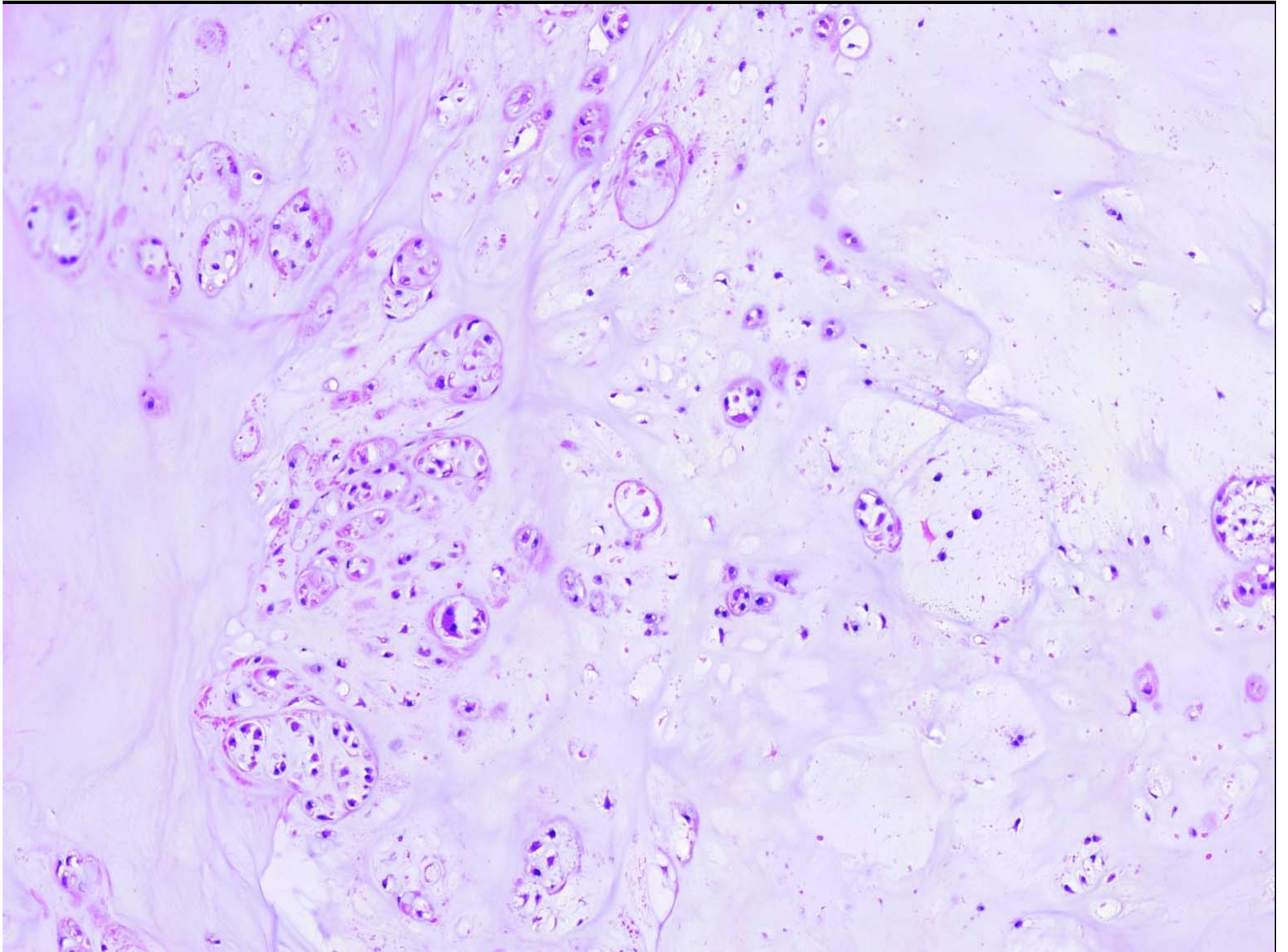
PERIOSTEAL CHONDROMA

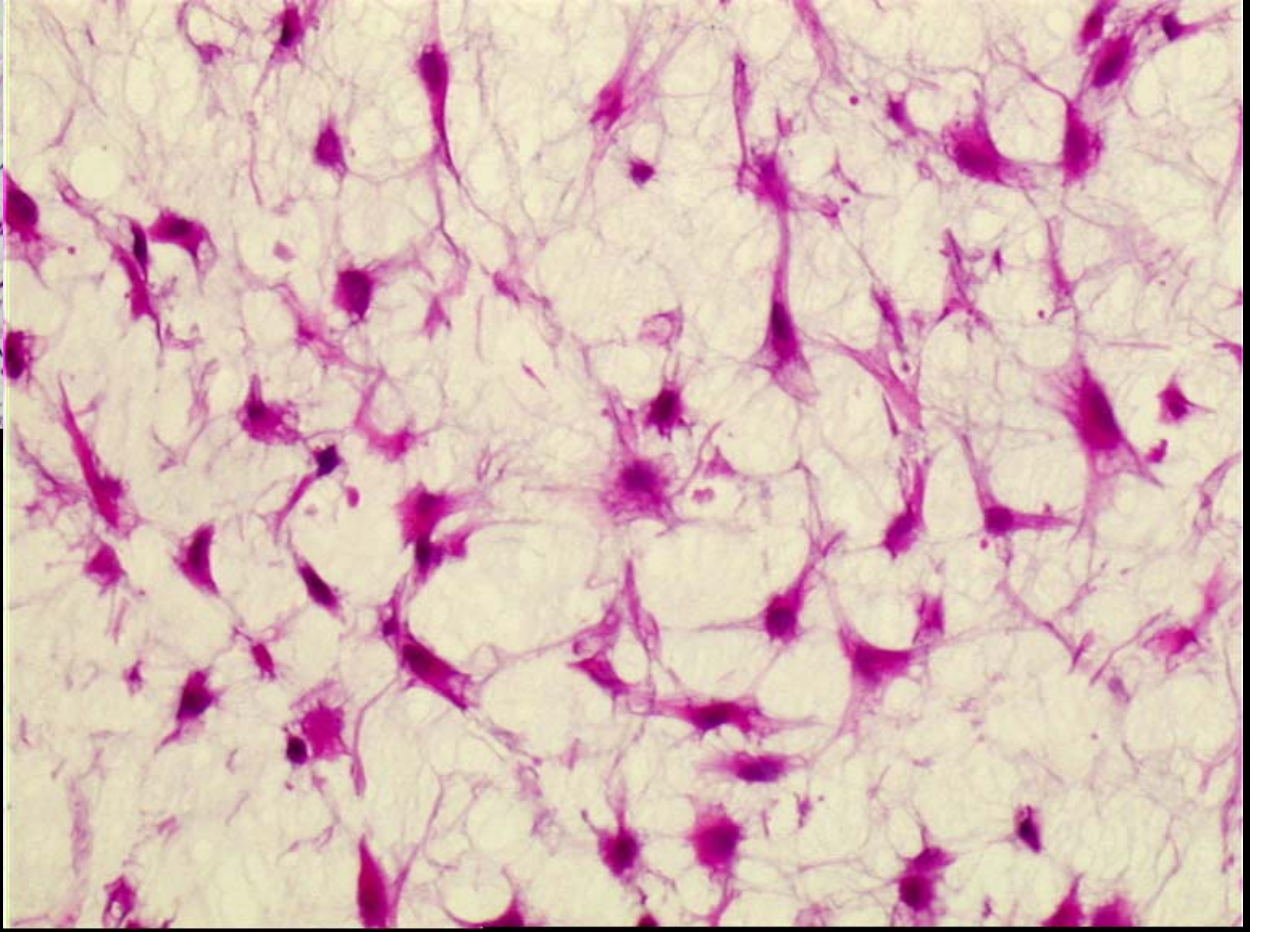
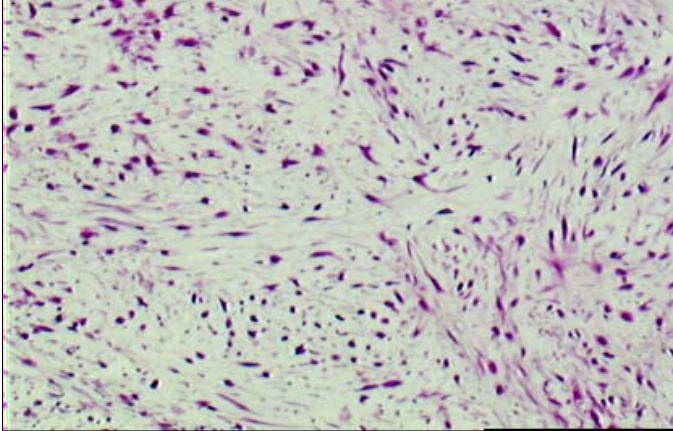
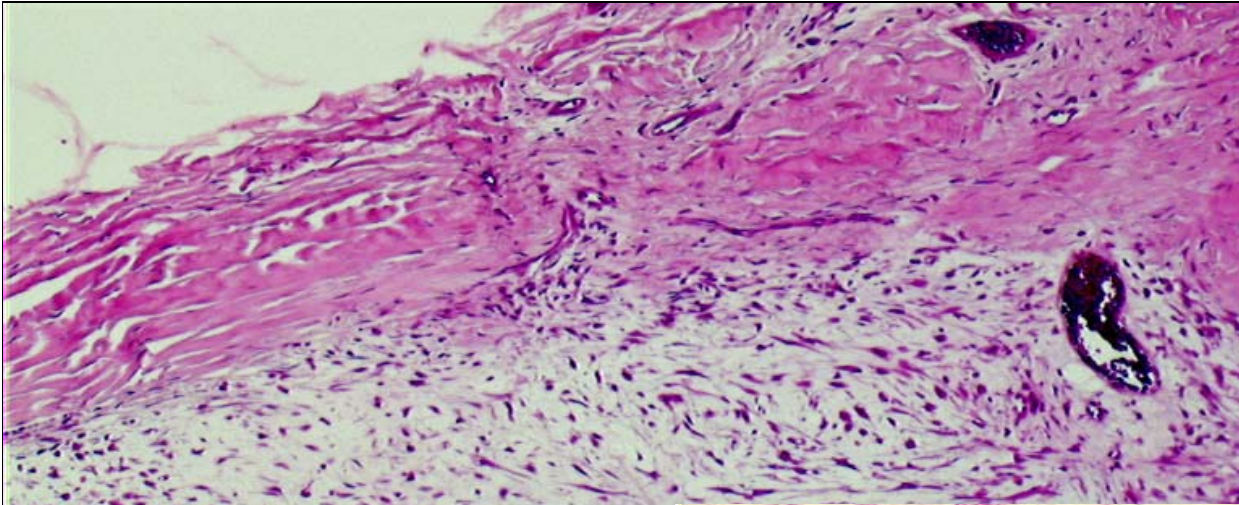


D

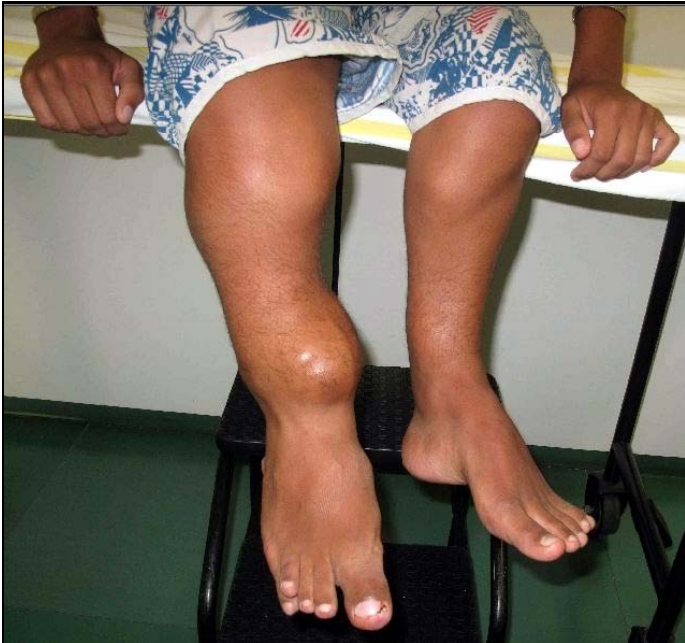






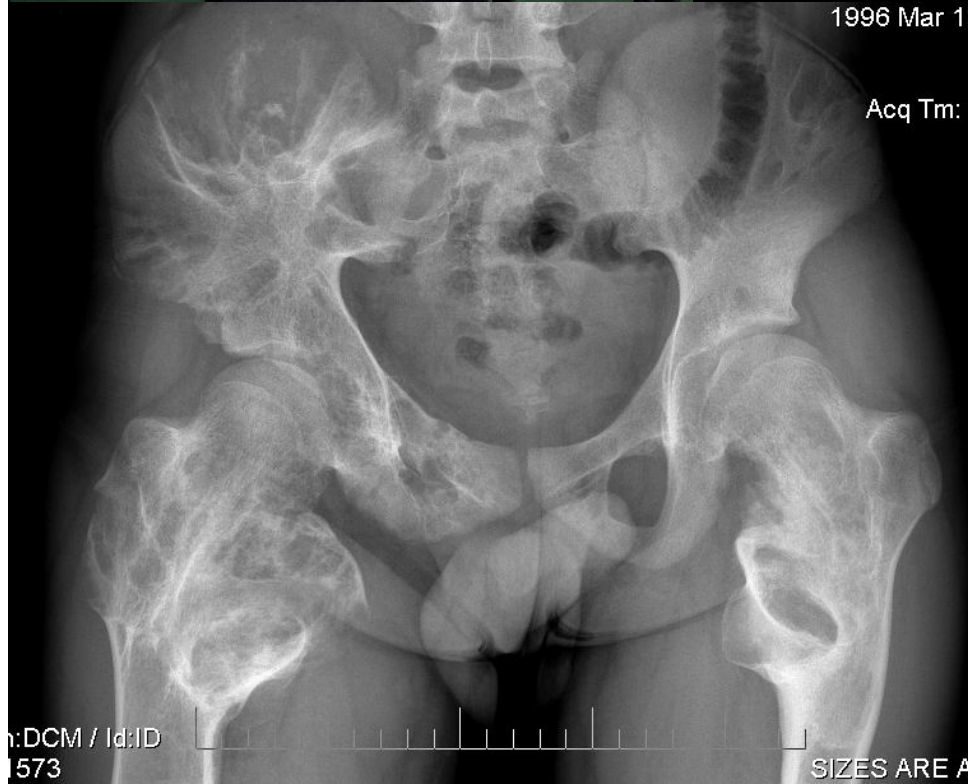
OLLIER'S DISEASE MULTIPLE ENCHONDROMATOSIS



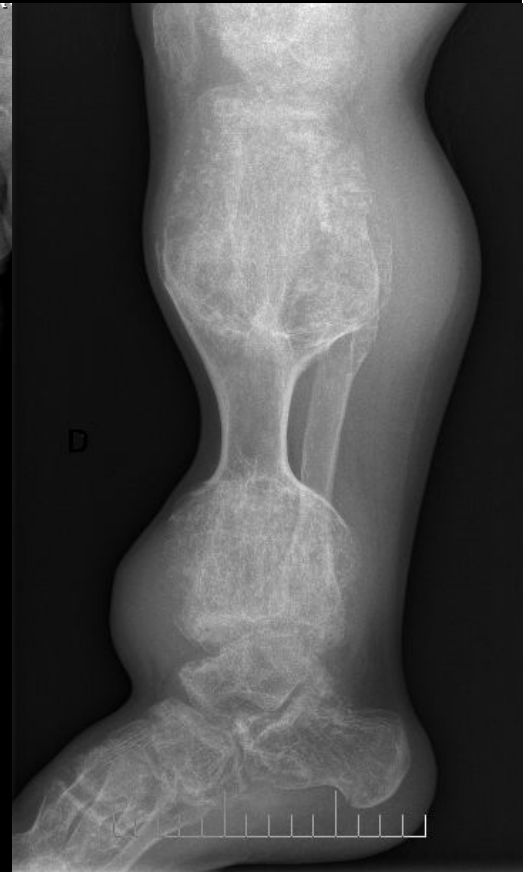
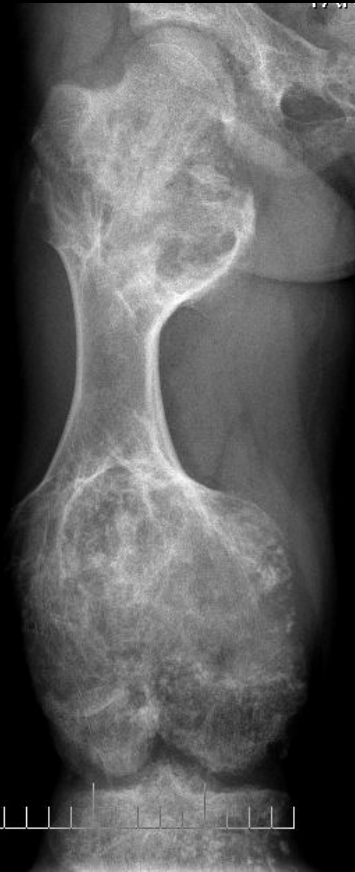1996 Mar 13

Acq Tm: 1

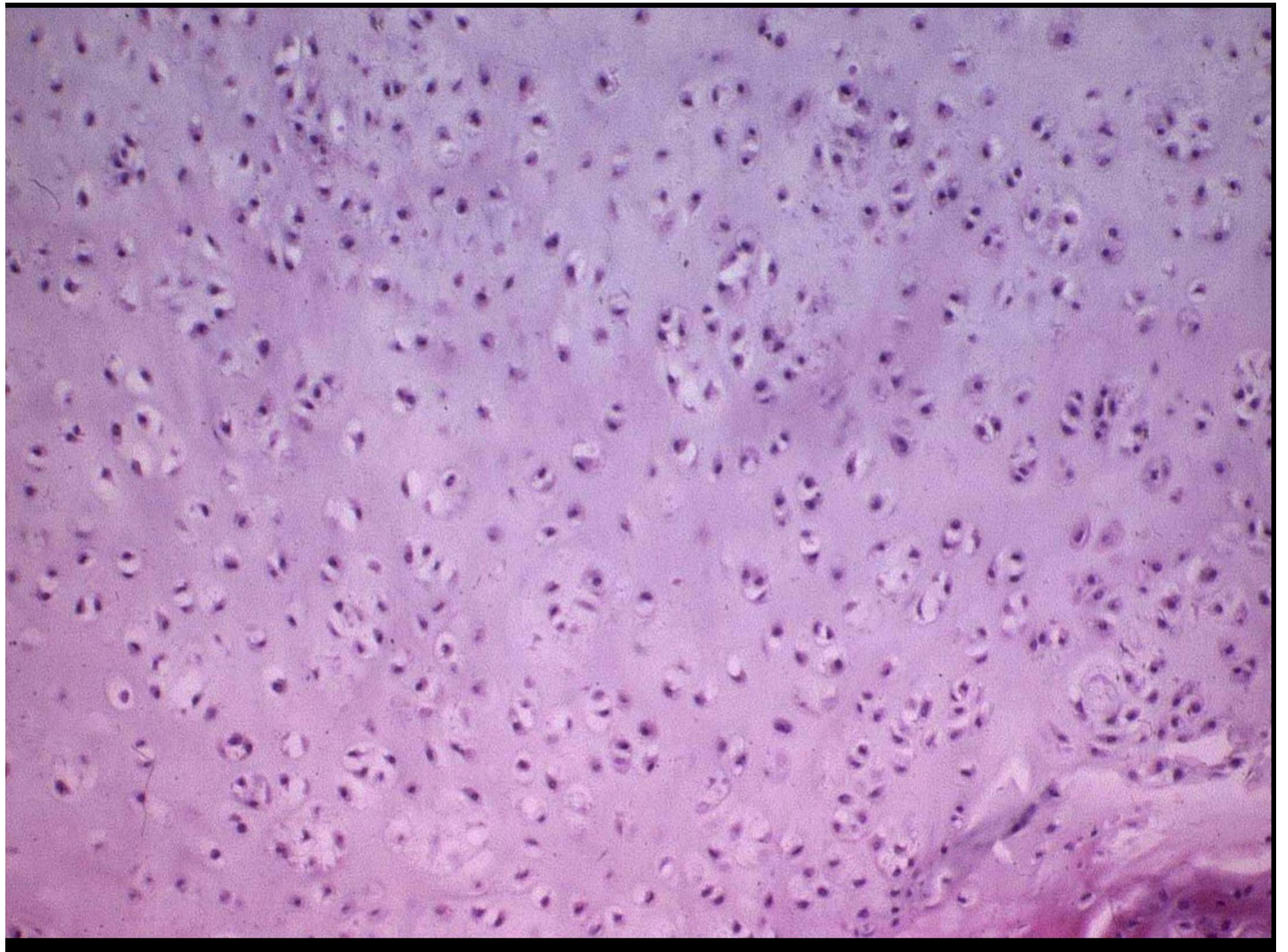


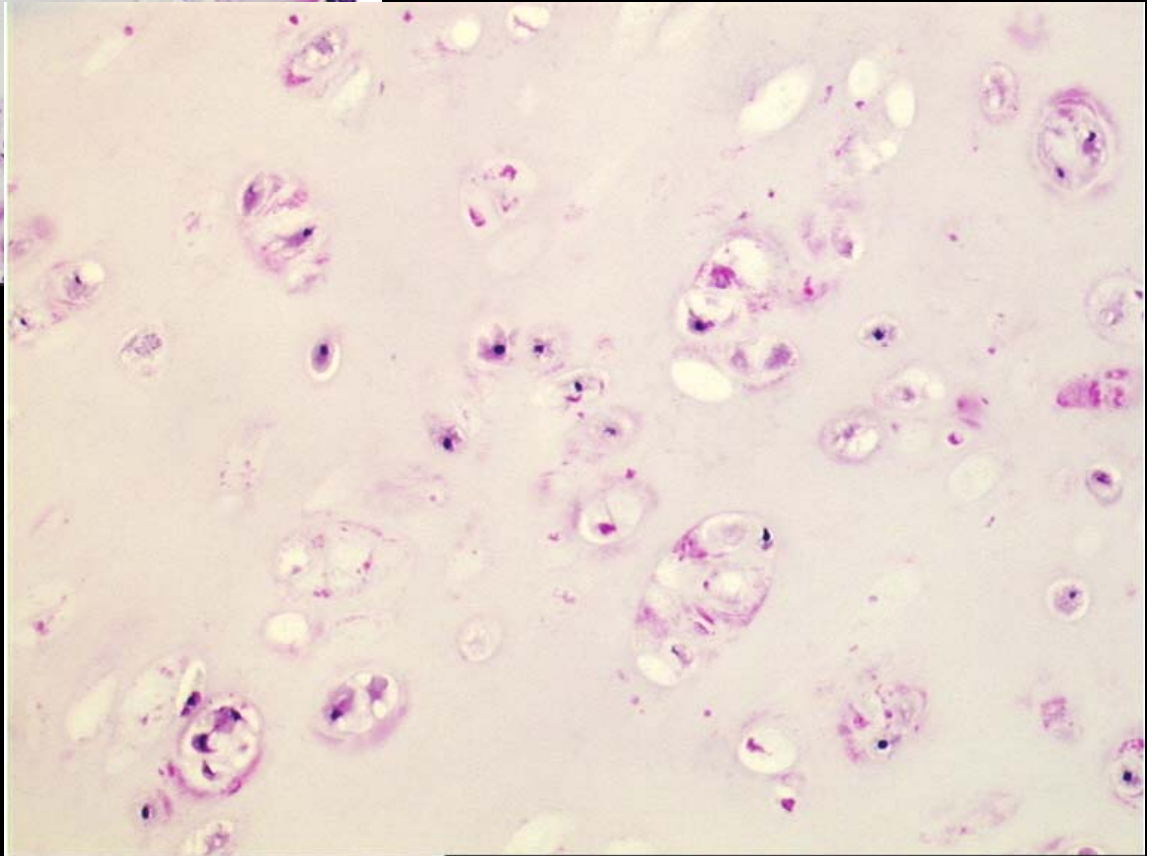
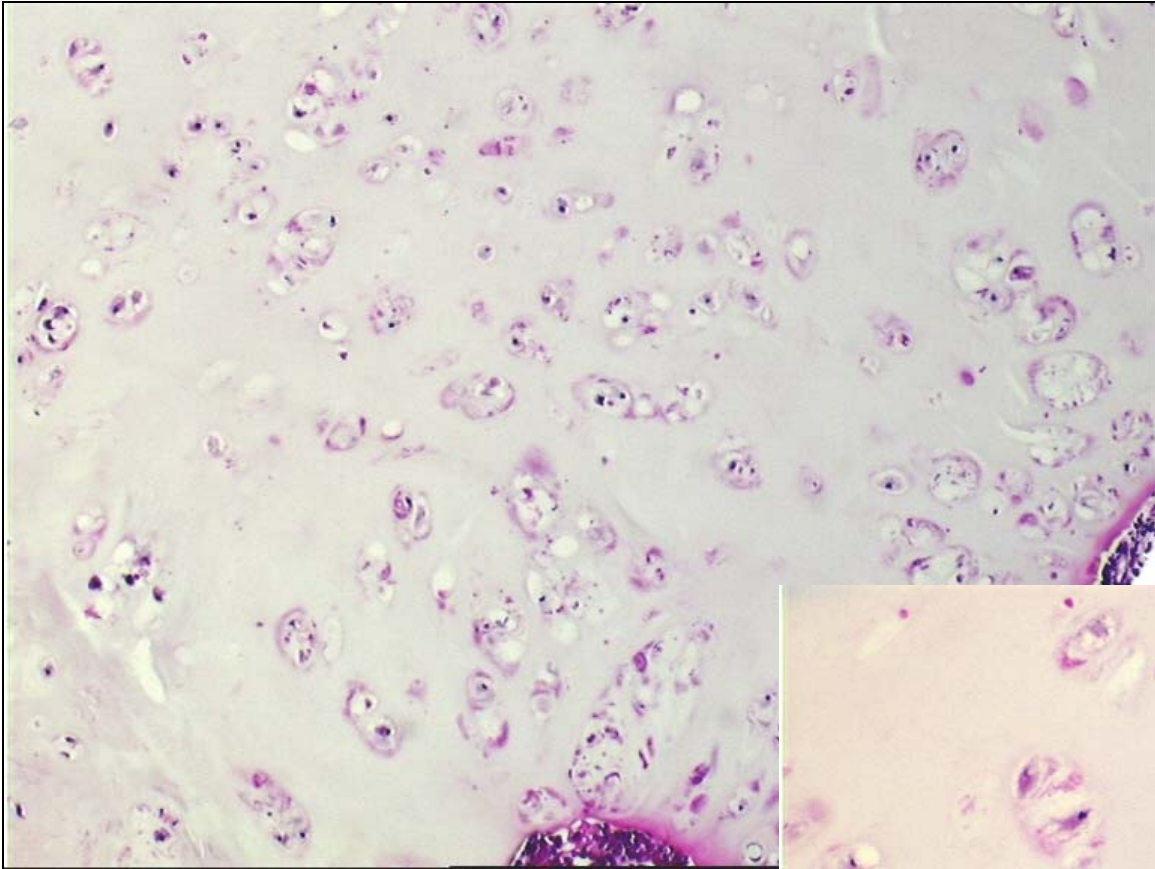
h:DCM / Id:ID
1573

SIZES ARE AI

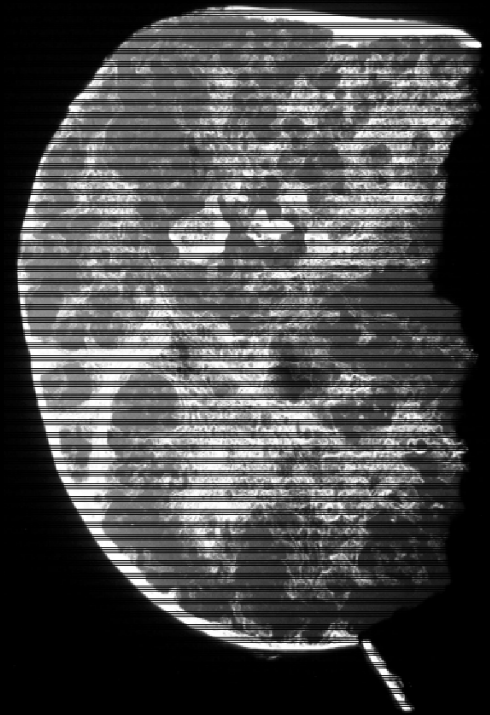
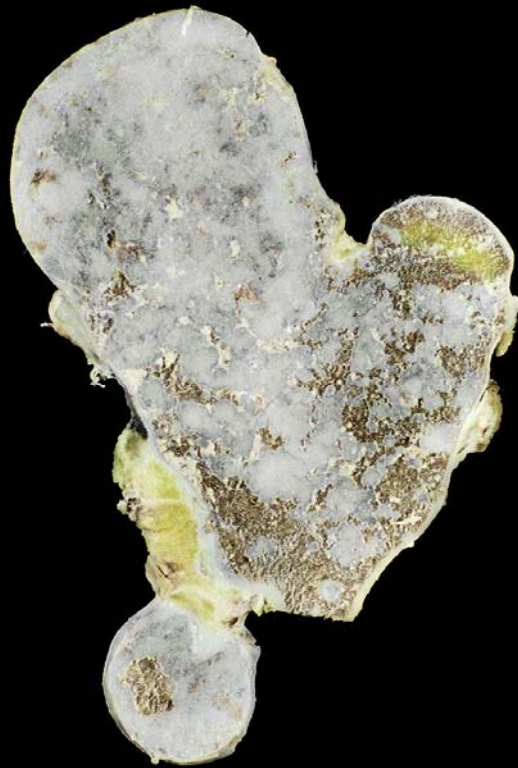
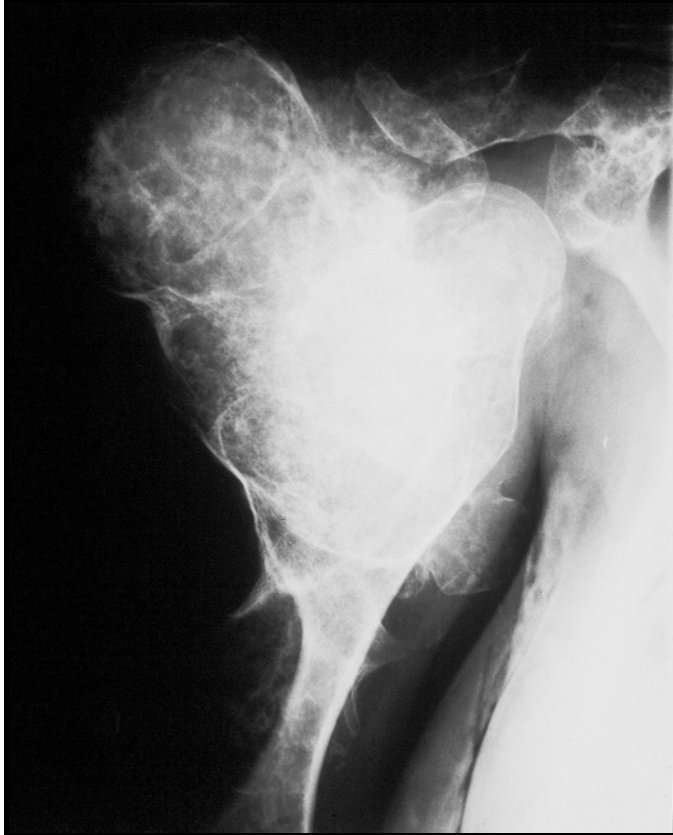
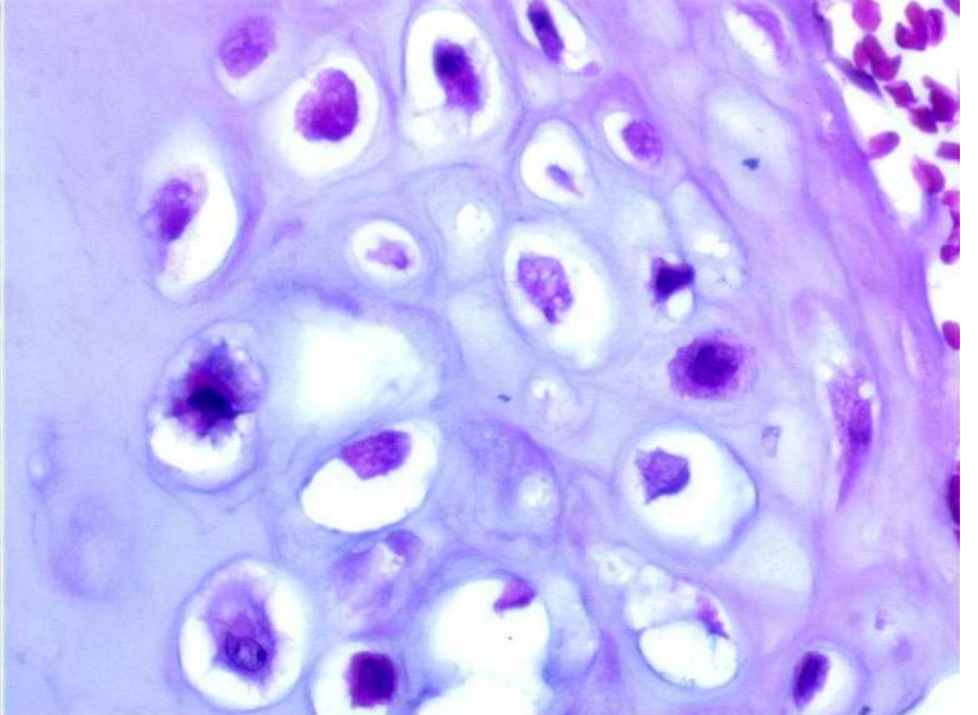
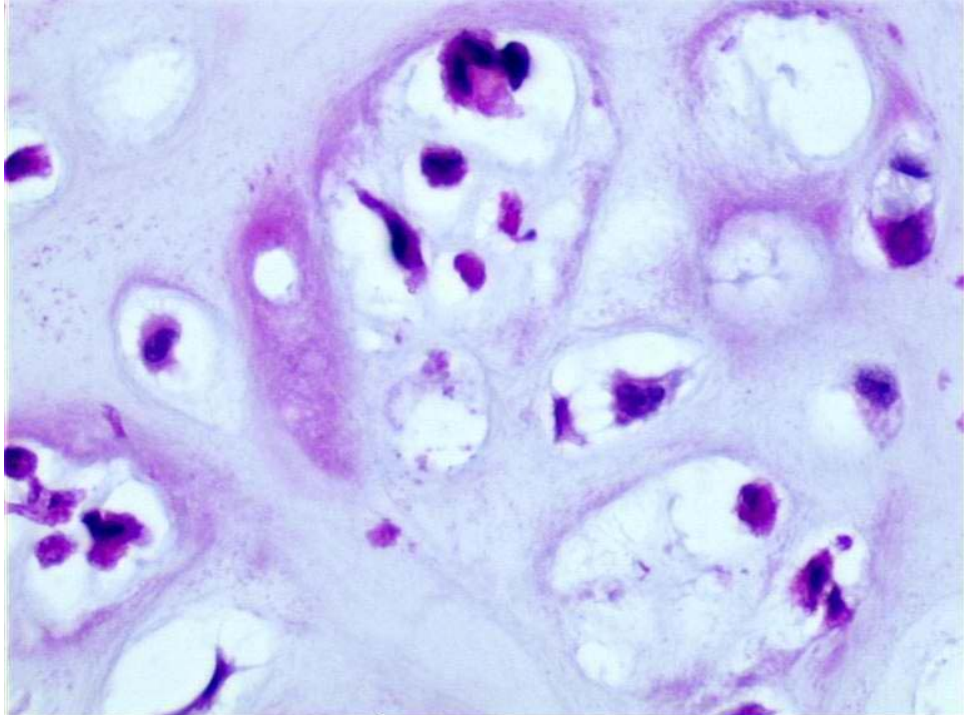
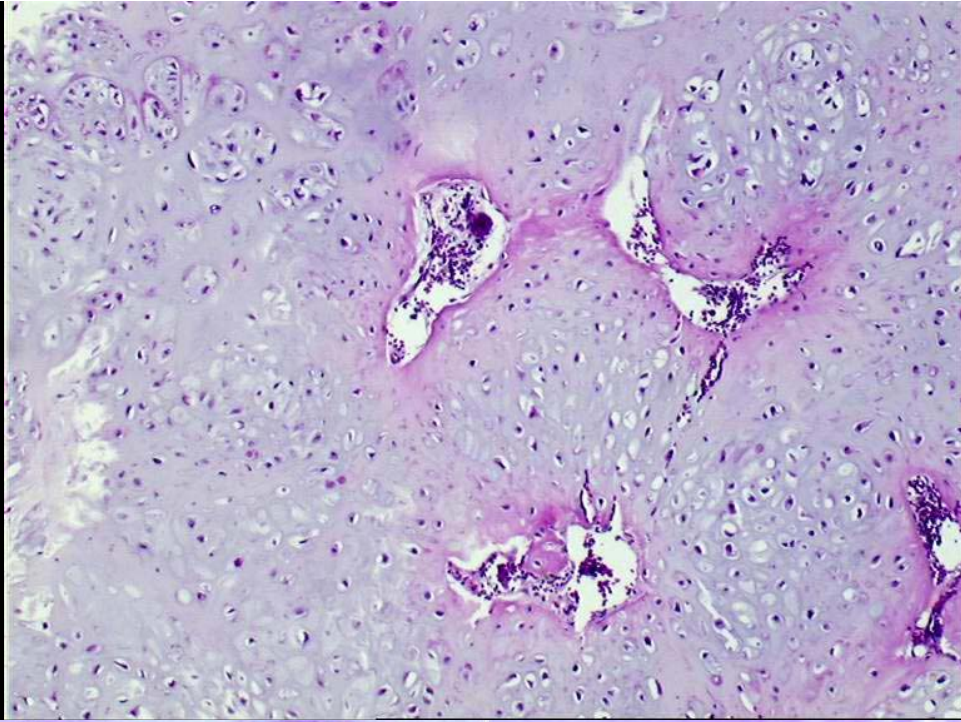
D





Malignization Risk: 25%





The behavior of a cartilage neoplasm is best predicted by asking the question:

Is the lesion growing?

Clinical, radiographic and microscopic features should be interpreted in the light of this question.

EVOLUTION

CHONDROMA

CHONDROSARCOMA I

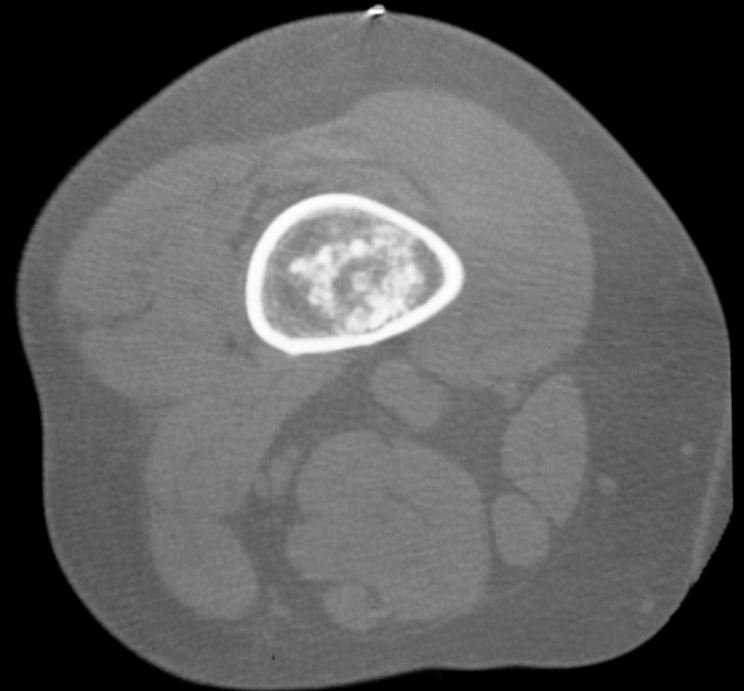
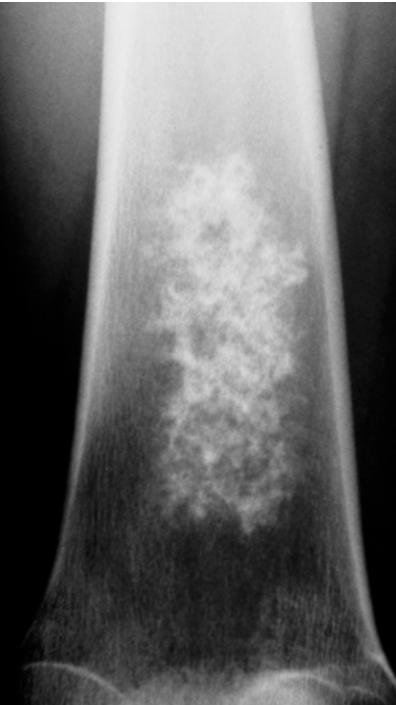
NO GROWTH
AFTER PUBERTY

PROGRESSIVE
GROWTH
IN THE ADULT

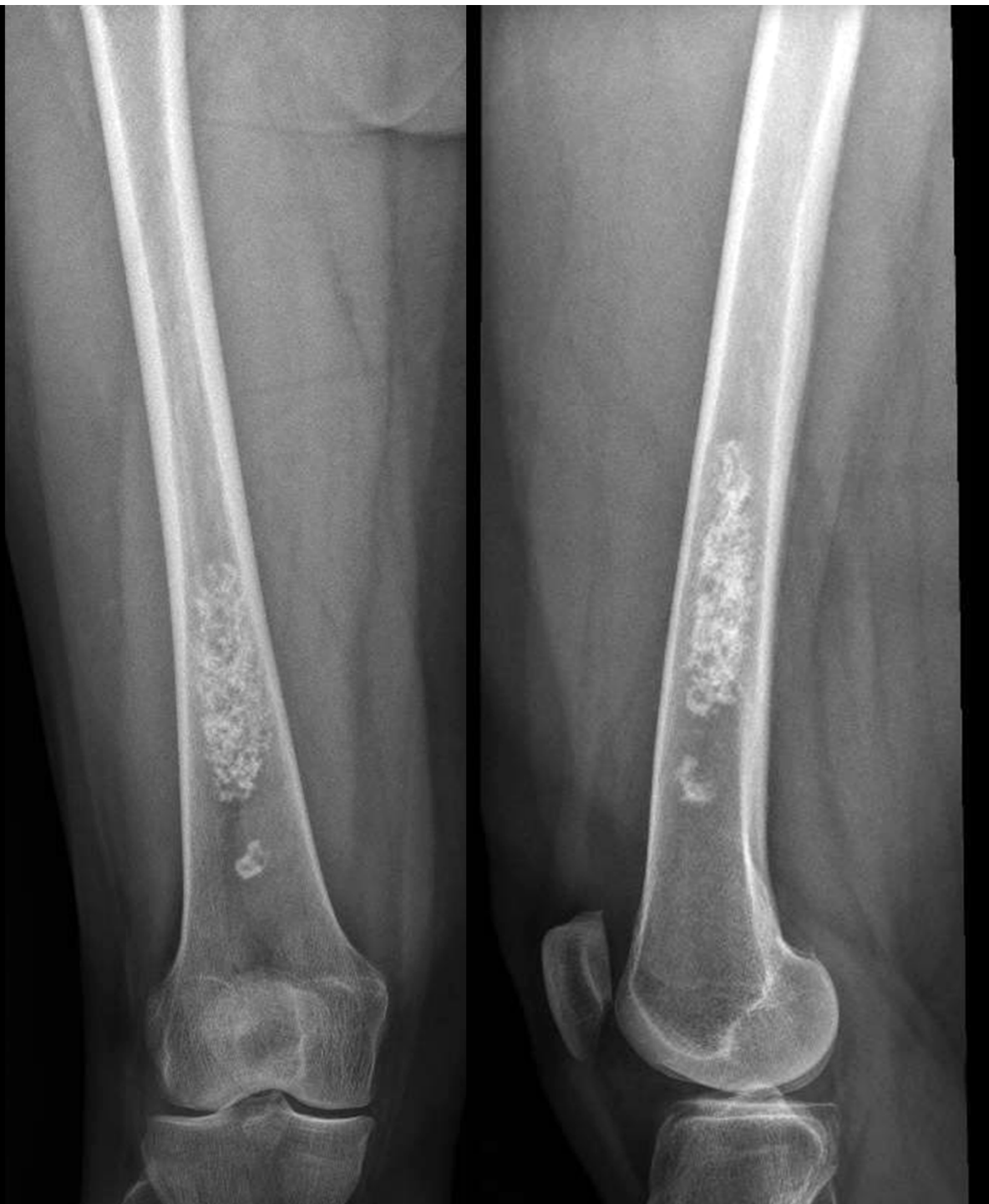CHONDROMA OF LONG BONES XR

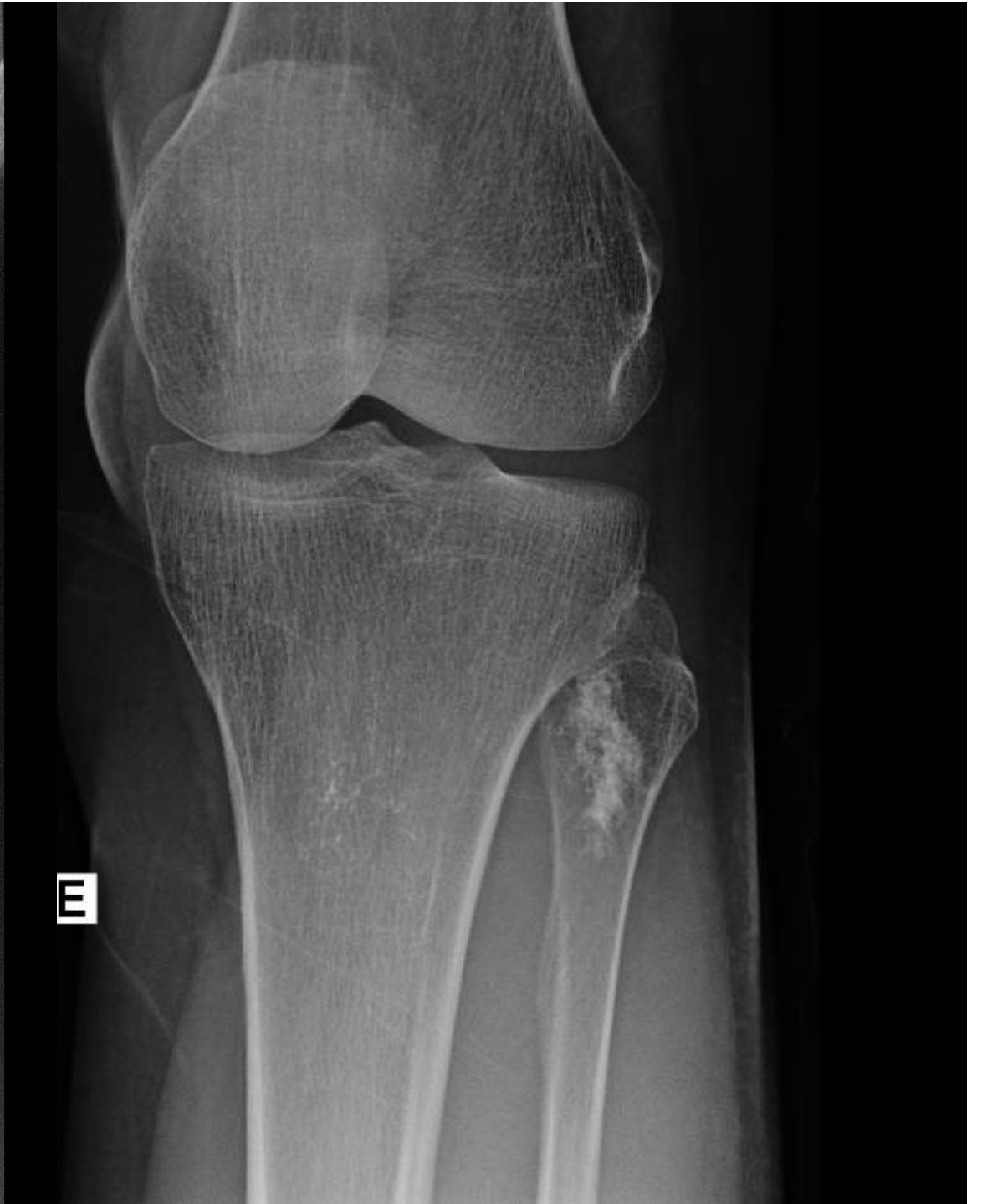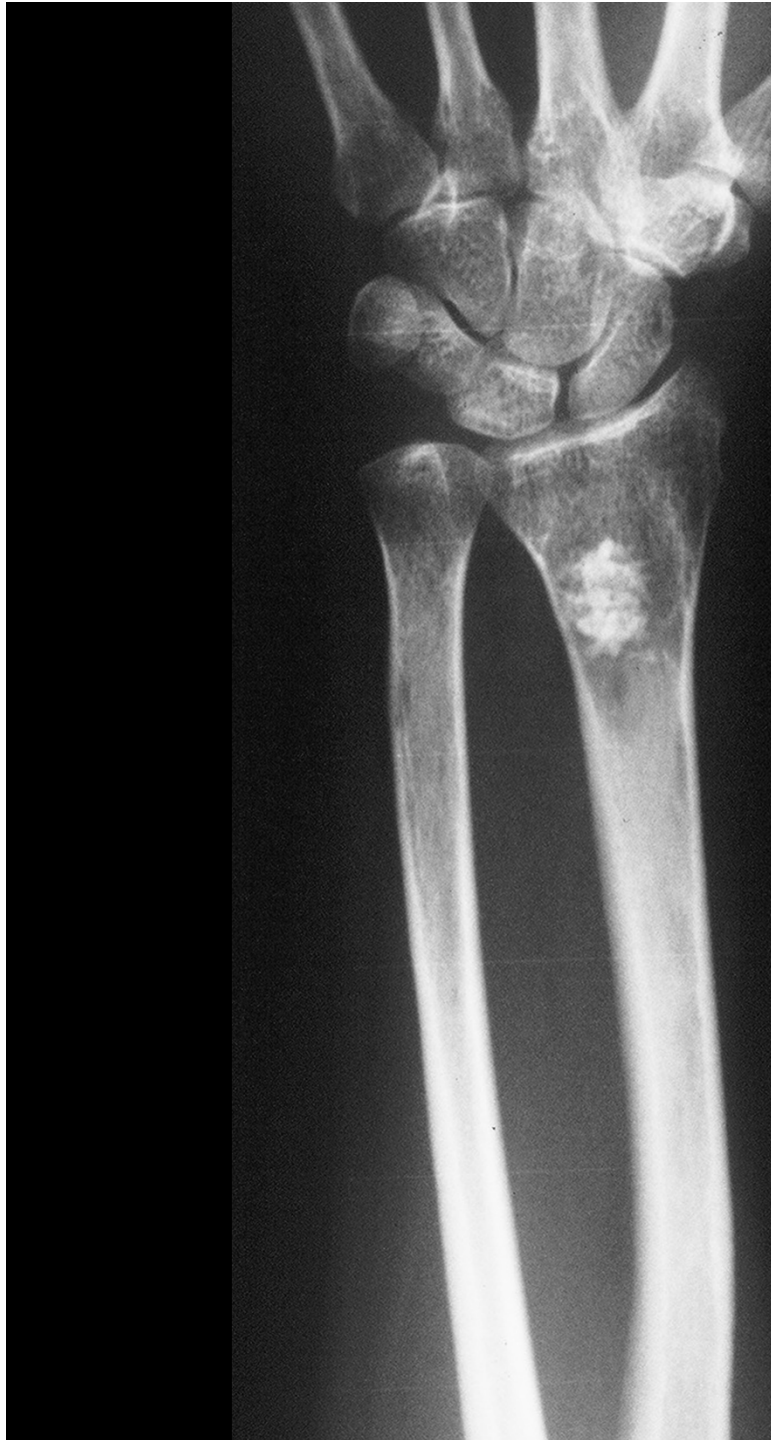- INTRAMEDULLAR
- NO OR MILD ENDOSTEAL RESORPTION
- NO CORTICAL THICKENING
- NO CORTICAL EXPANSION

FOLLOW-UP X-R

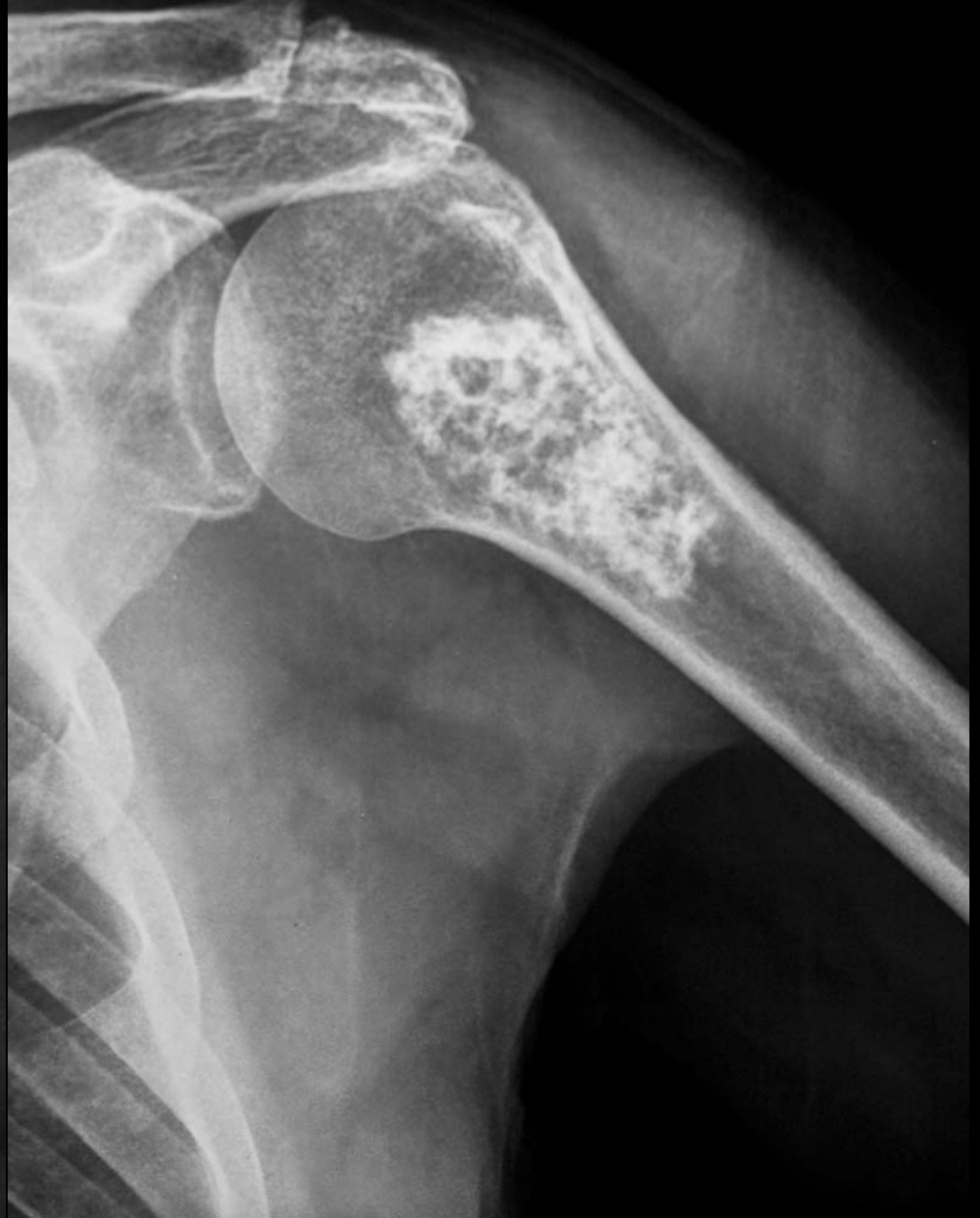
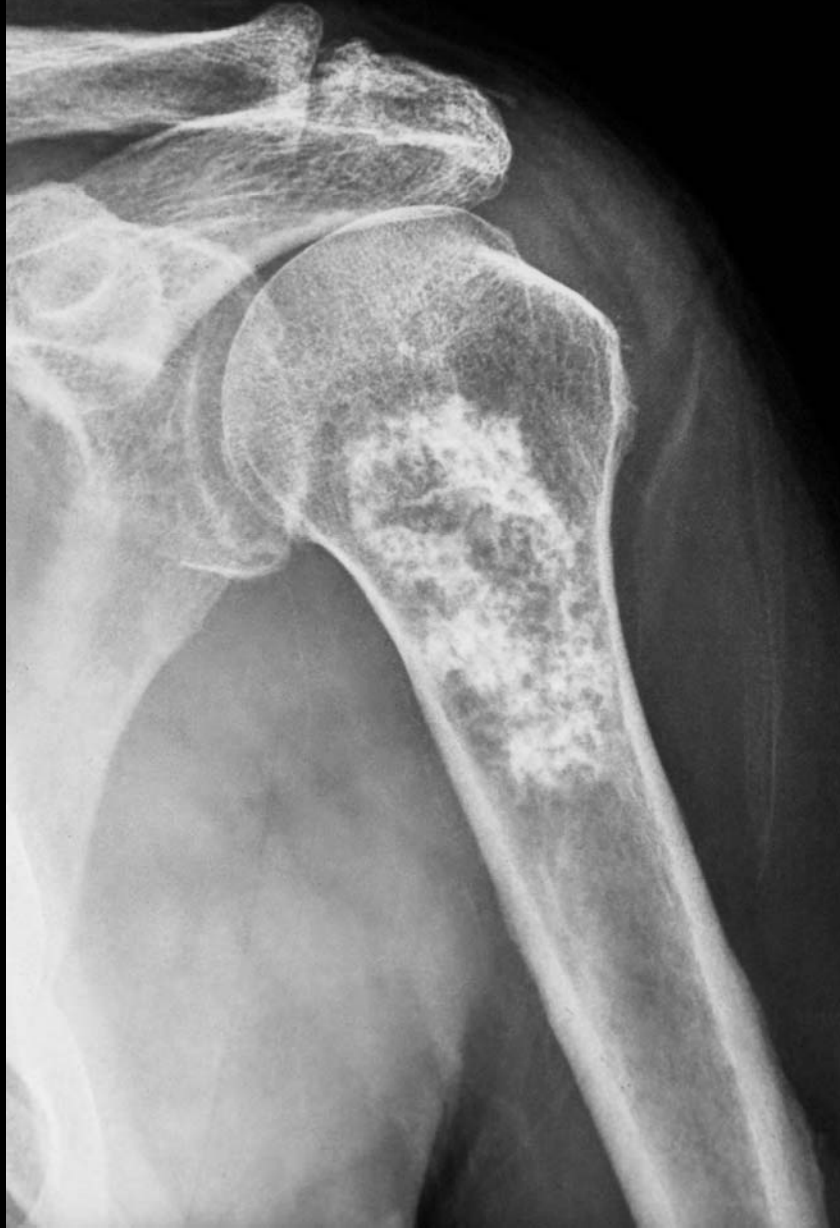
No or mild
endosteal
resorption





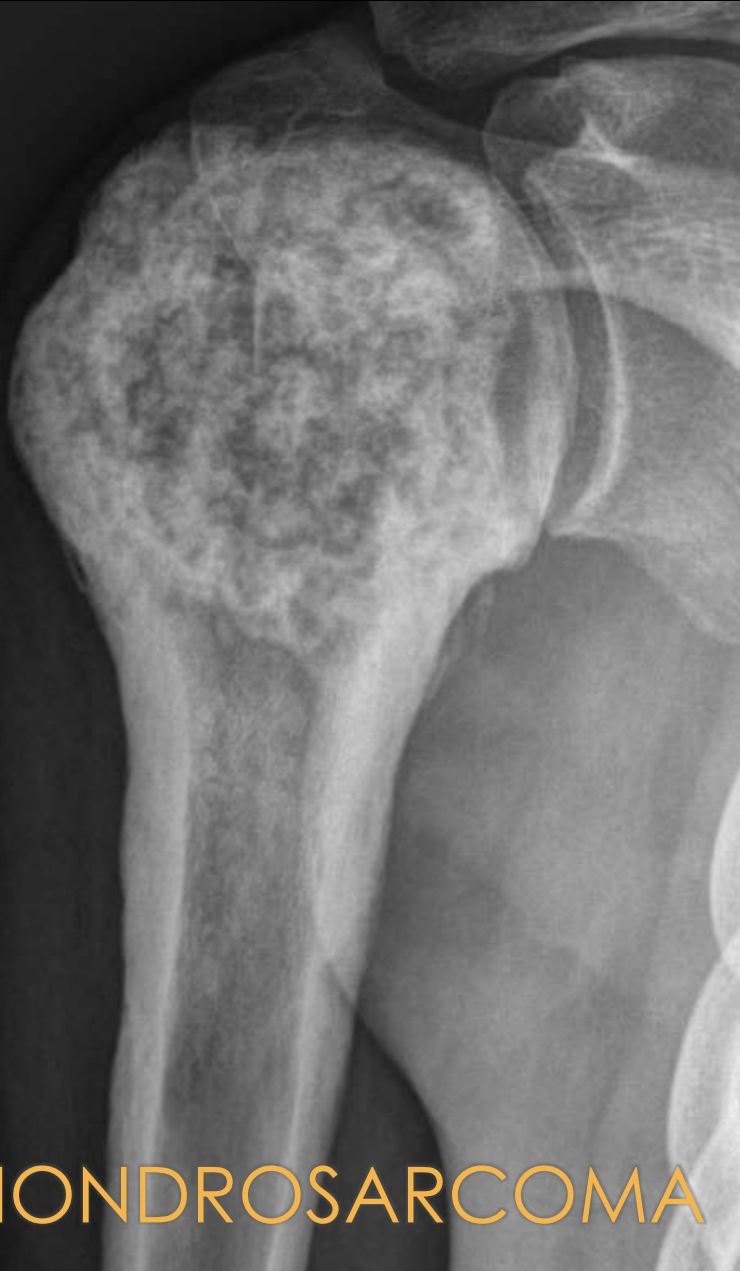CALCIFICATION IN ARCS AND RINGS;
"POPCORN" CALCIFICATION



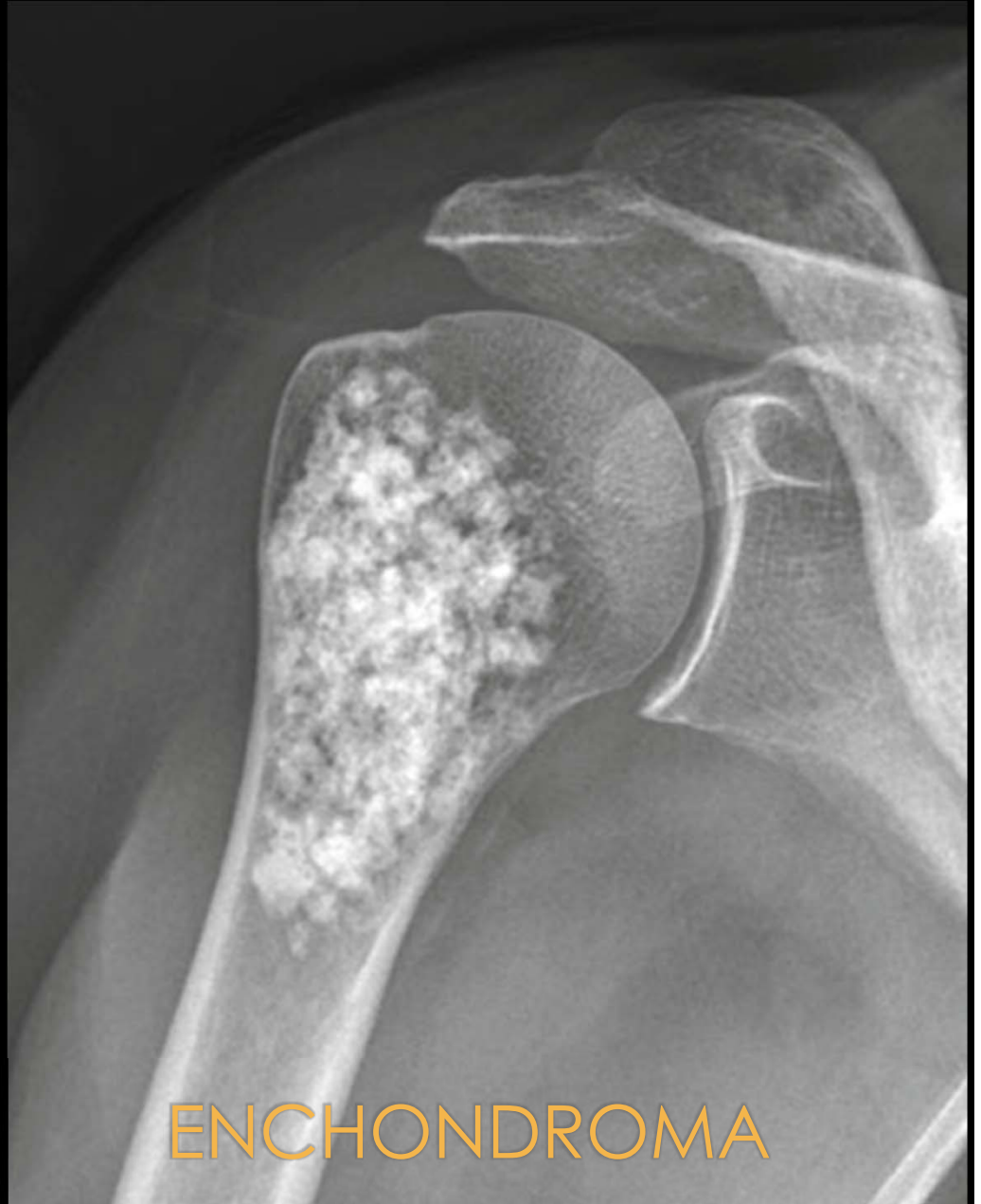CALCIFICATION IN ARCS AND RINGS;
"POPCORN" CALCIFICATION

9090

D



CHONDROSARCOMA

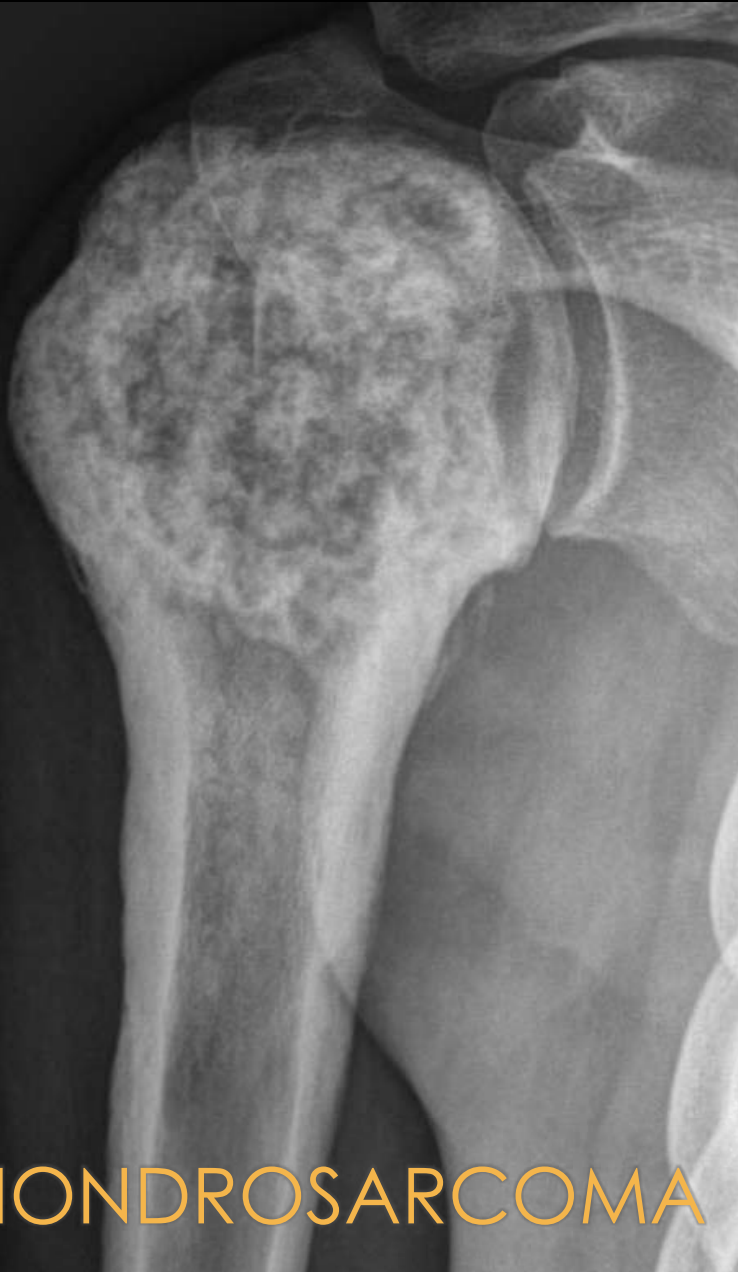

ENCHONDROMA

CORTICAL IRREGULAR, THICKENED

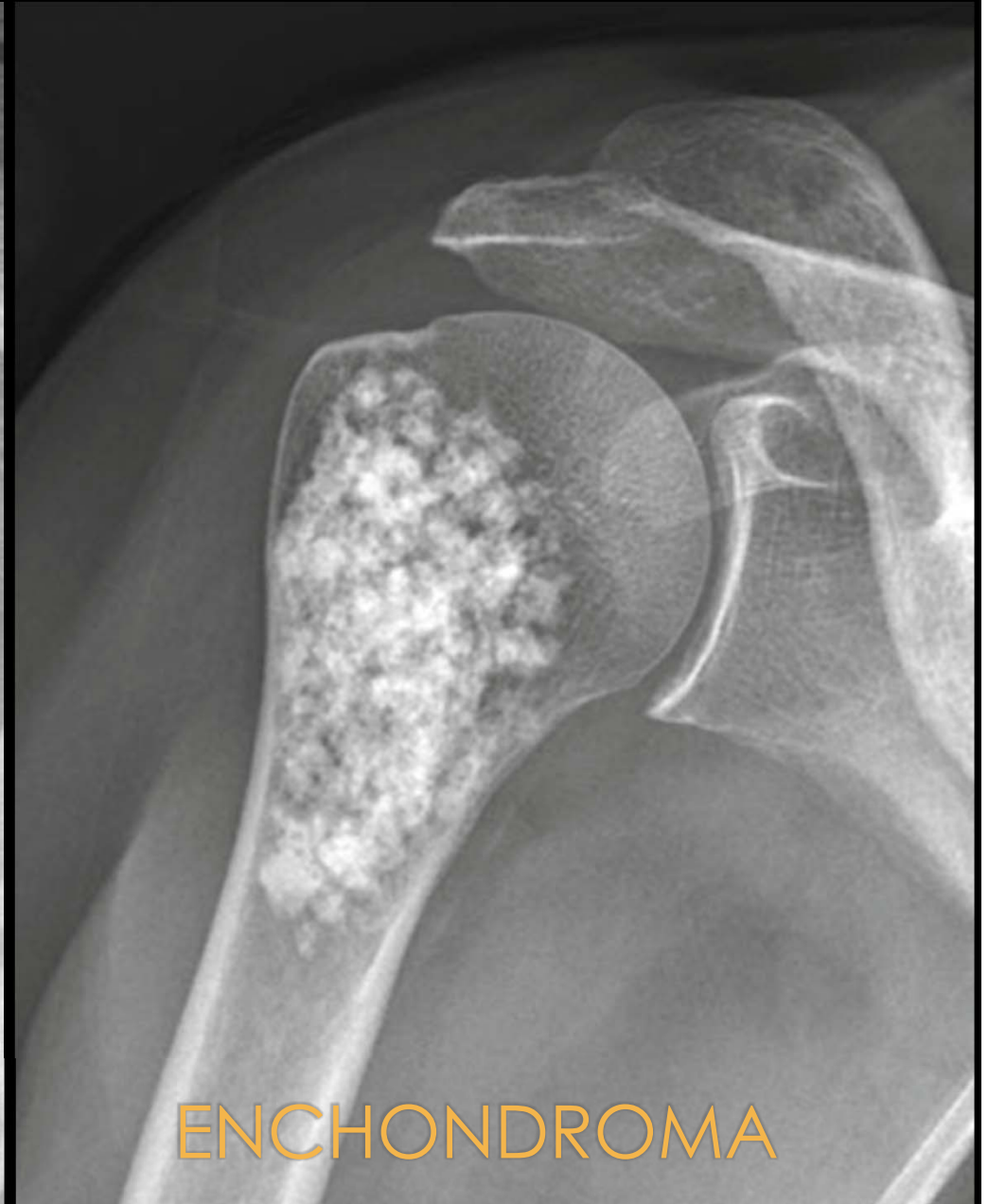9090

D

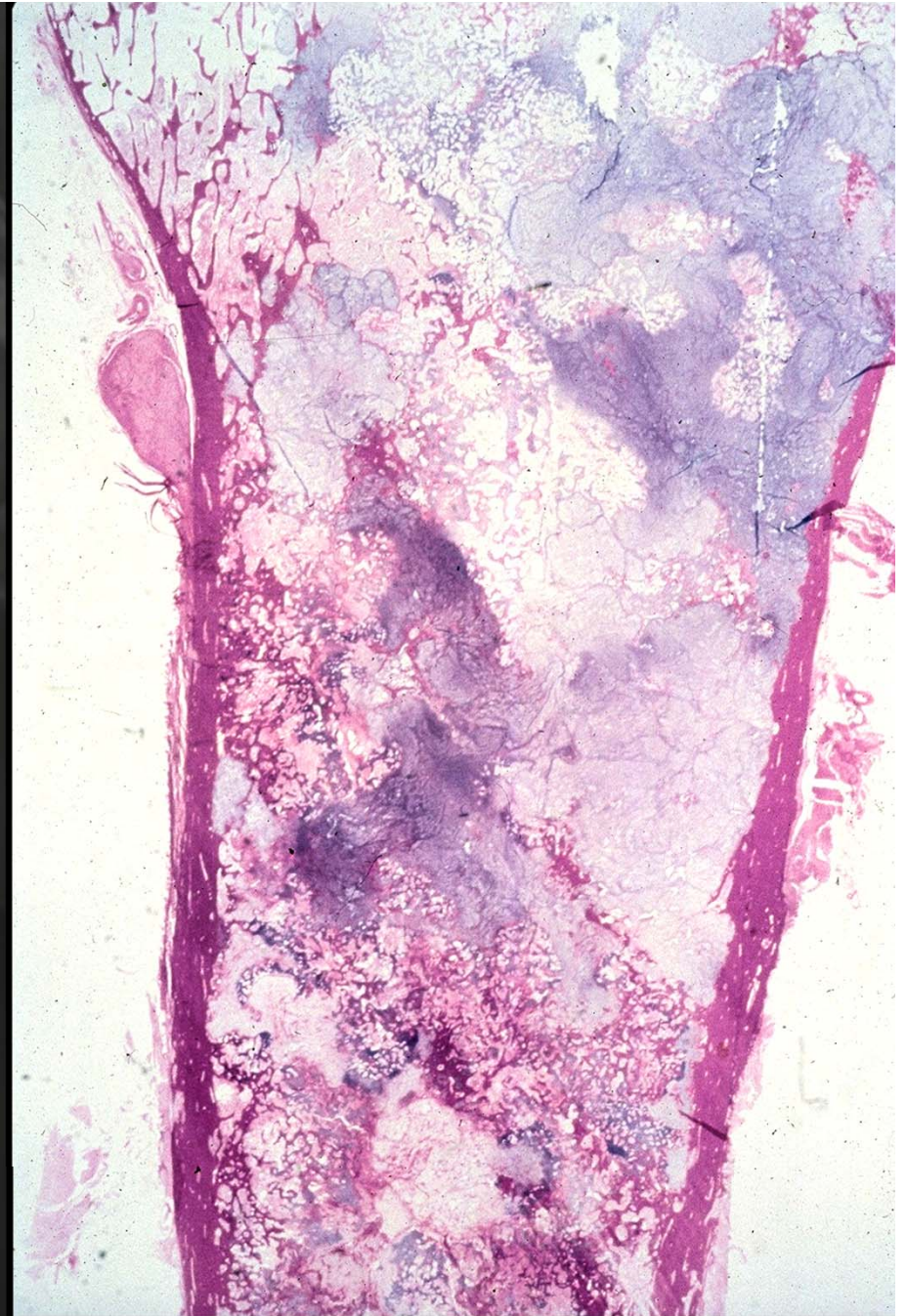
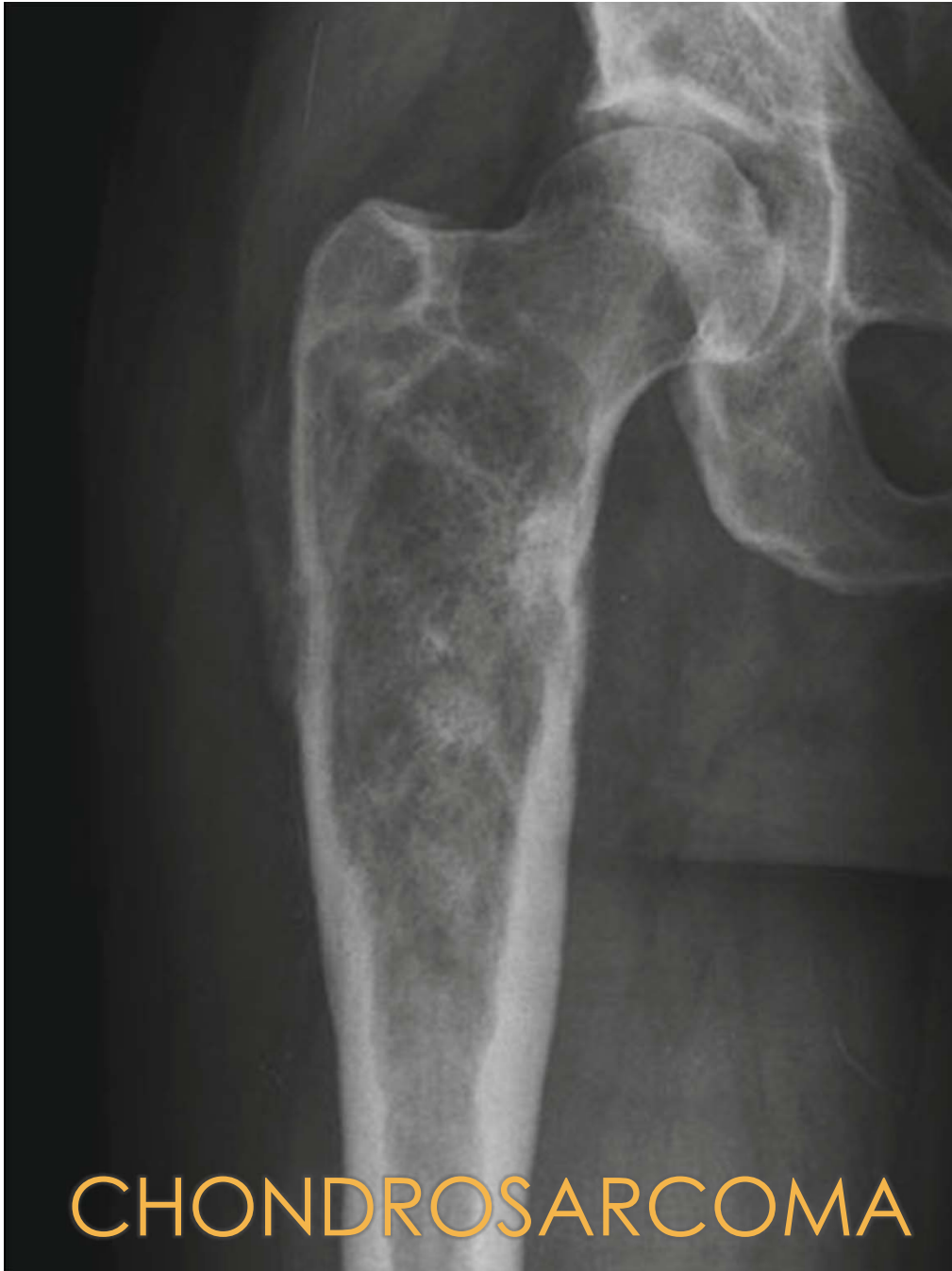
CHONDROSARCOMA

CORTICAL PRESERVED

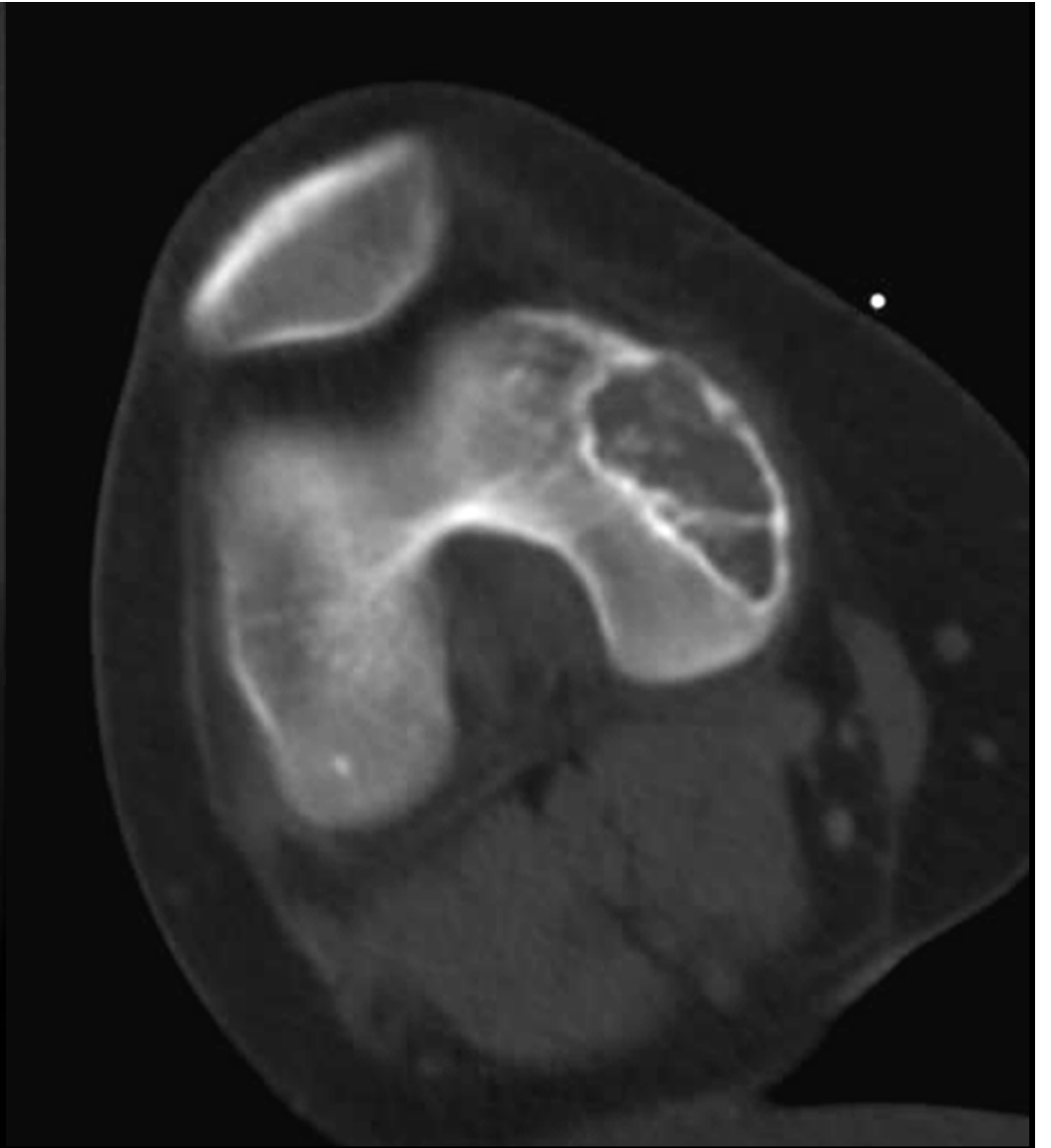
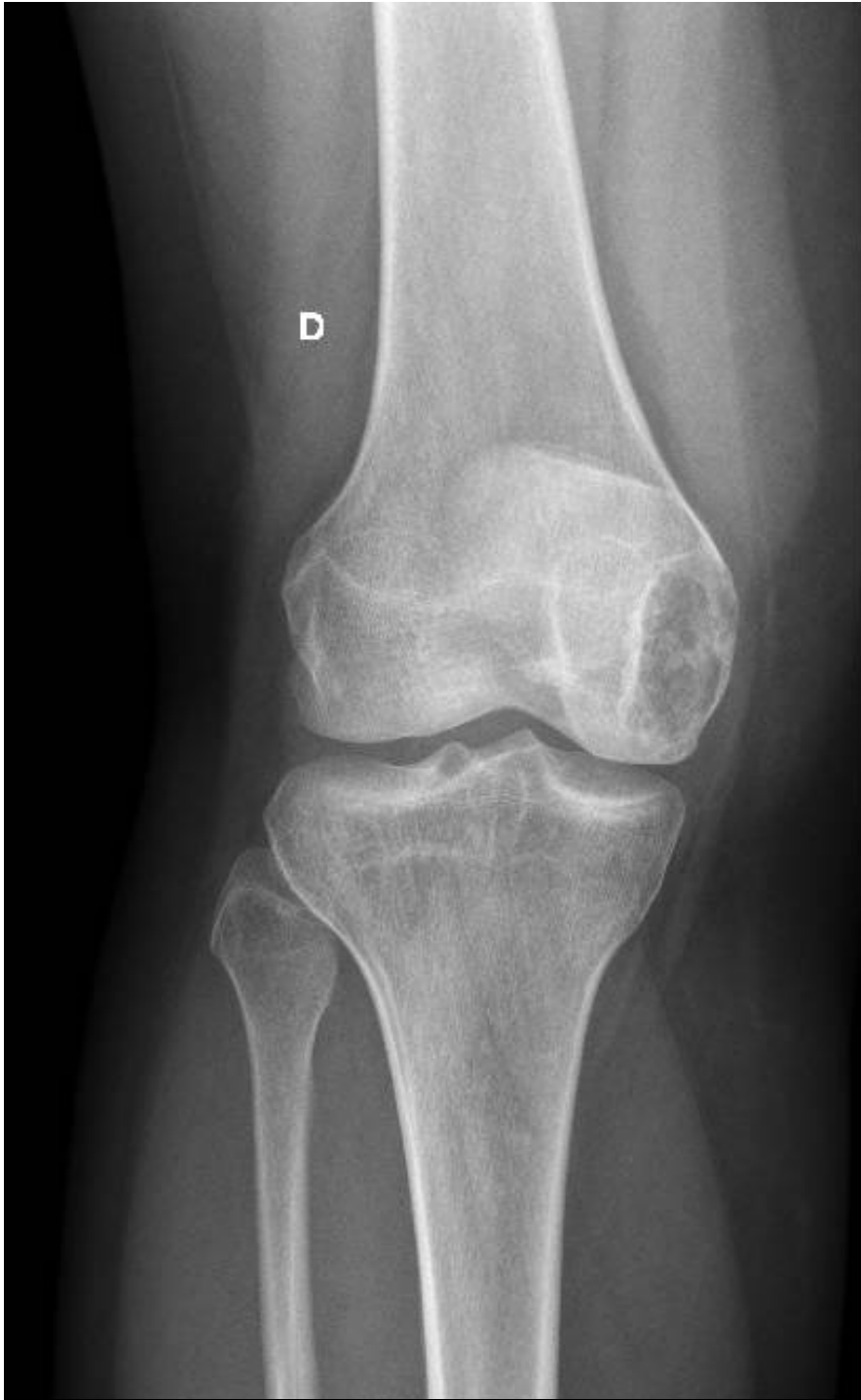


ENCHONDROMA

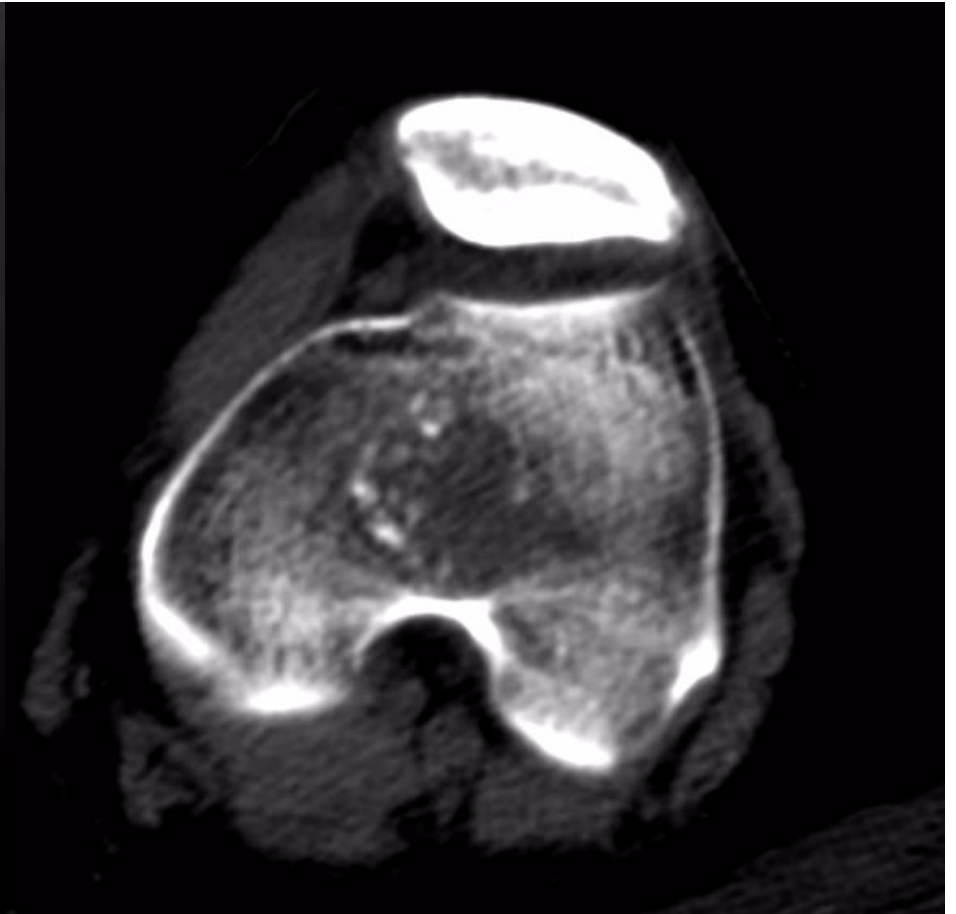
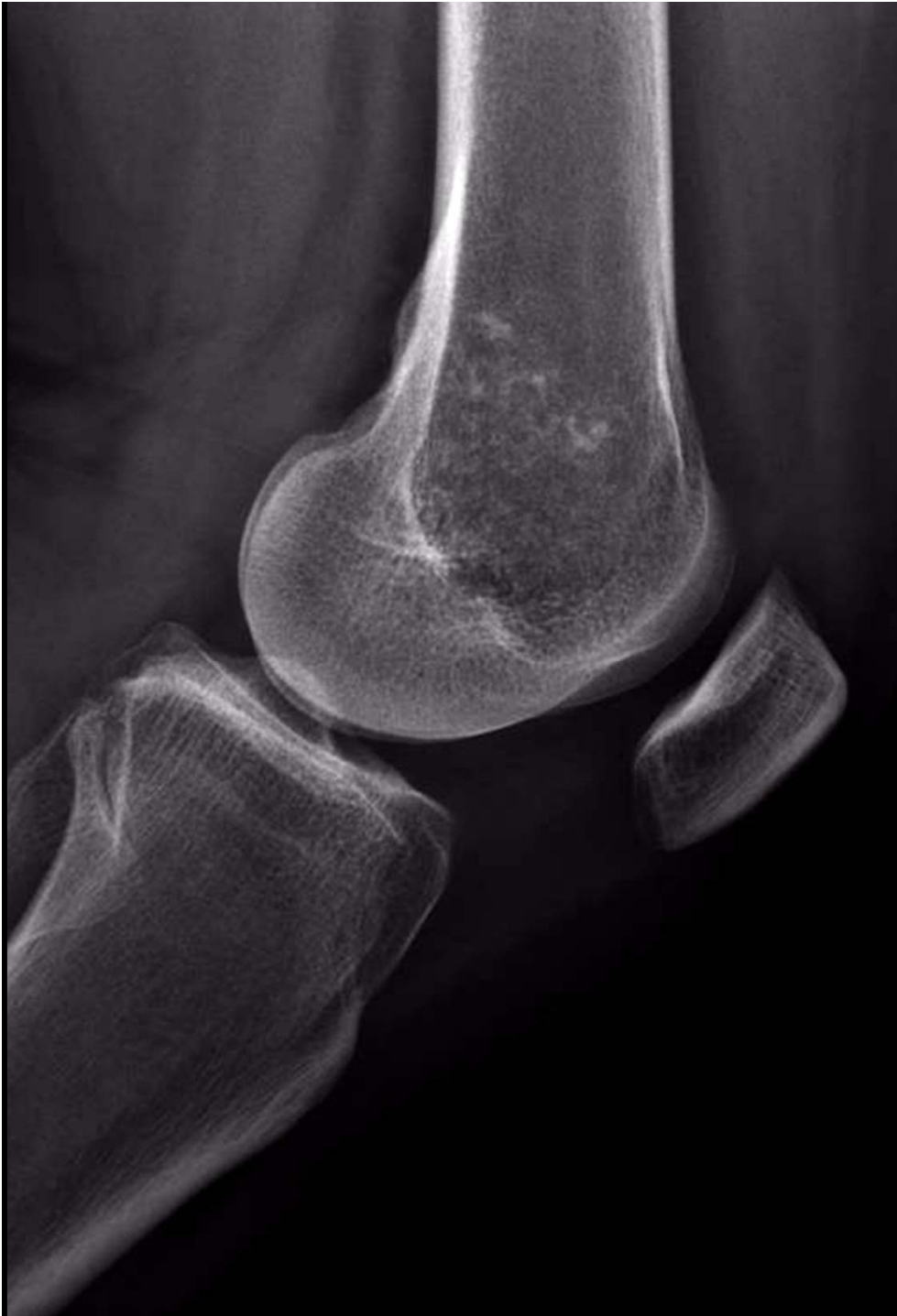

CHONDROSARCOMA

CORTICAL THICKENING, ENDOSTEAL EROSION AND BONE EXPANSION



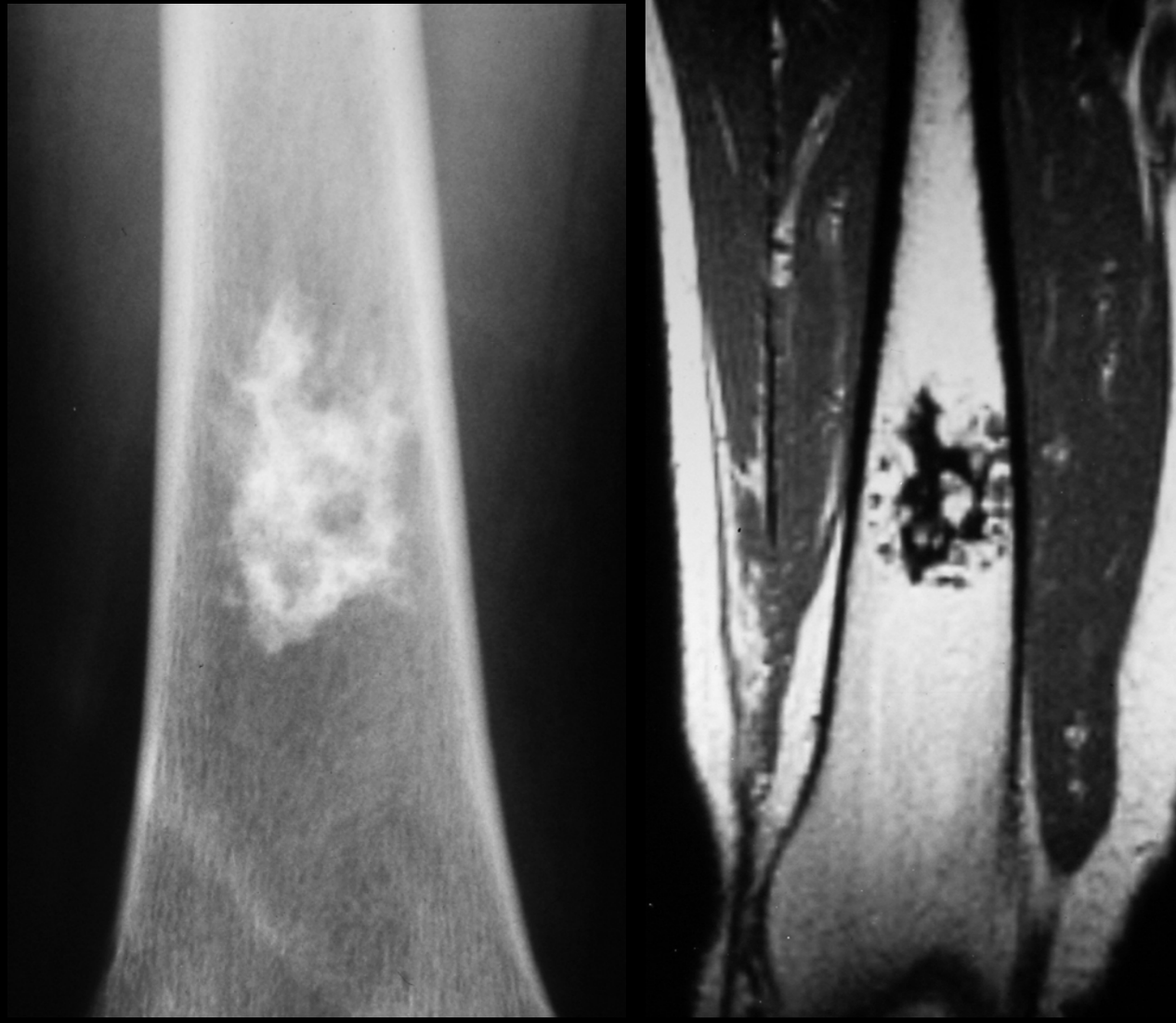
CORTICAL RESORPTION $\geq 2/3$:
BORDERLINE OR MALIGNANT

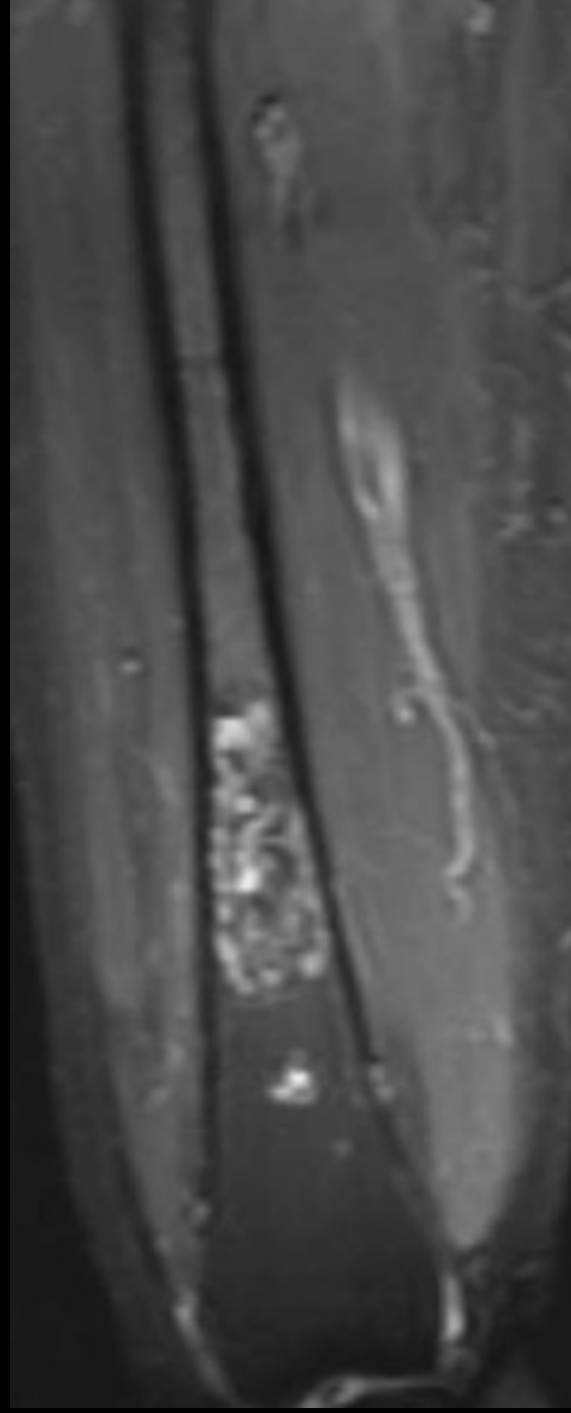
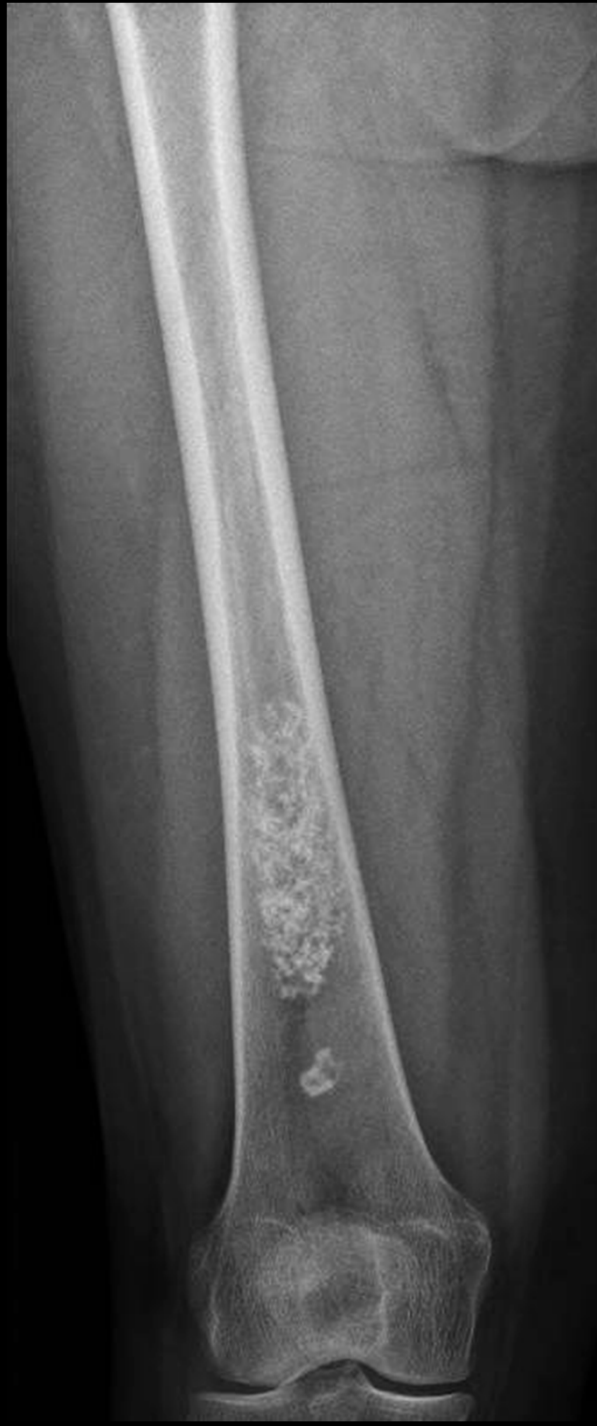

CORTICAL UNTOUCHED:
PROBABLY BENIGN

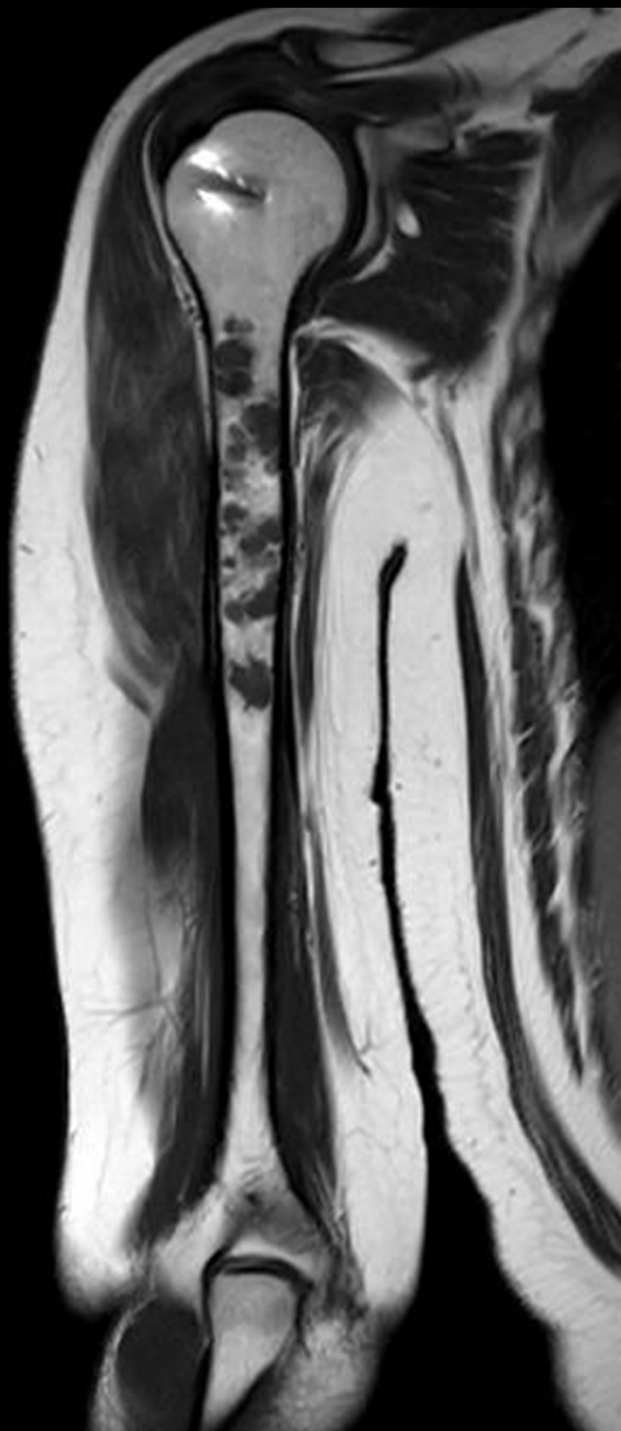
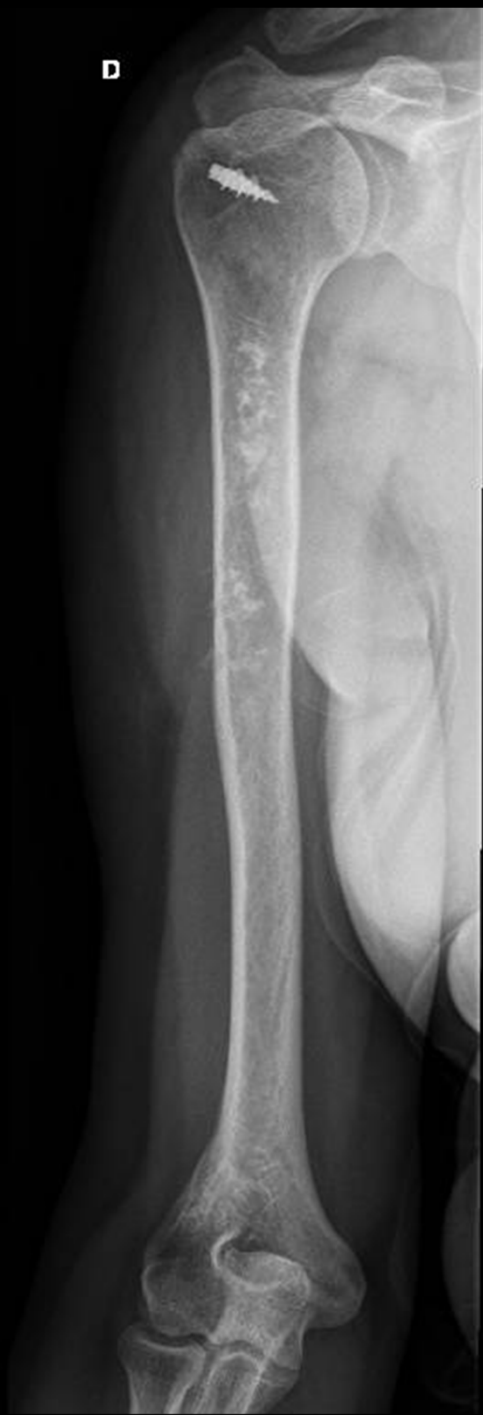CHONDROMA - MRI

VOLUME OVERLAP XR/MRI

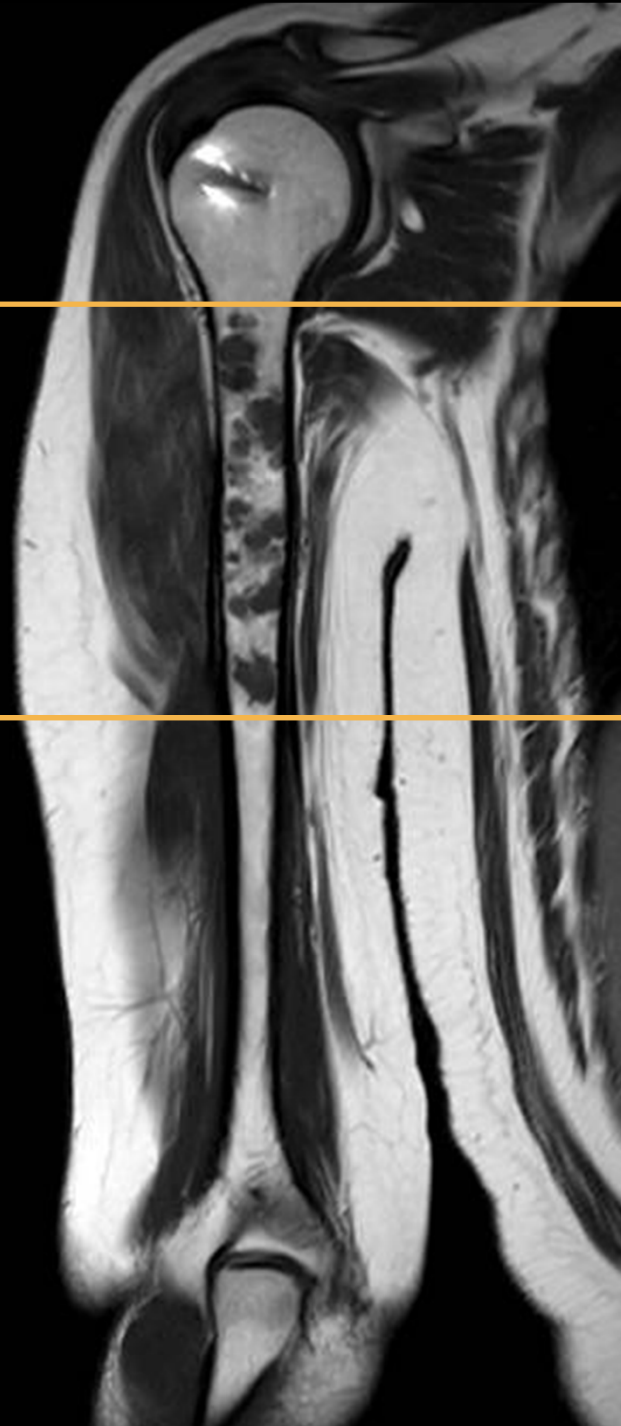
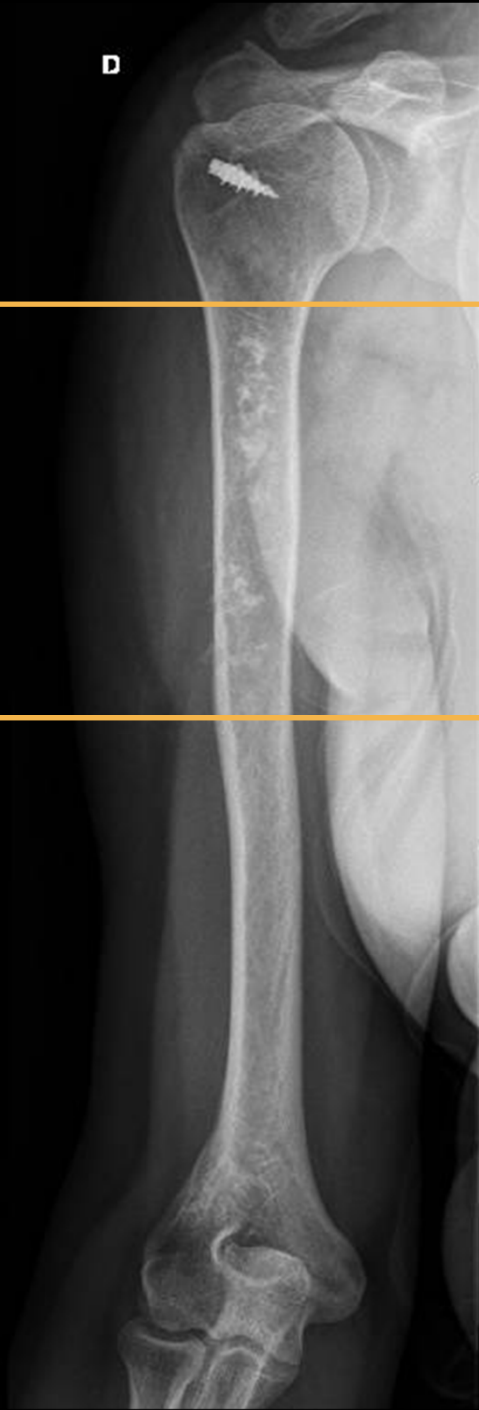




D



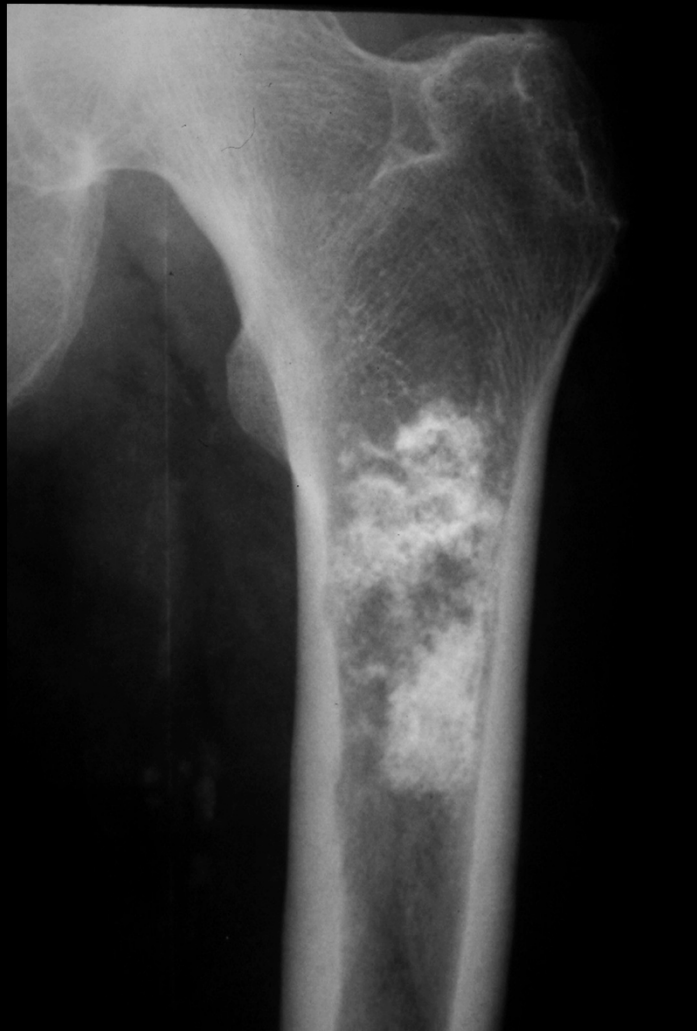D

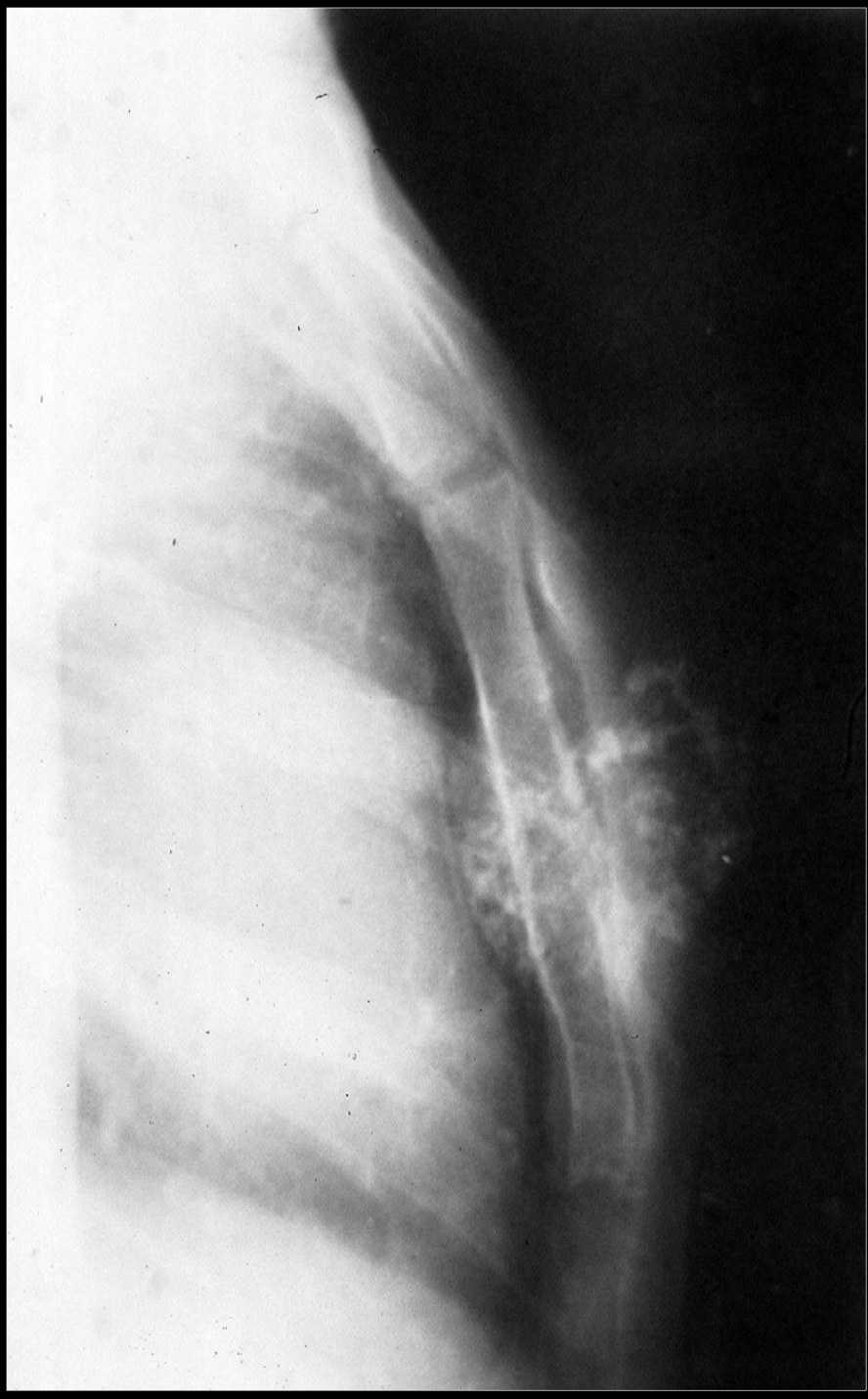
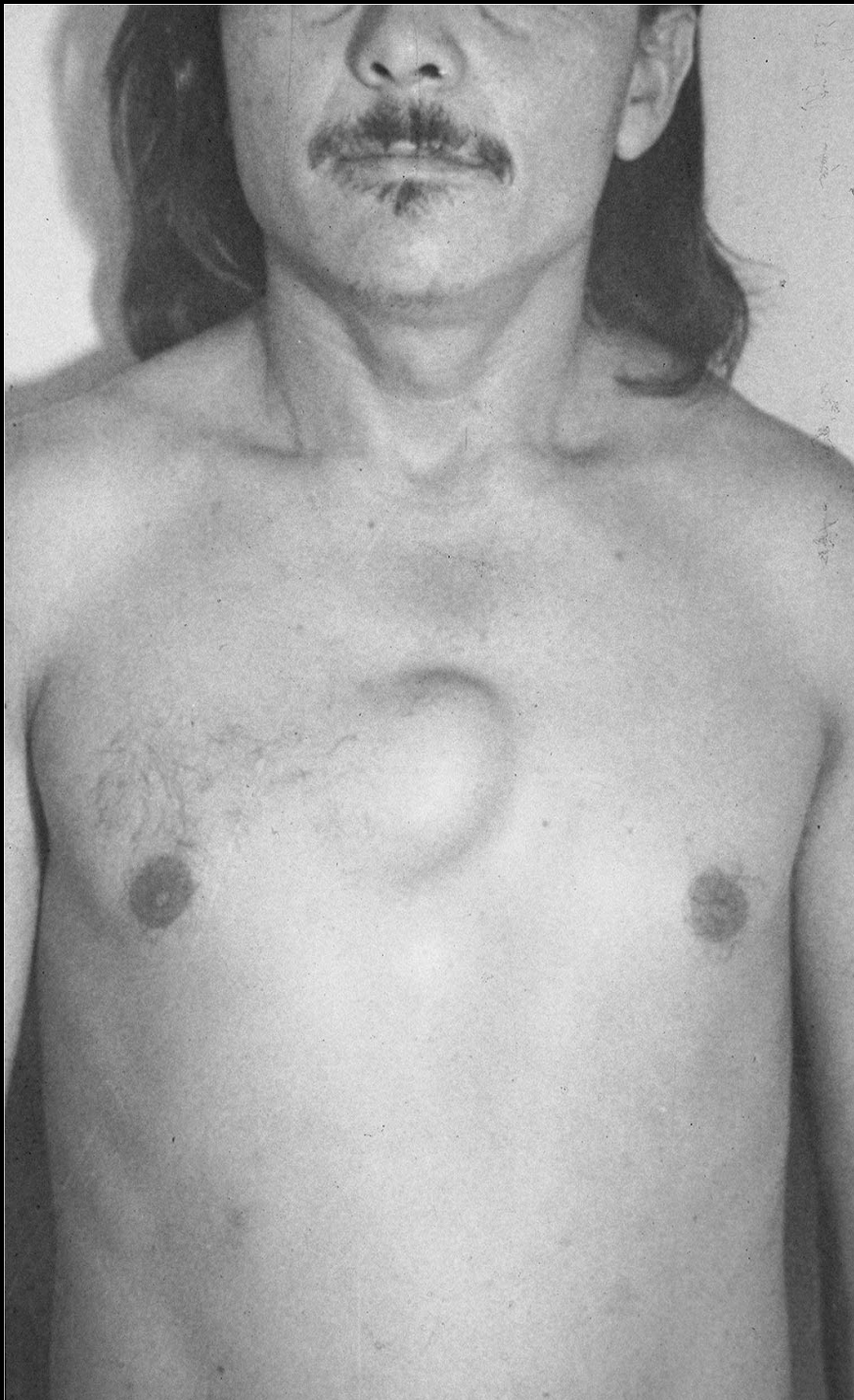


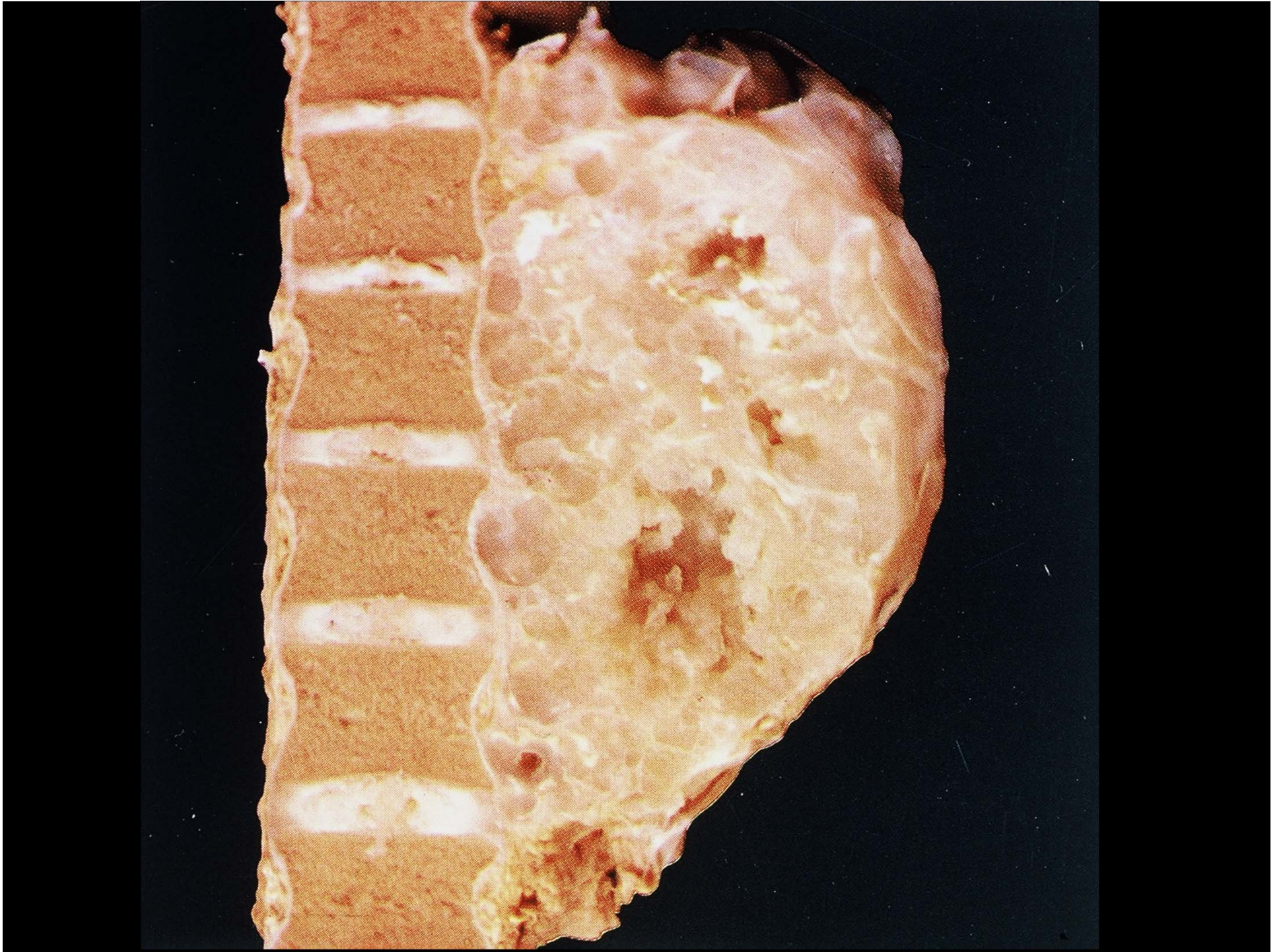
CHONDROSARCOMA - MRI

VOLUME LARGER IN MRI THAN XR

- BONE MARROW EDEMA
- SOFT TISSUE INVOLVEMENT







CHONDROMATOUS LESIONS

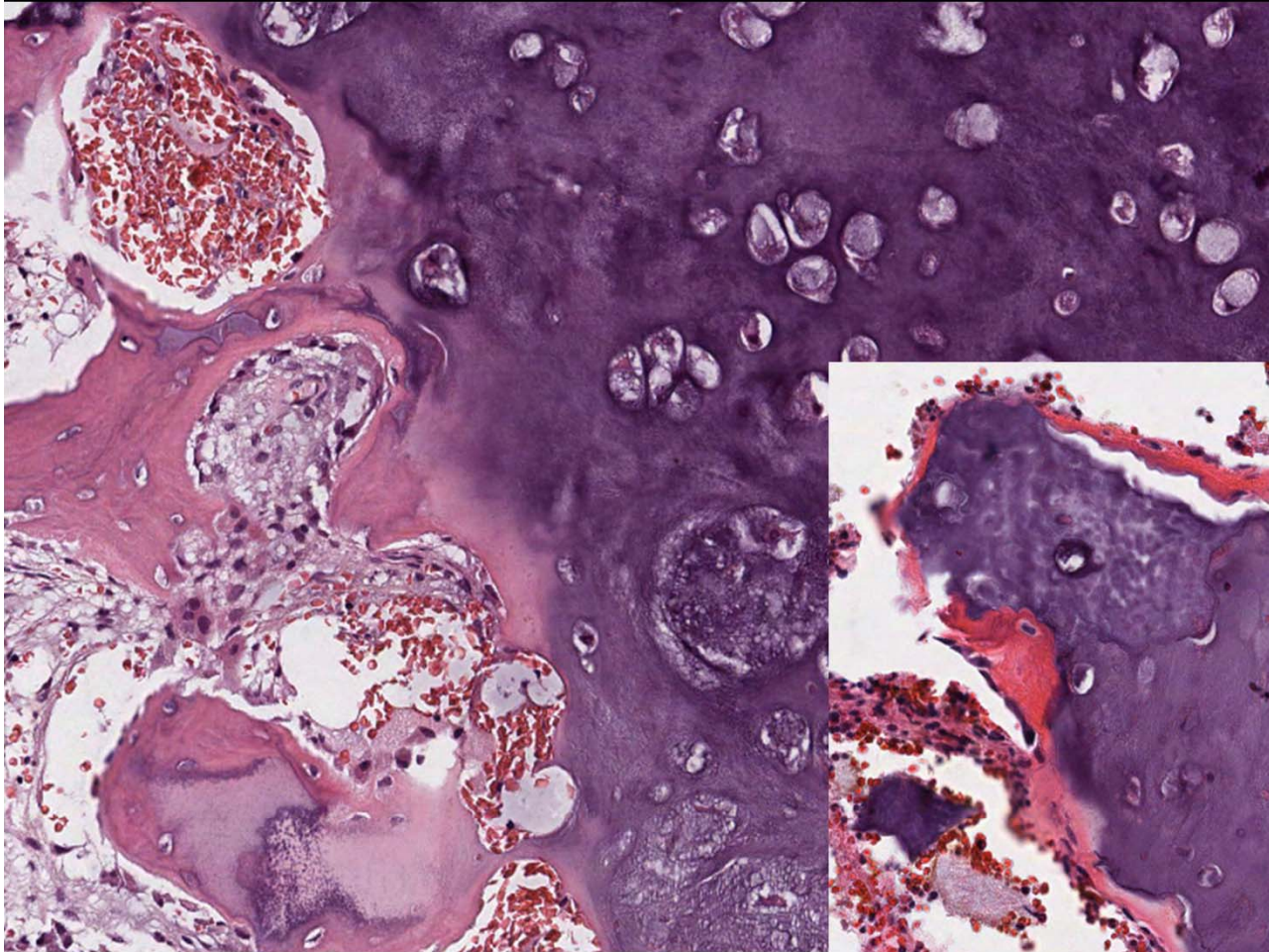
- in the axial skeleton, especially in sternum, pelvis and spine,
- presenting growth during adulthood,

are almost certain to be clinically malignant

CARTILAGINOUS TUMORS IN LONG BONES

MICROSCOPY

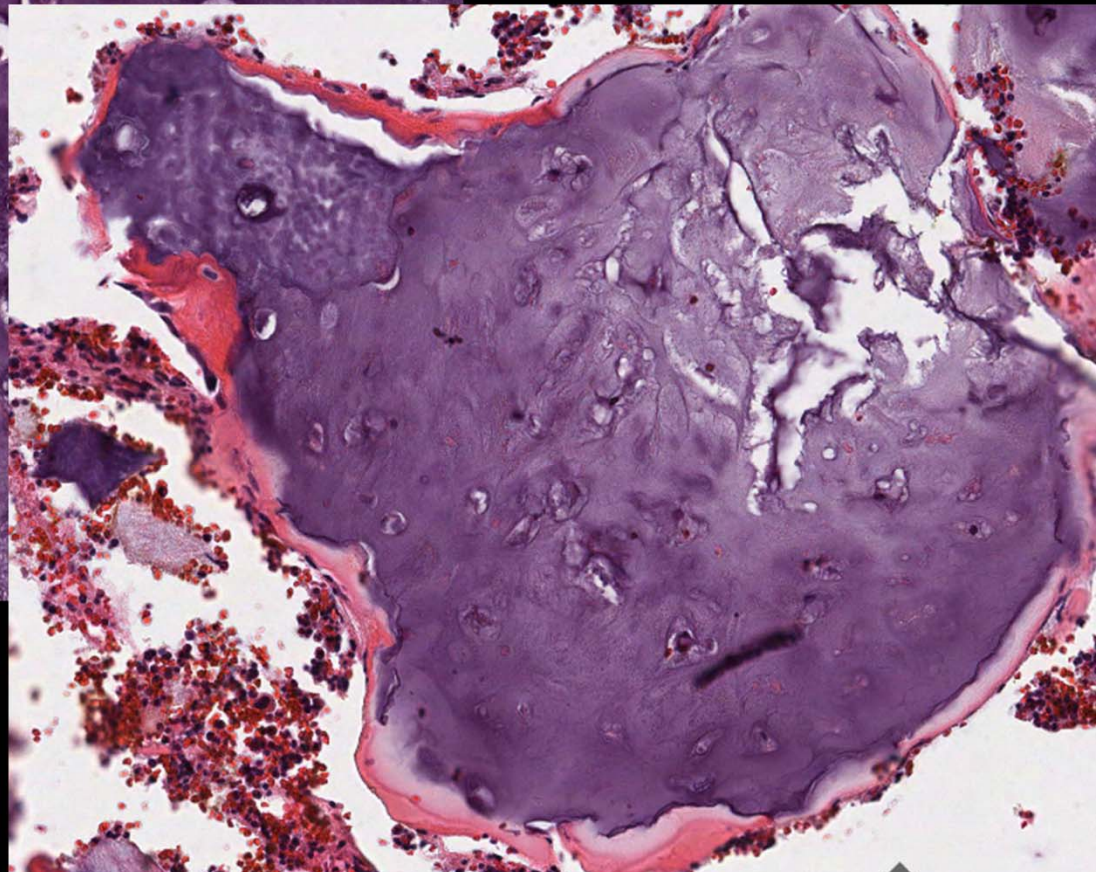
CHONDROMA IN LONG BONES



LOW CELLULARITY

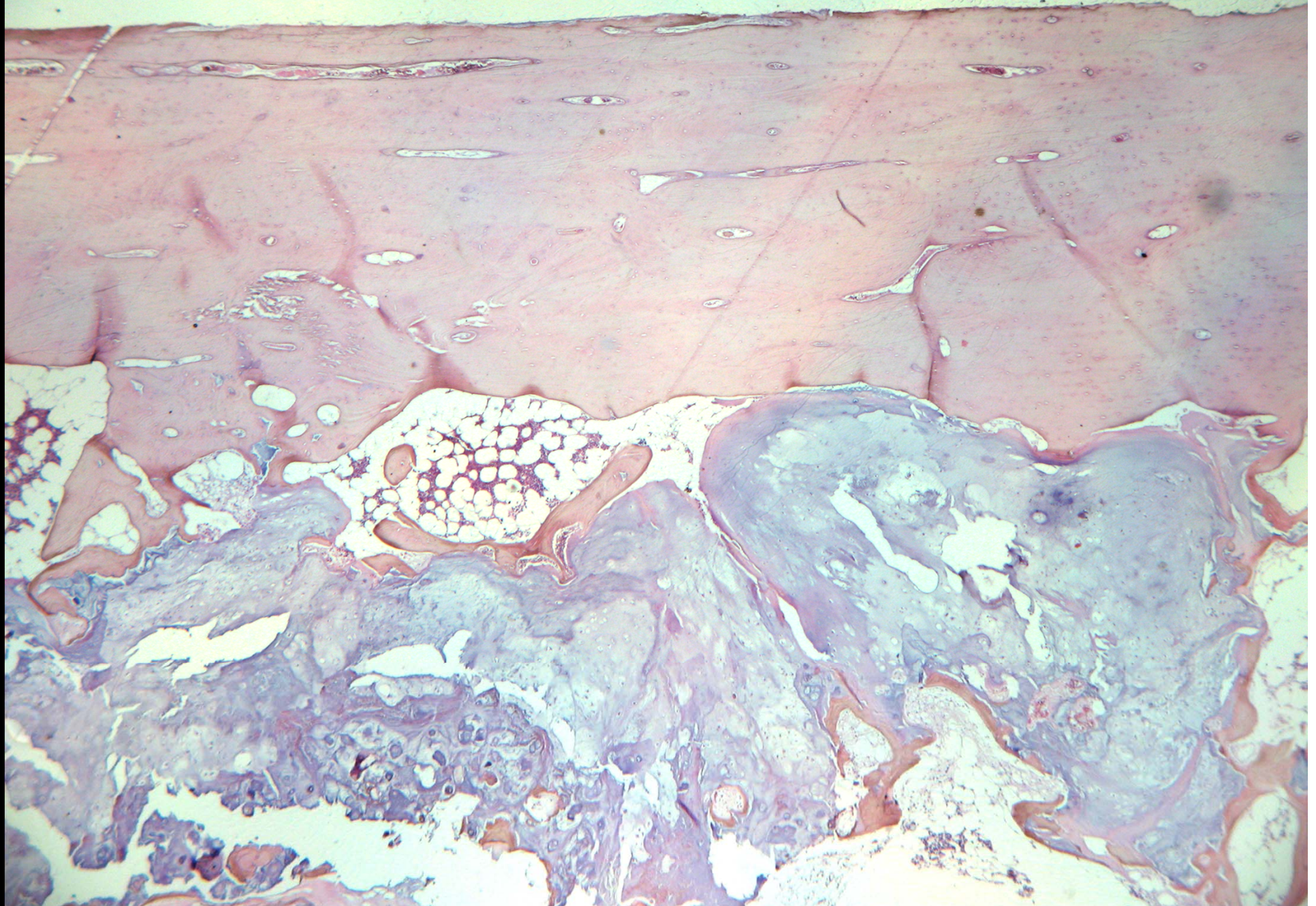
WELL-DIFFERENTIATED

CLEAR LIMITS WITH
BONE MARROW

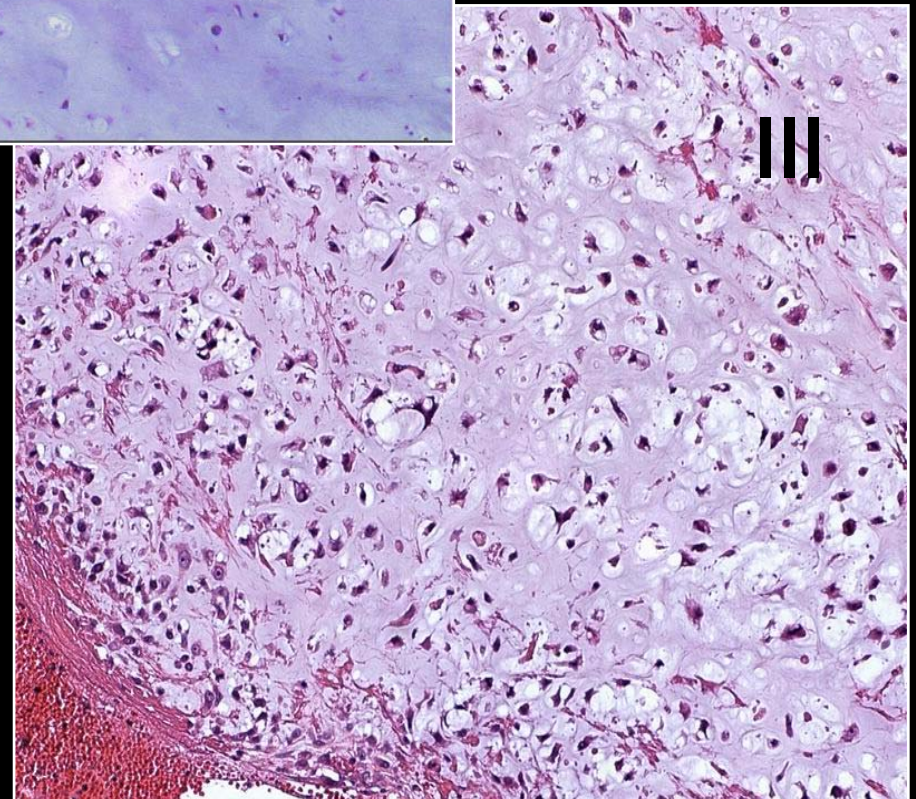
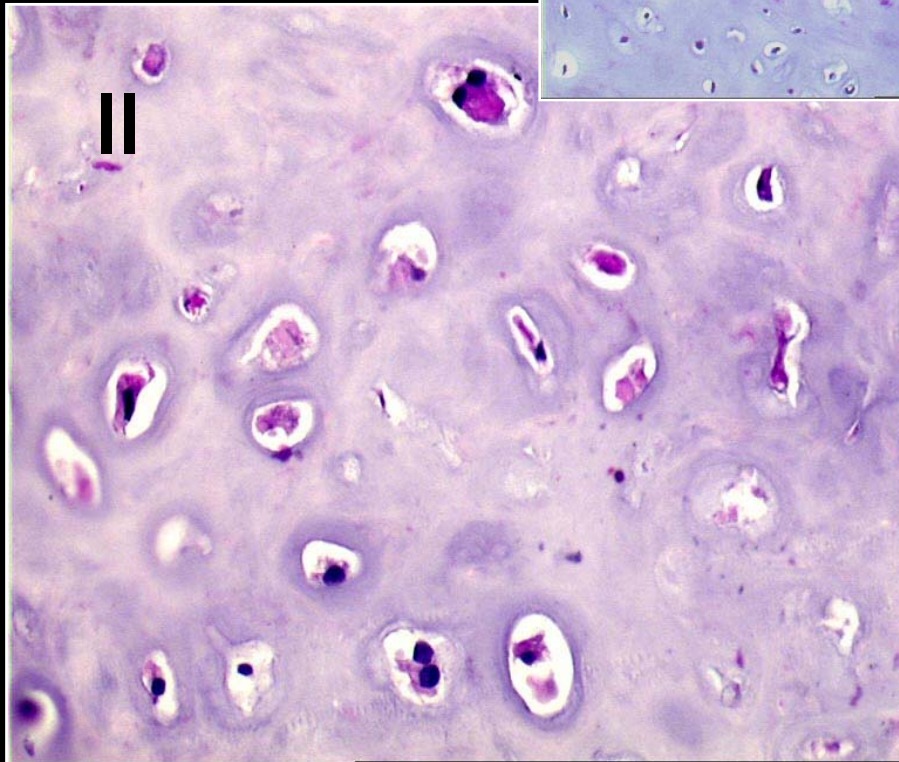
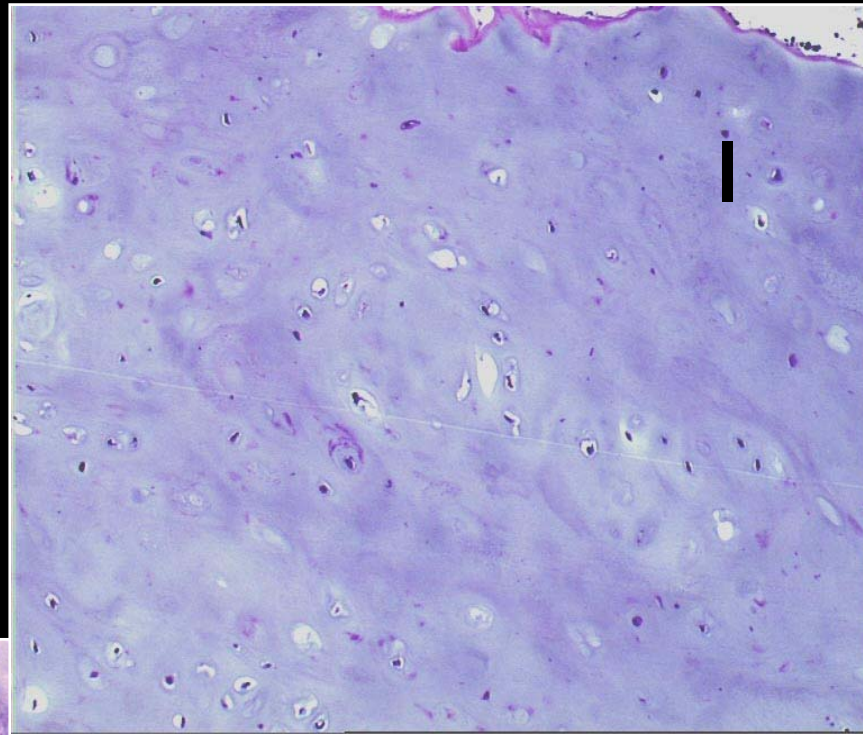


ENCHONDRAL
OSSIFICATION AT
PERIPHERY OF
CHONDRID LOBULES

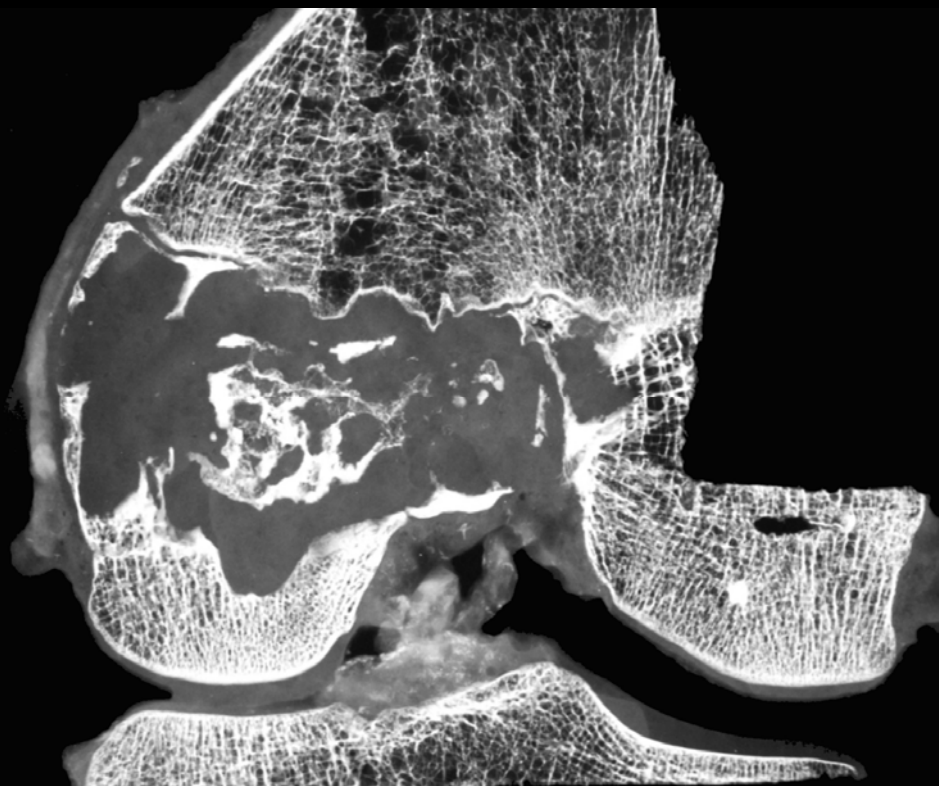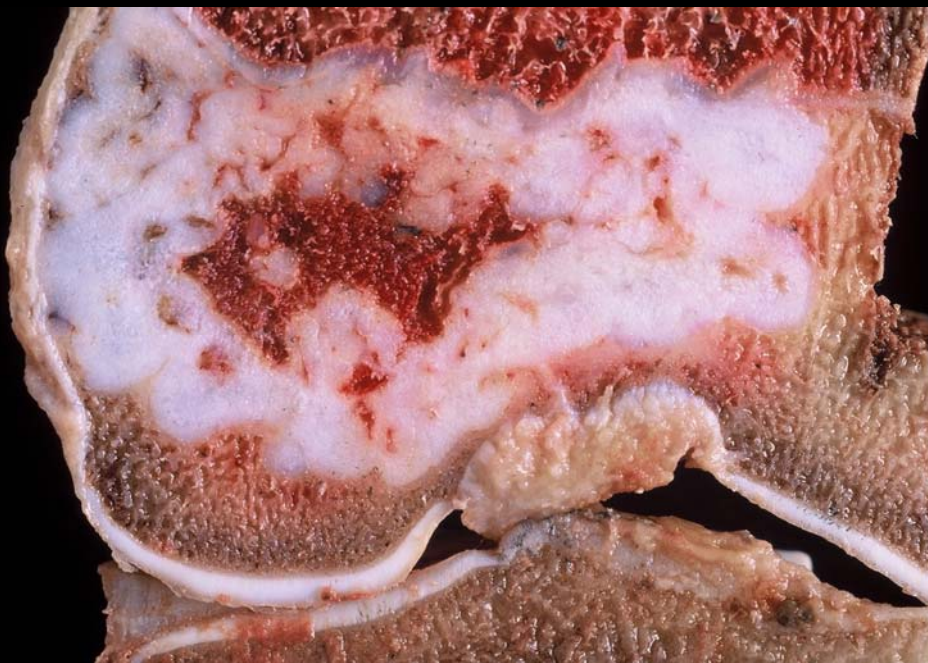
NO OR VERY LITTLE CORTICAL ENDOSTEAL RESORPTION



CHS GRADING



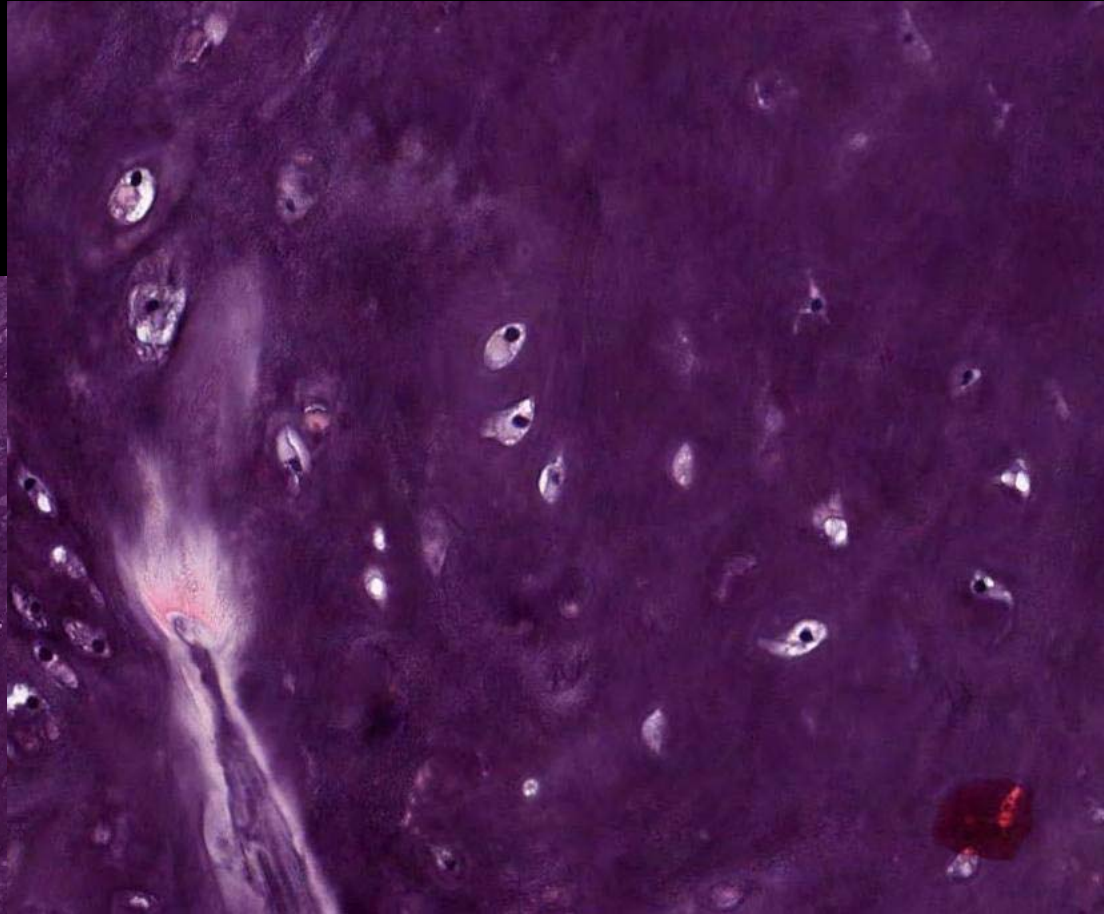
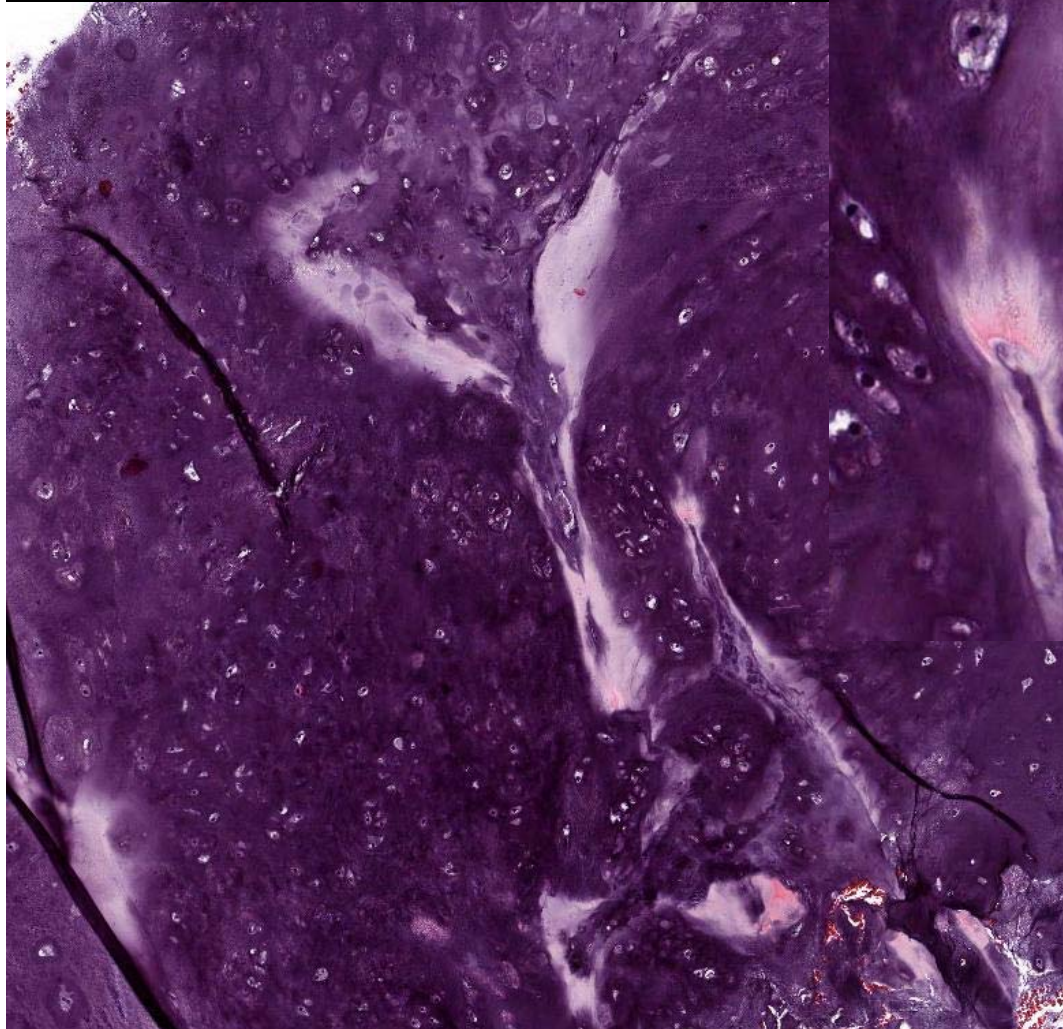
CHONDROSARCOMA, GRADE I



CHONDROSARCOMA I

Histology

Benign/Low Grade/Borderline/
Intermediary/Grade I



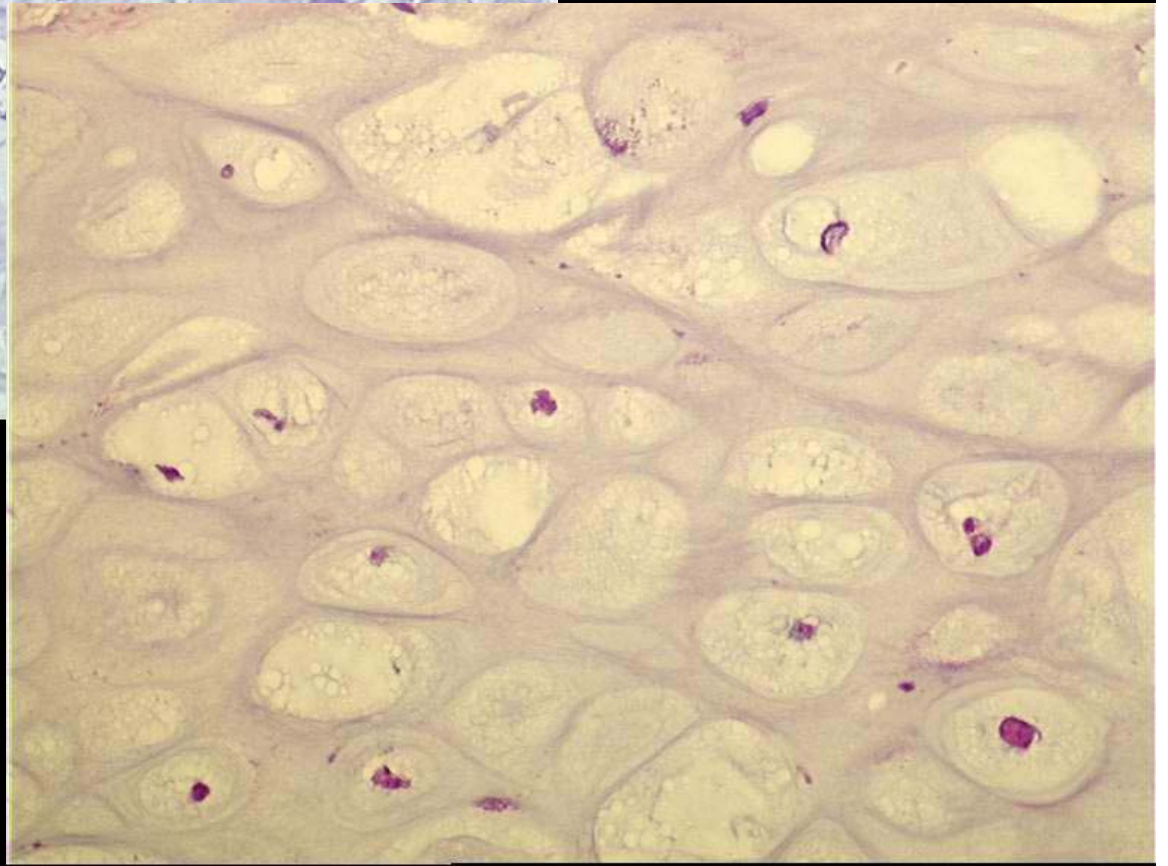
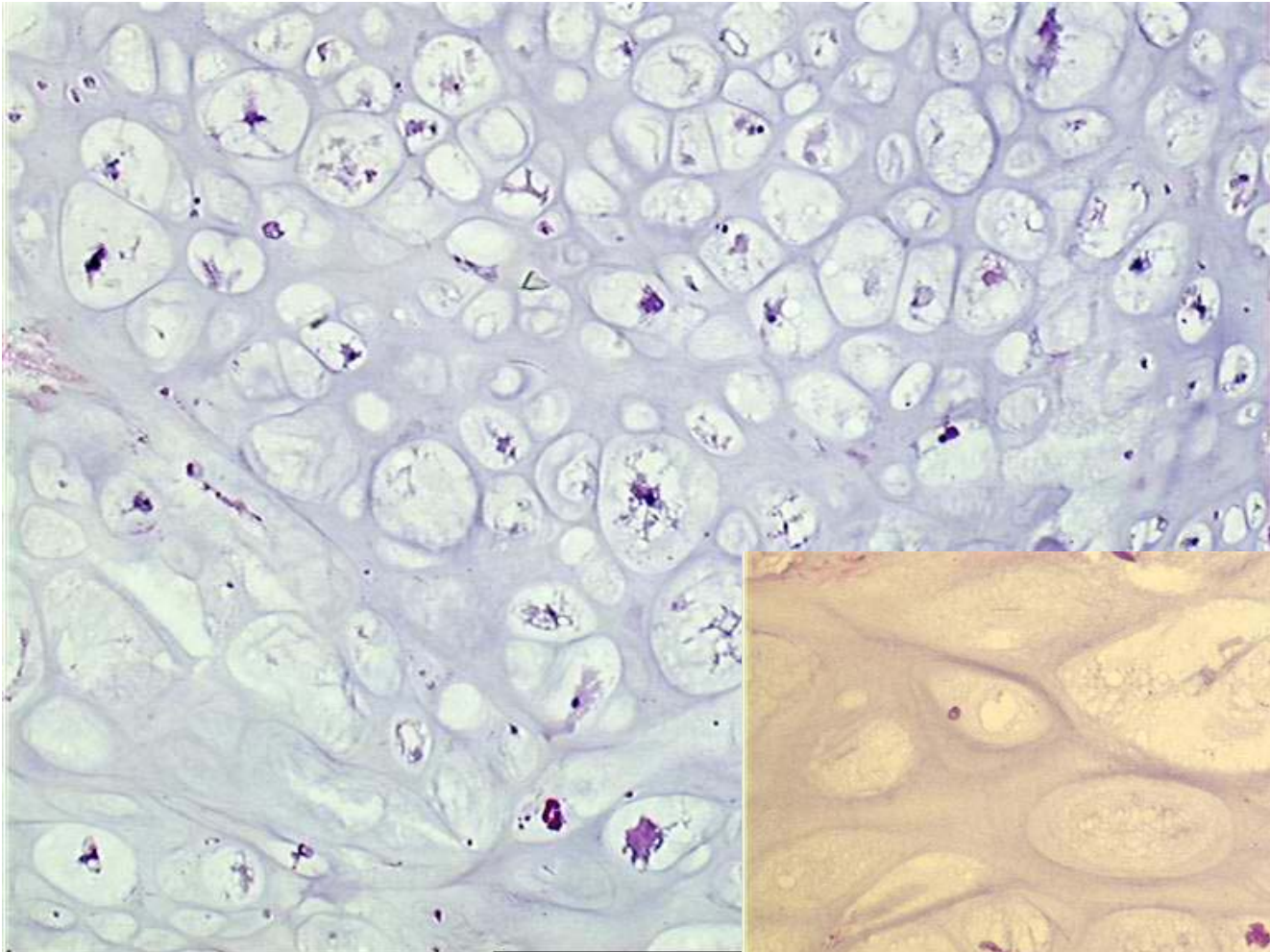
LOW-GRADE, GRADE I CHONDROSARCOMA,

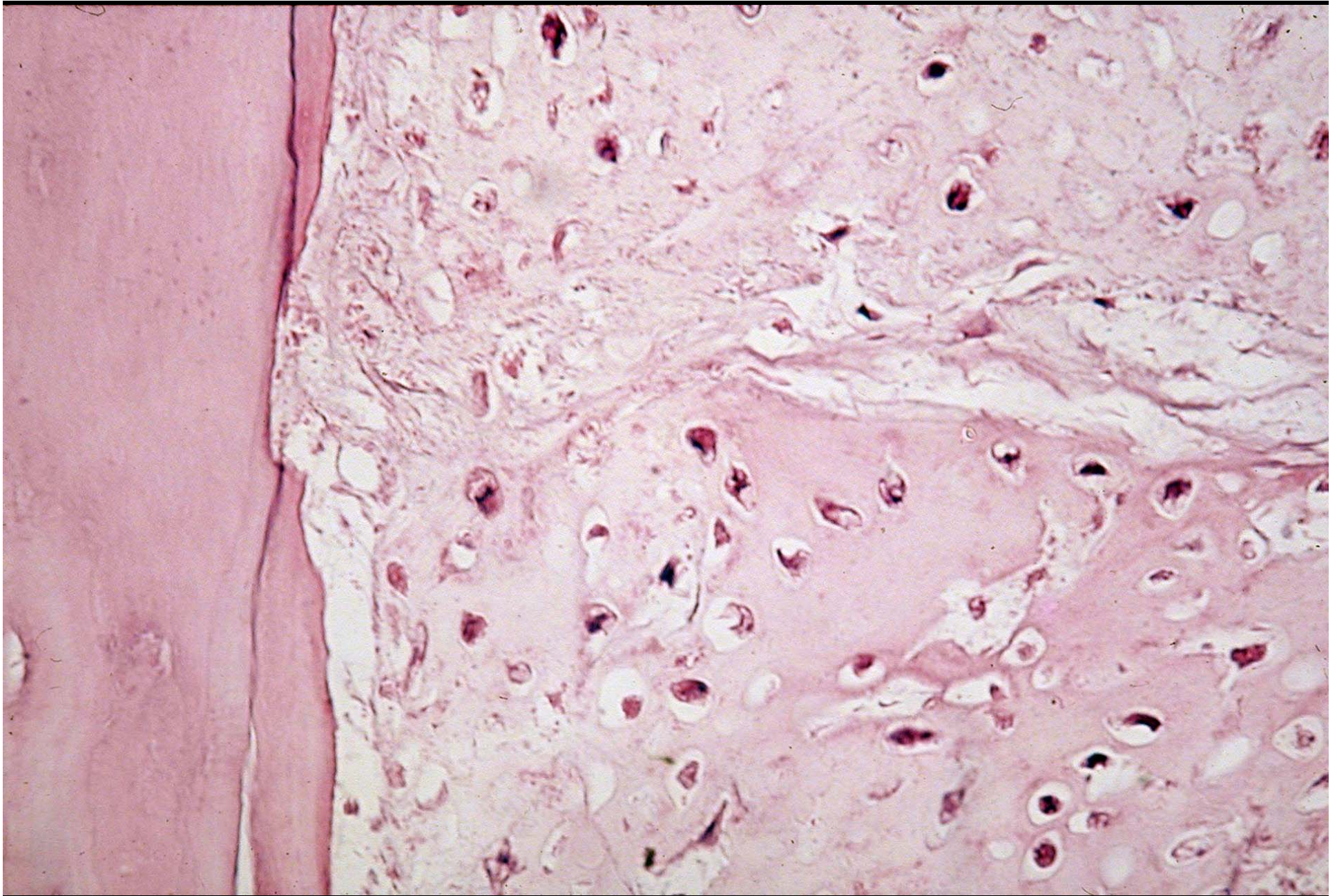
IS DIAGNOSED WHEN THE HISTOLOGIC FEATURES ARE NOT SUFFICIENT TO DIAGNOSE GRADE I CHONDROSARCOMA

BUT THE ROENTGENOGRAMS SHOW FEATURES OF AN AGGRESSIVE NEOPLASM, ESPECIALLY IN THE FORM OF ENDOSTEAL EROSION”

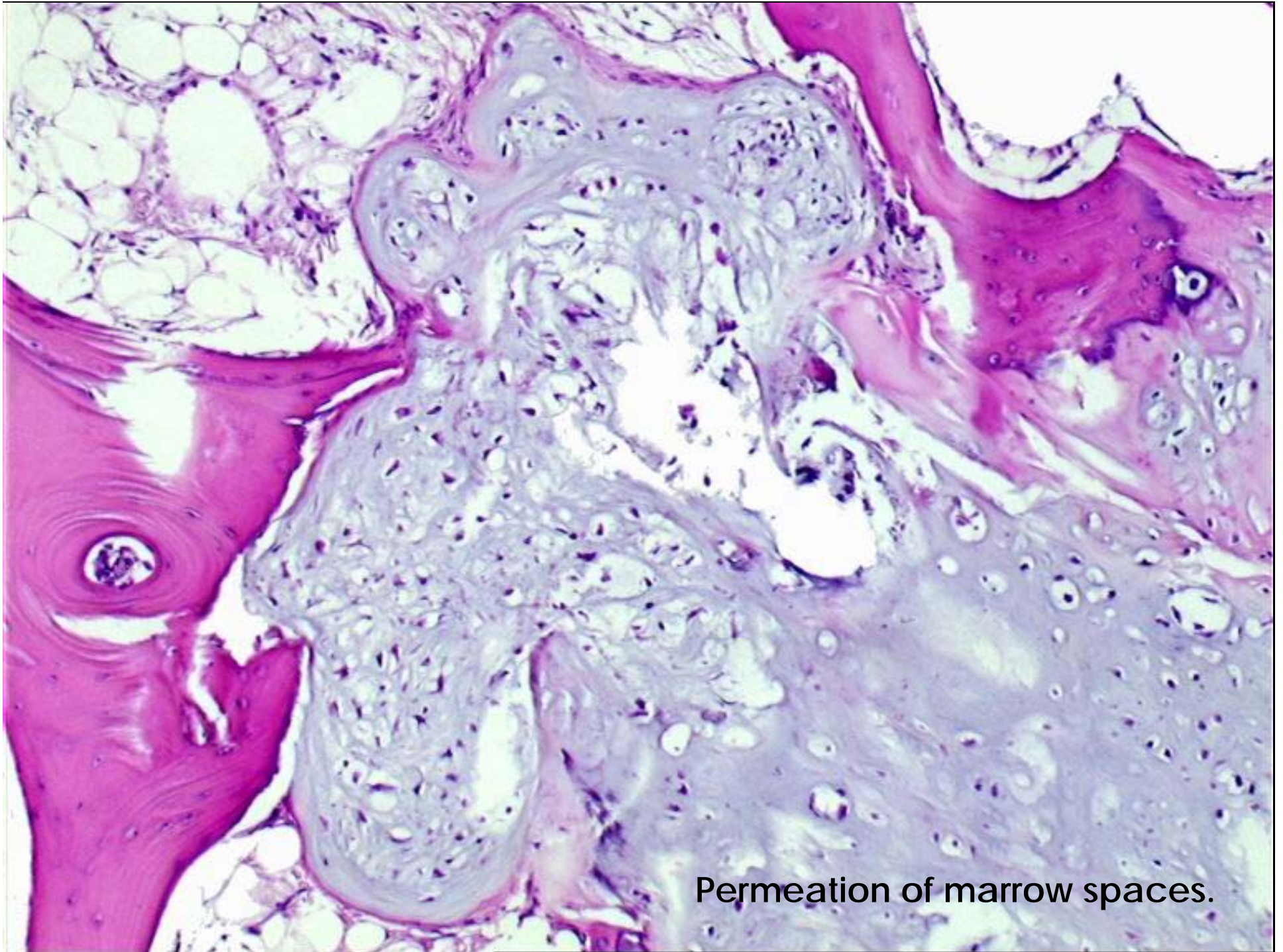
K. K. UNNI

DAHLIN'S BONE TUMORS.5TH ED.1996.



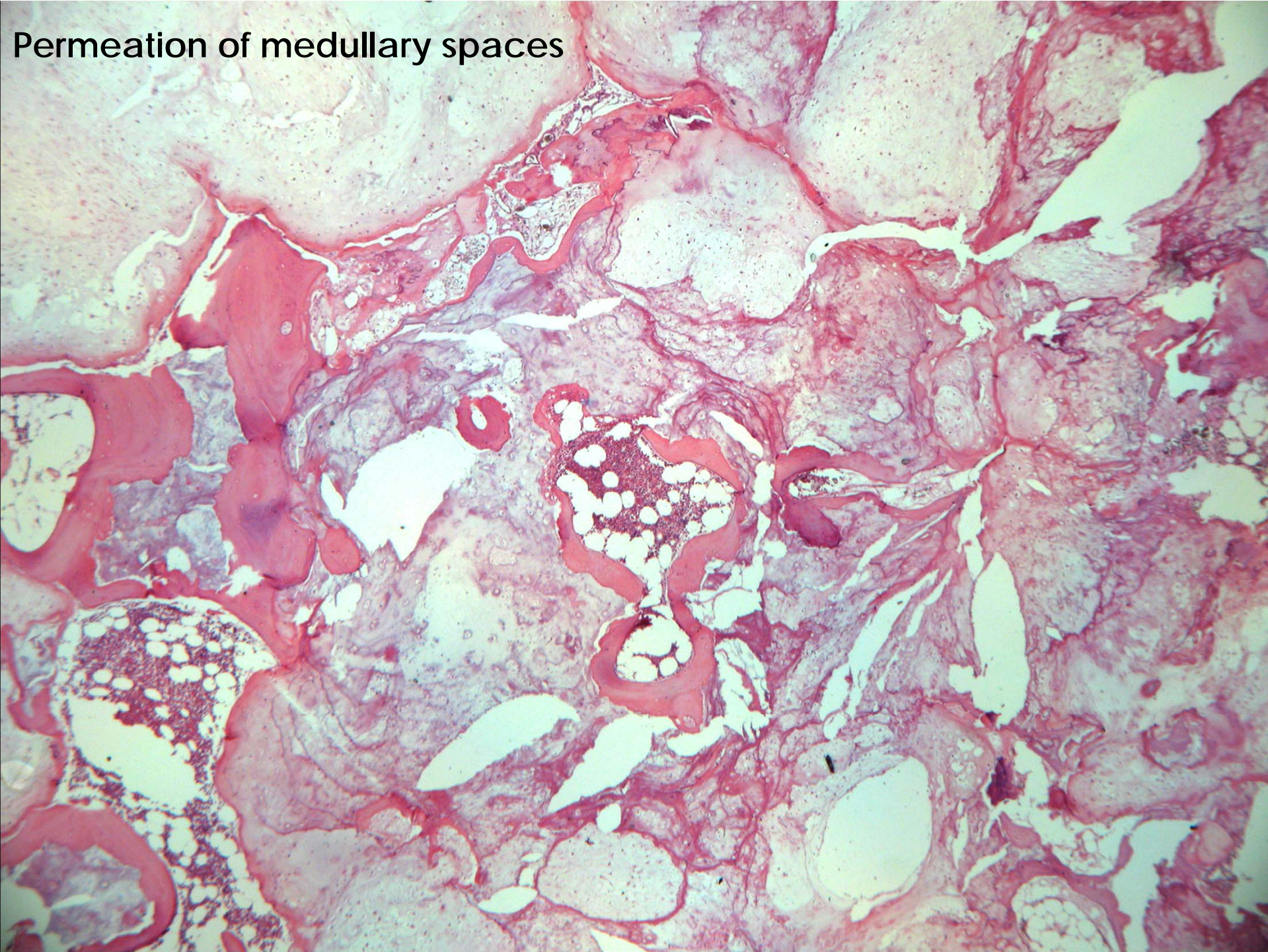

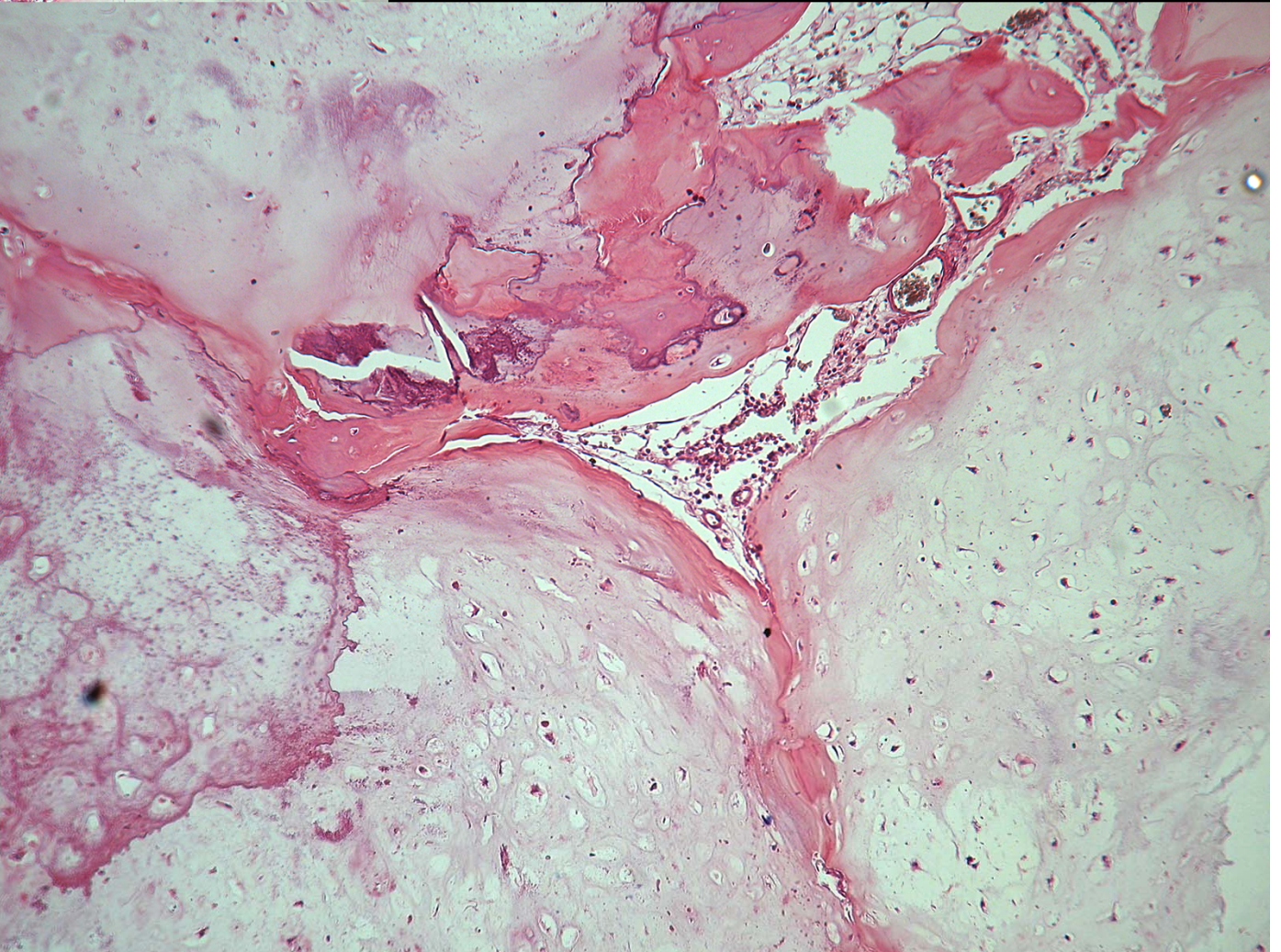

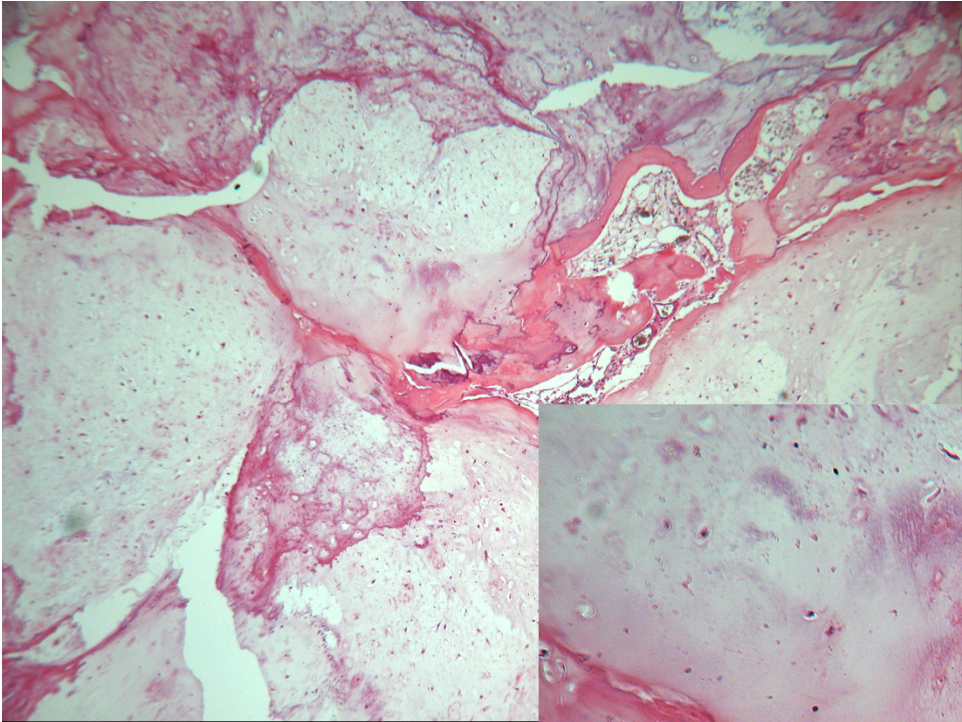
Endosteal resorption

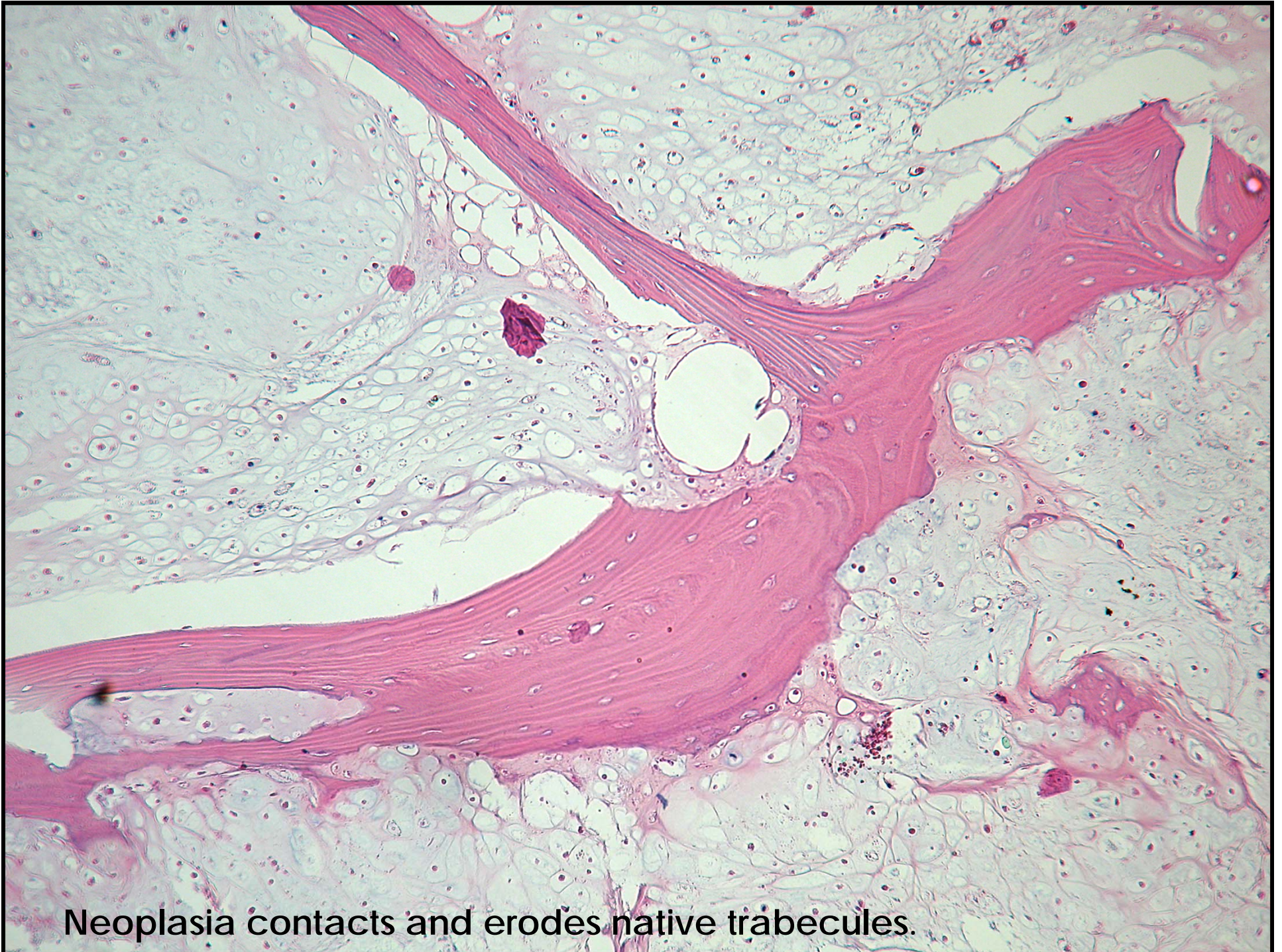


Permeation of marrow spaces.

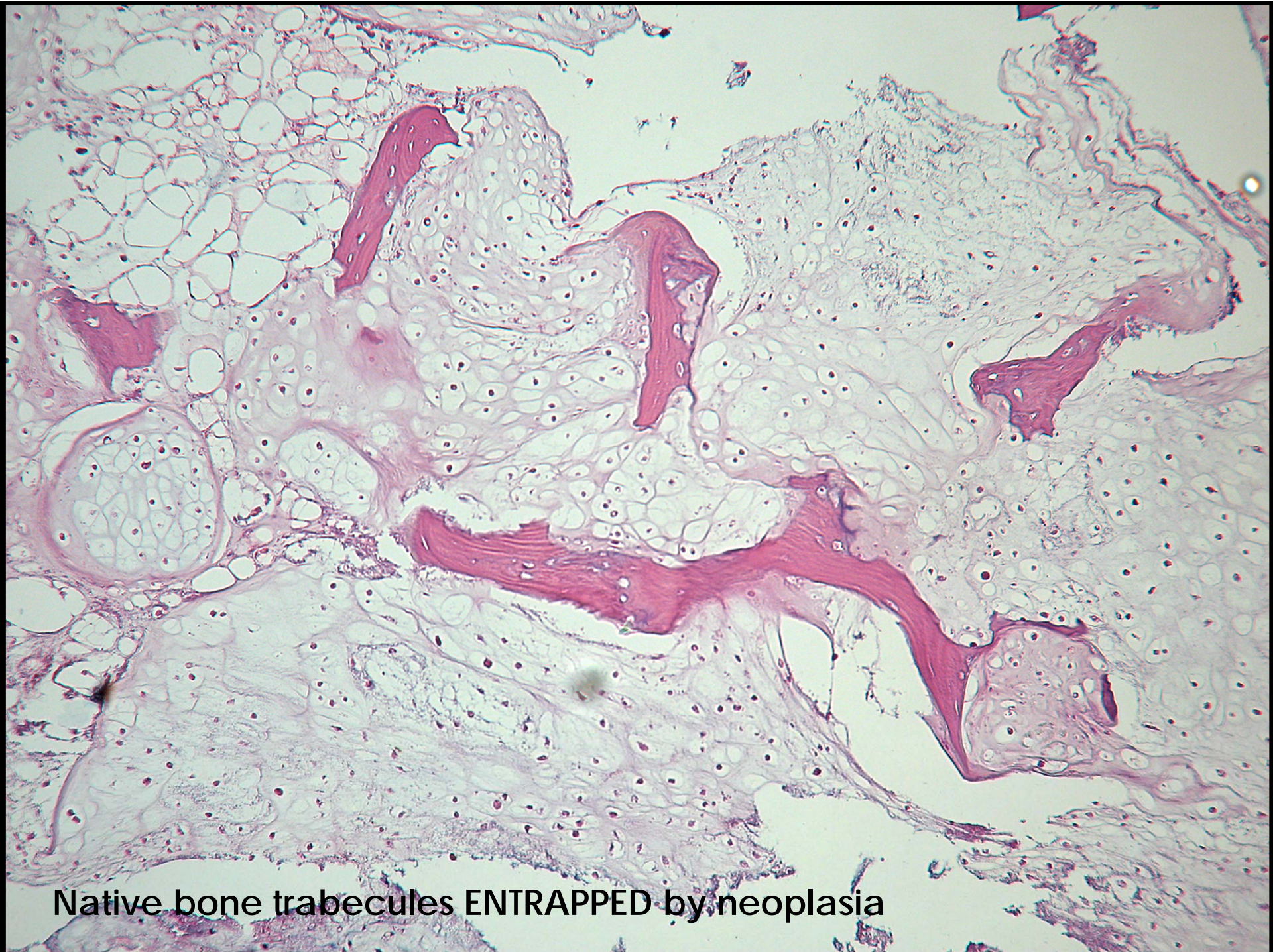
Permeation of medullary spaces





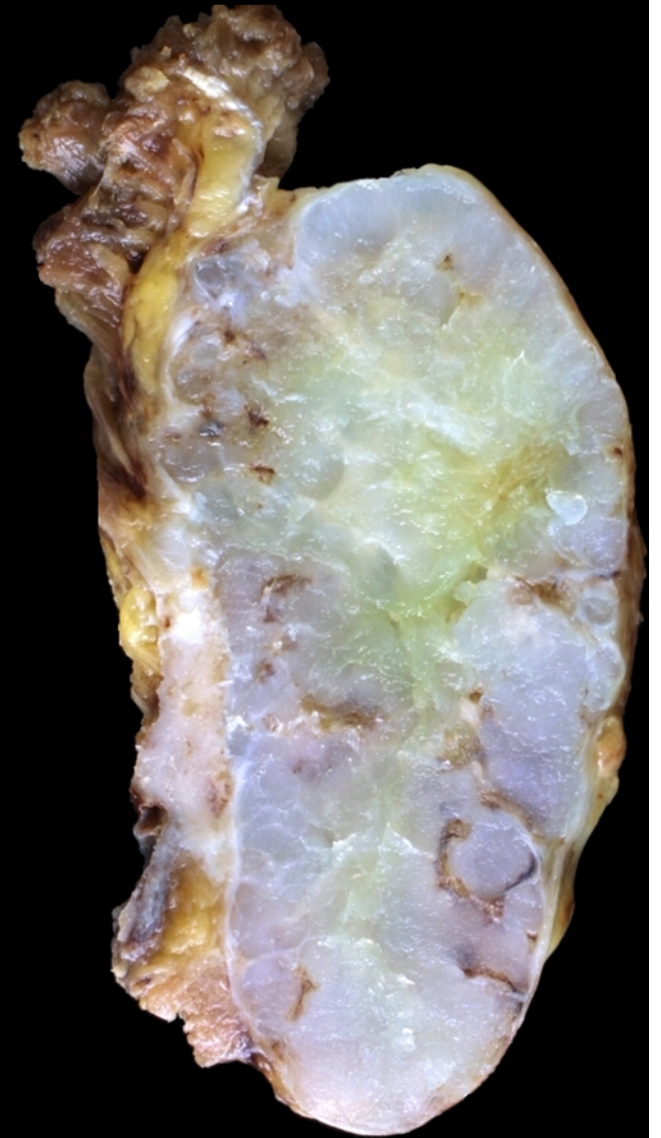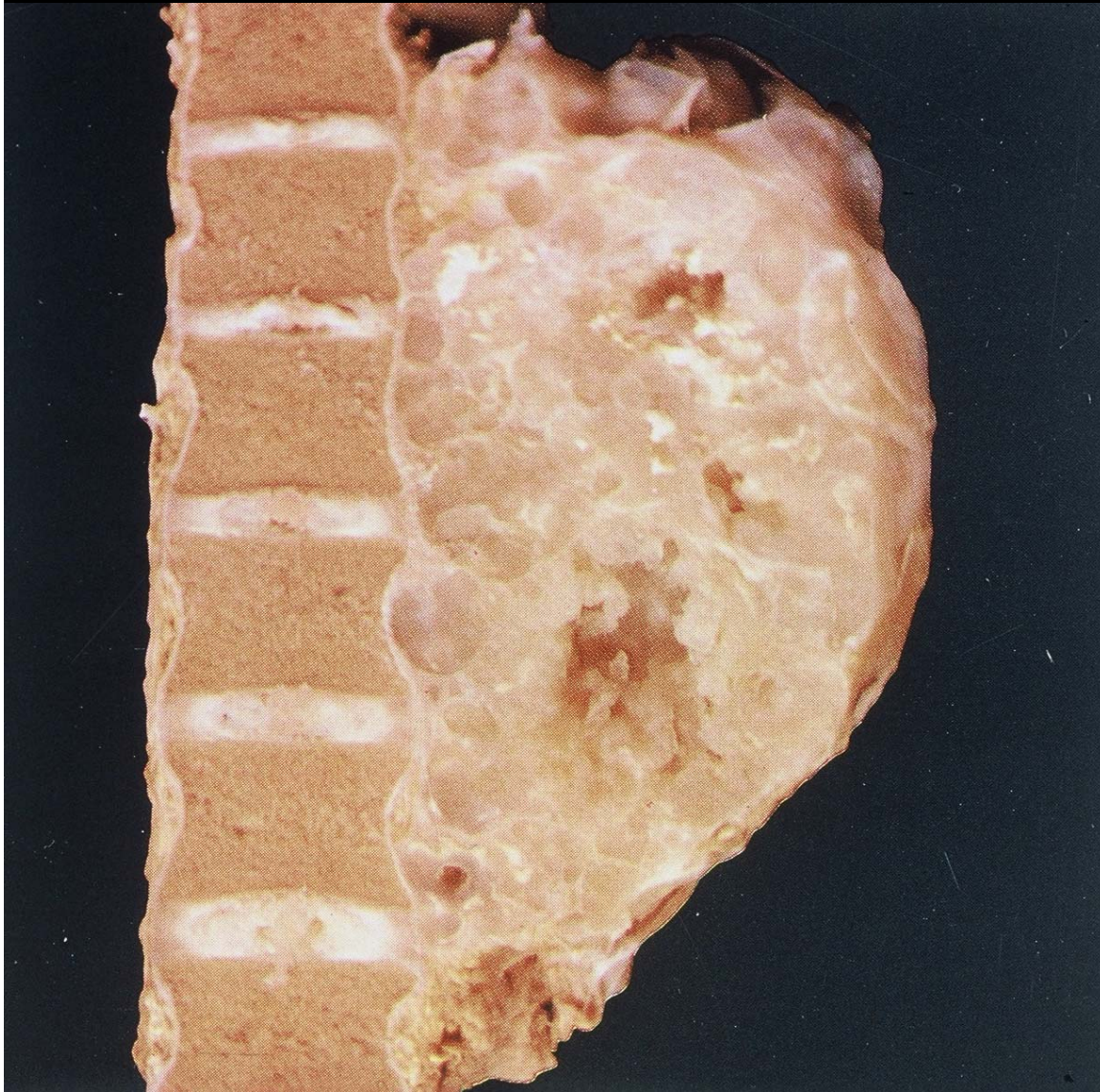


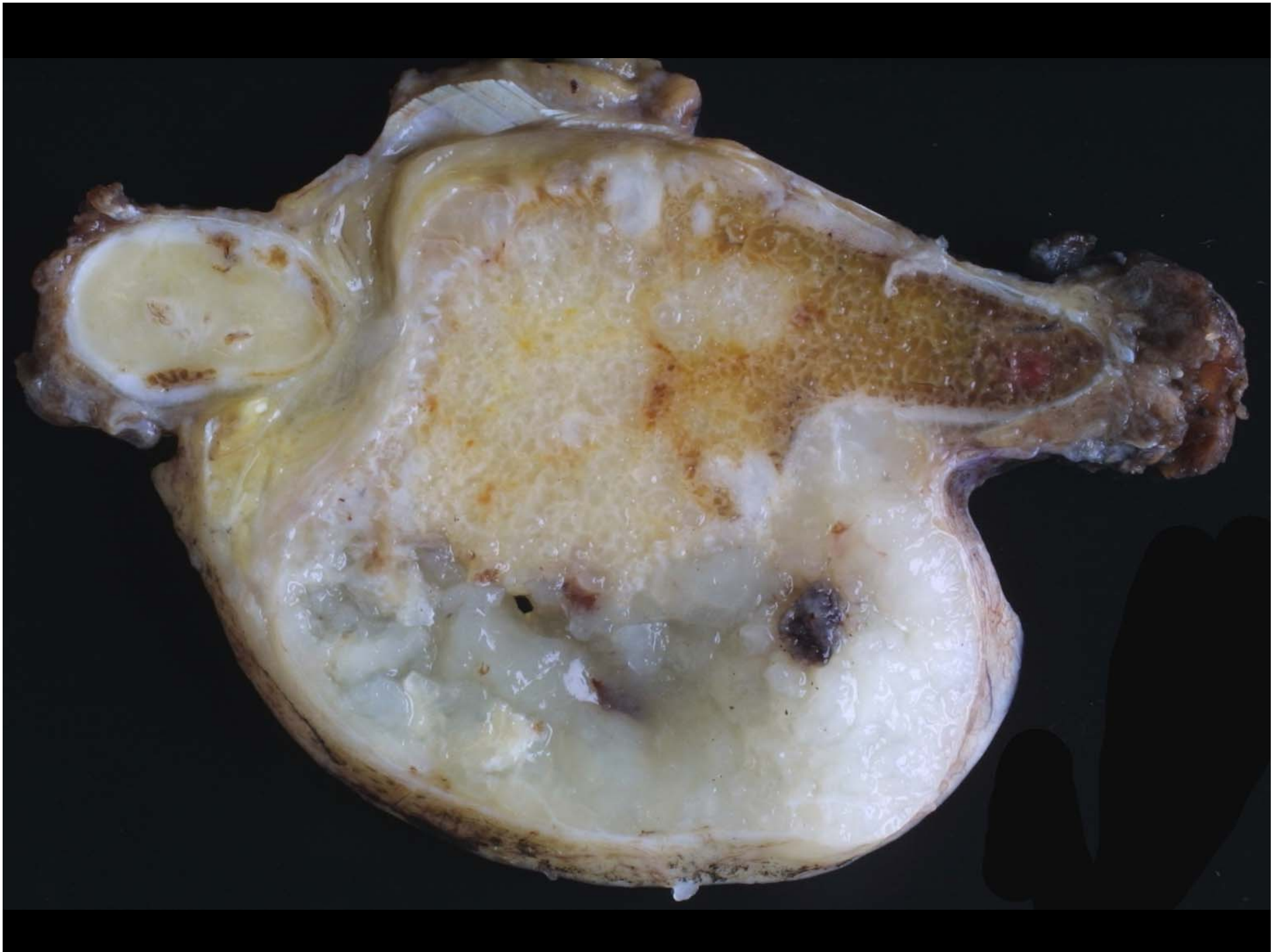
Neoplasia contacts and erodes native trabecules.



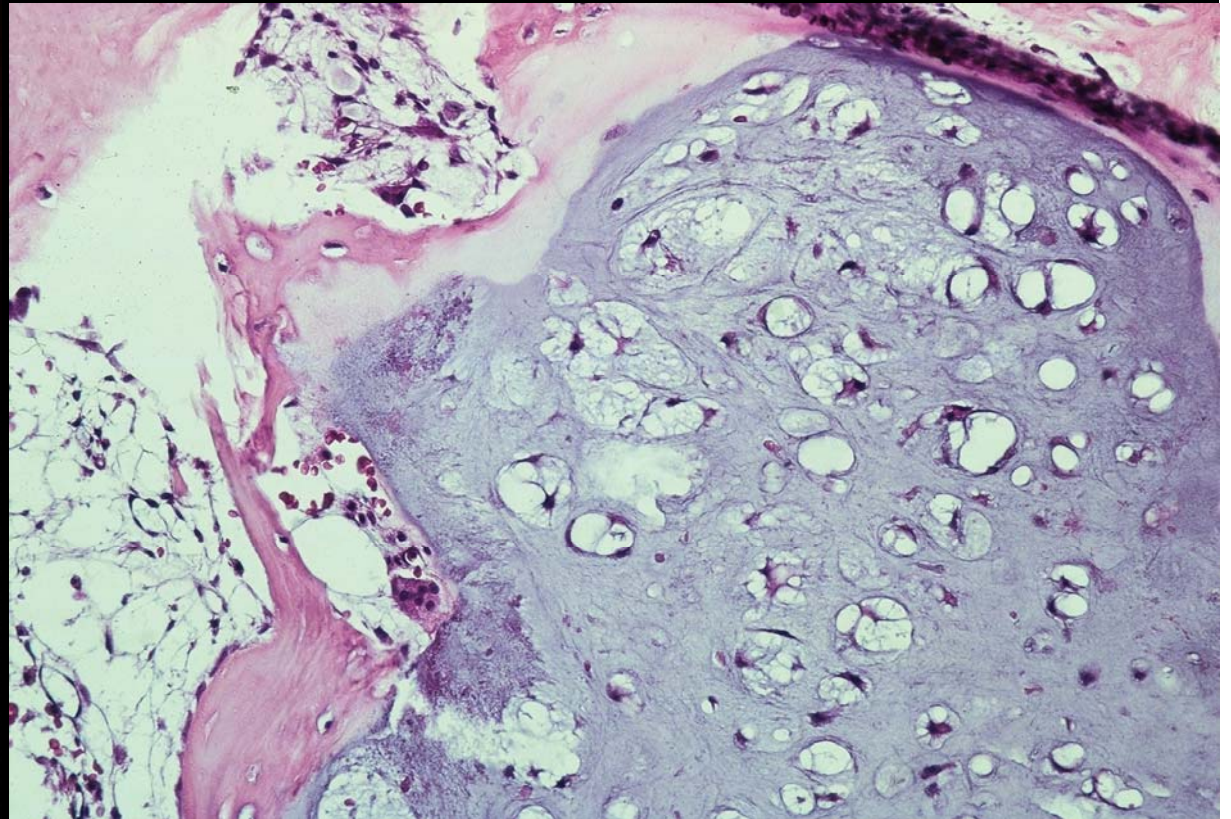
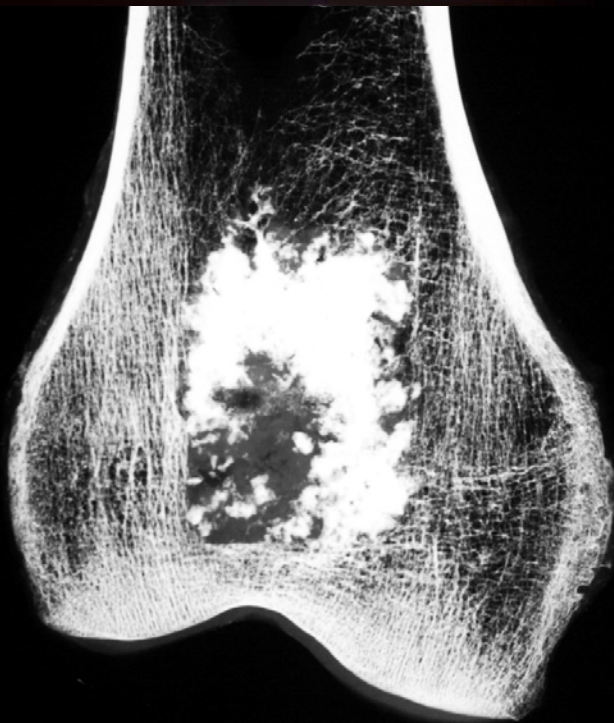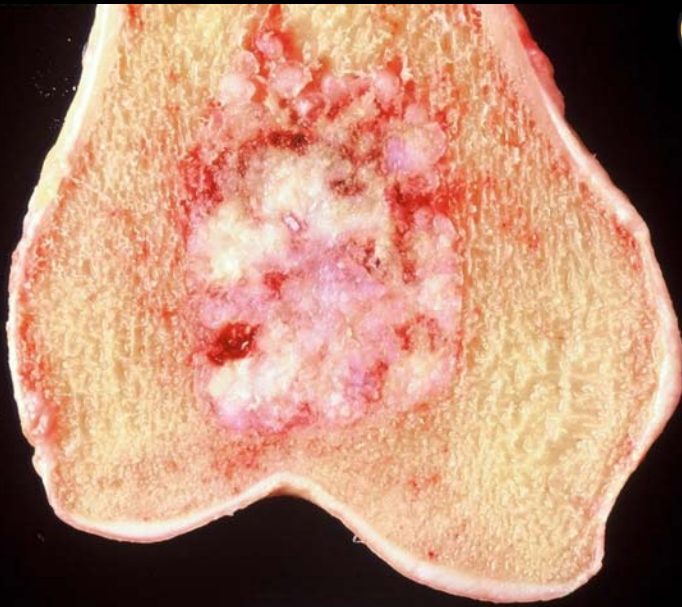
Native bone trabeculae ENTRAPPED by neoplasia

CHONDROSARCOMA GRADE 2 GROSS PATHOLOGY





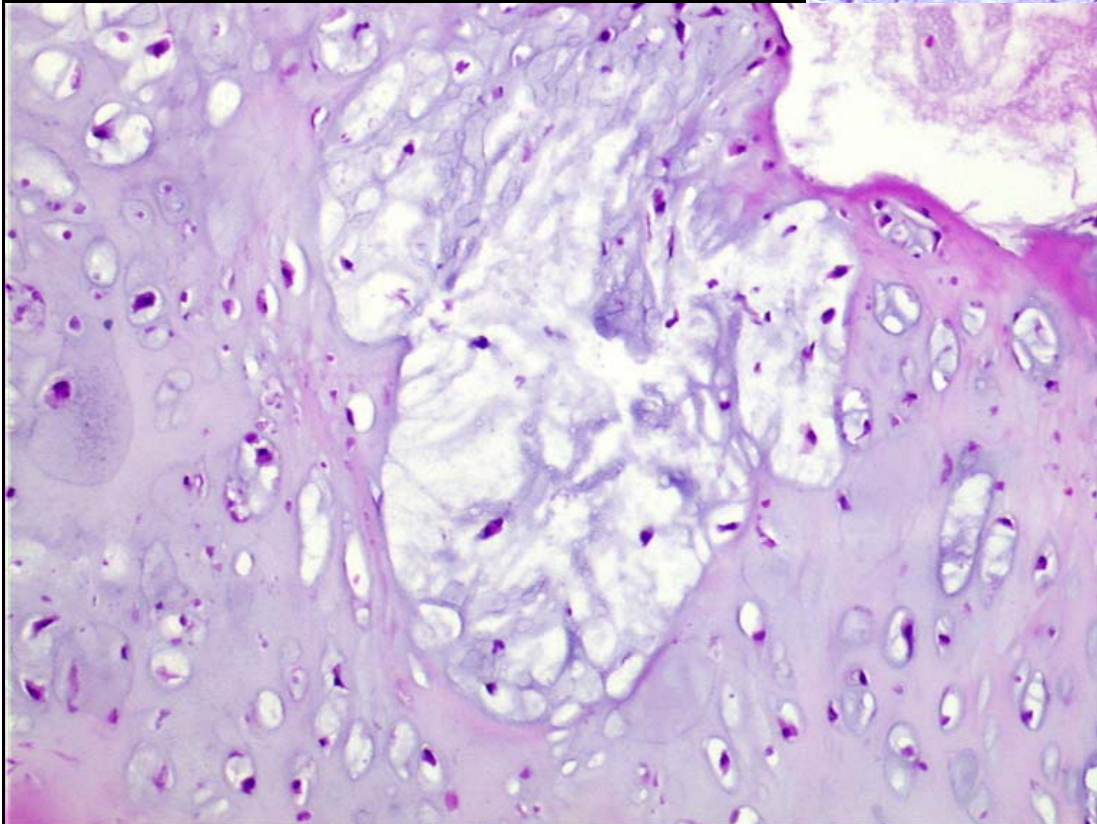
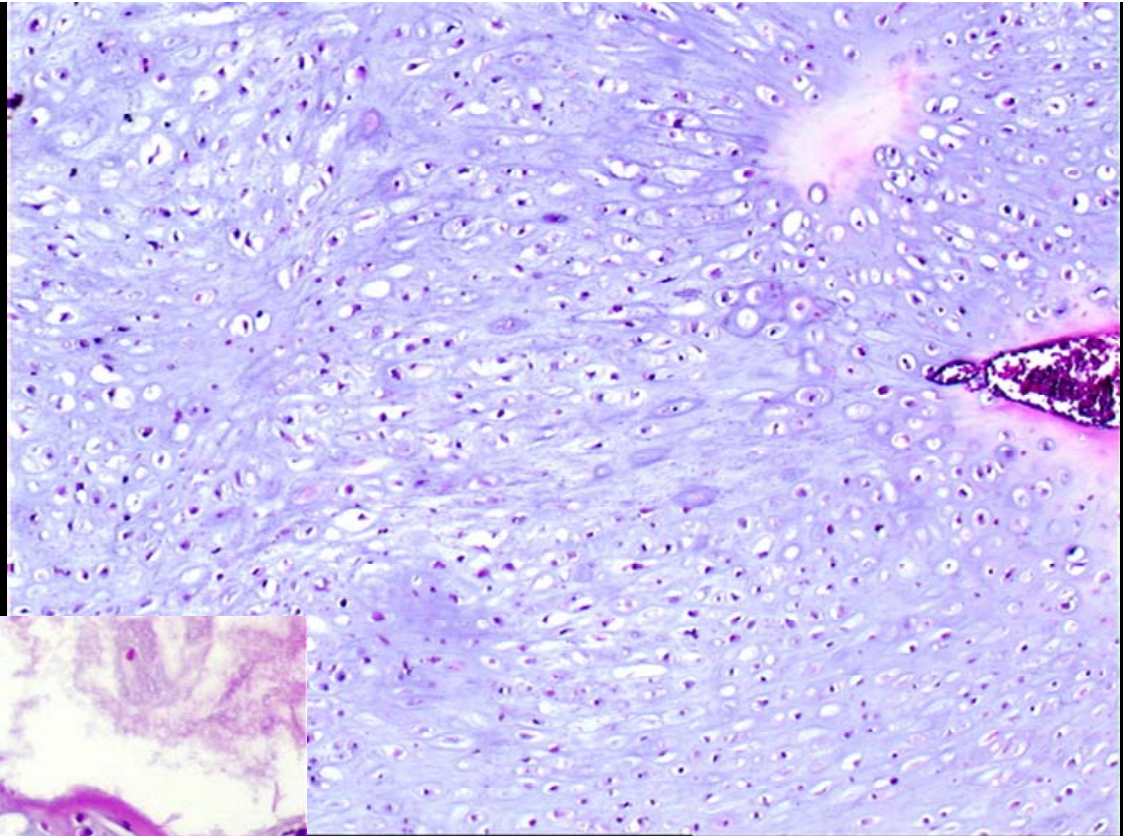
CHONDROSARCOMA 2



Higher cellularity
Lacunar pattern kept

CHS 2

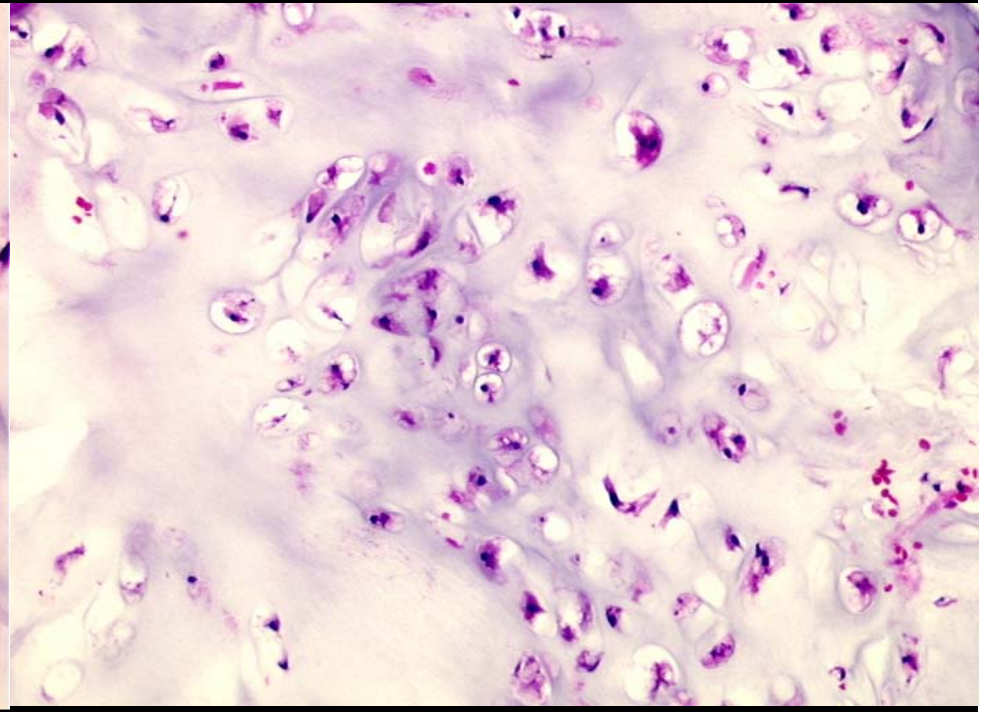
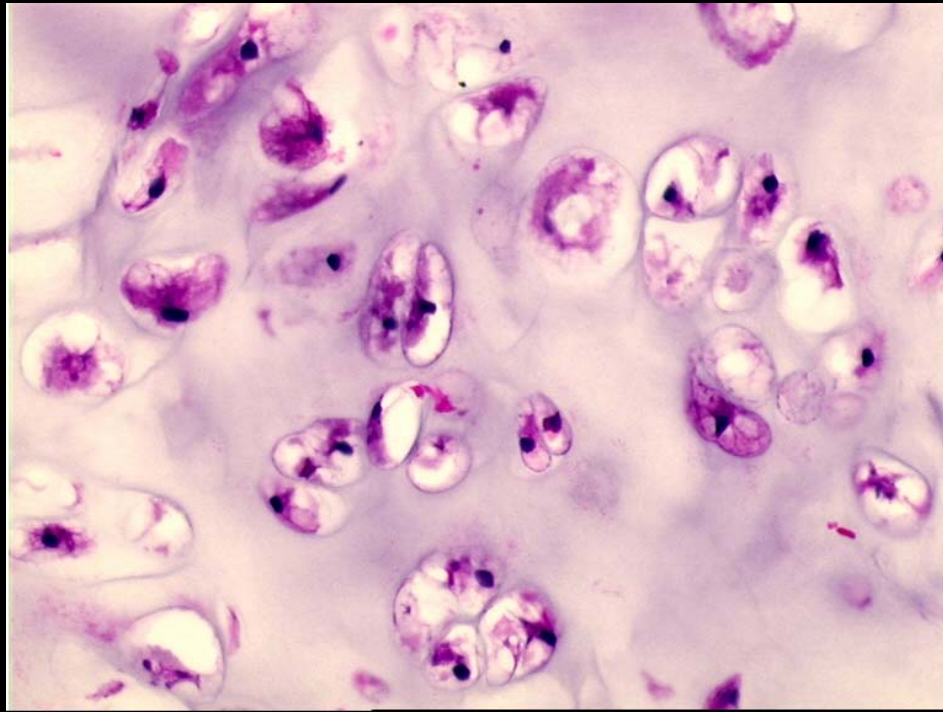
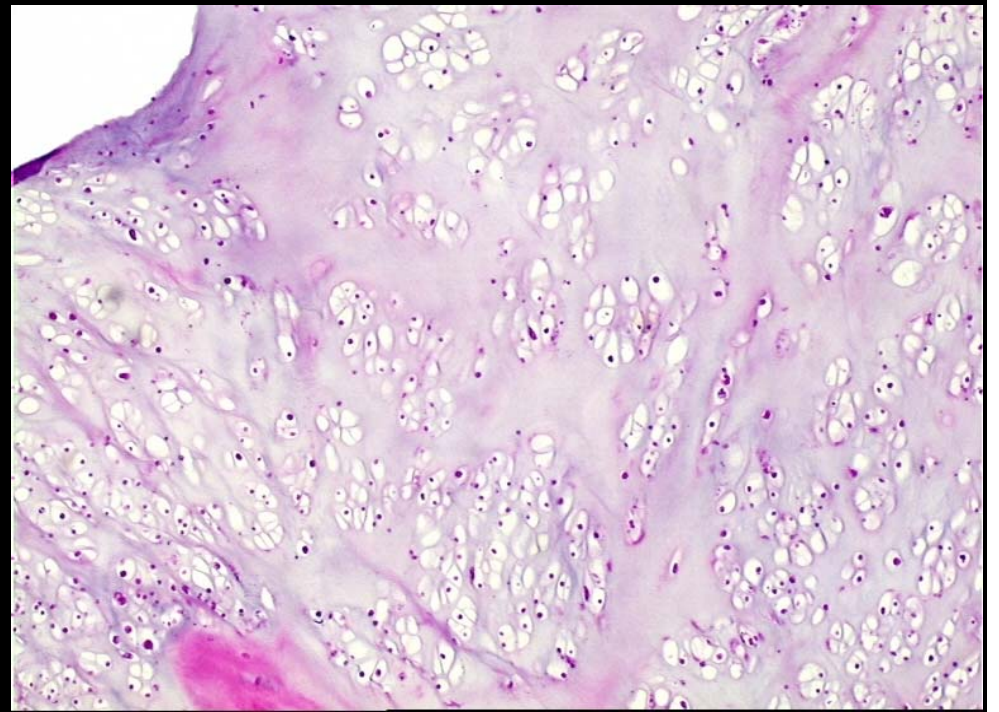
Higher cellularity
Lacunar pattern



Myxoid not usual

CHS 2

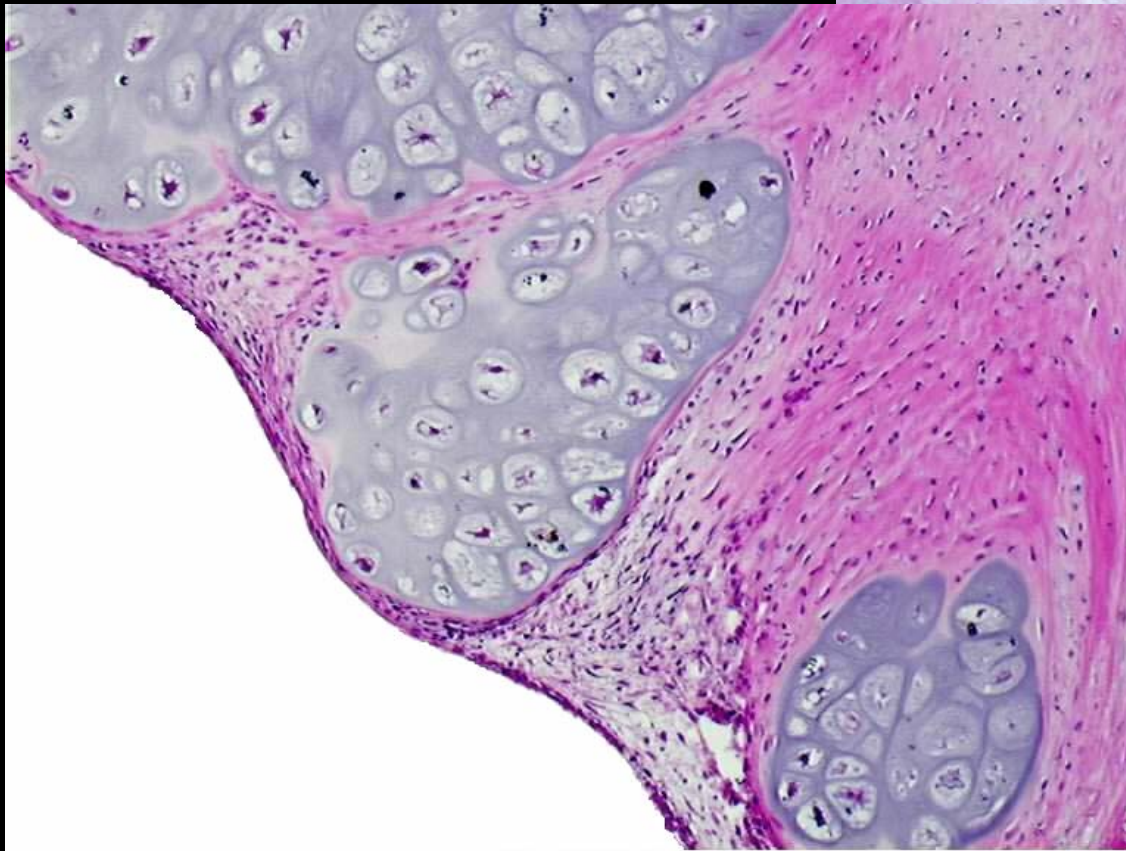
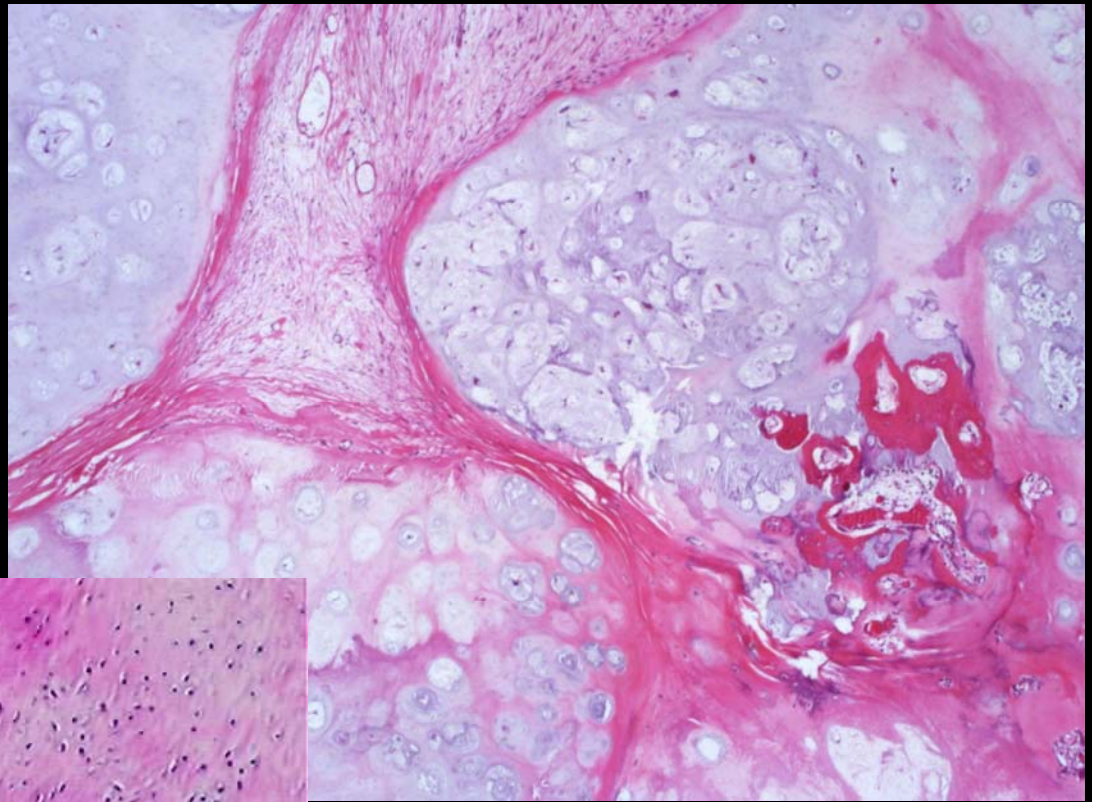
Nuclei of variable size
Abundant cytoplasm
No important atipias



CHS 2

Chondroid lobules of
variable sizes

Separated by fibrous tissue

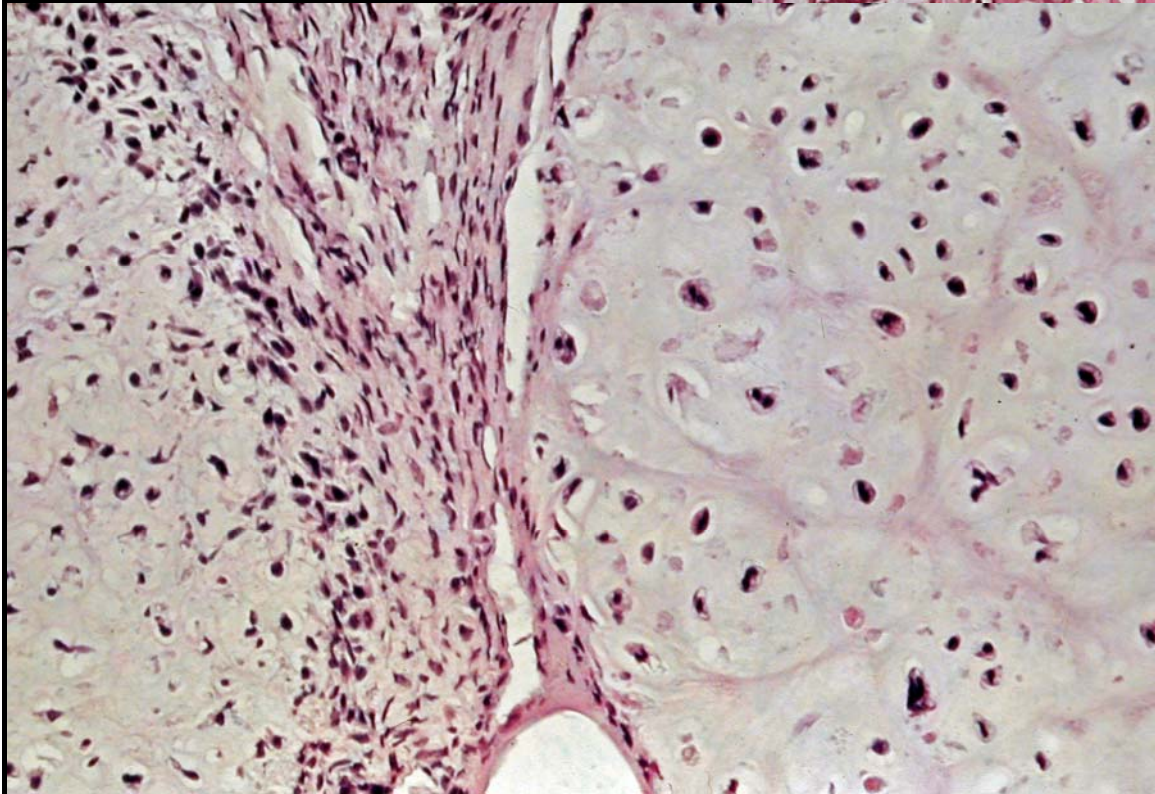
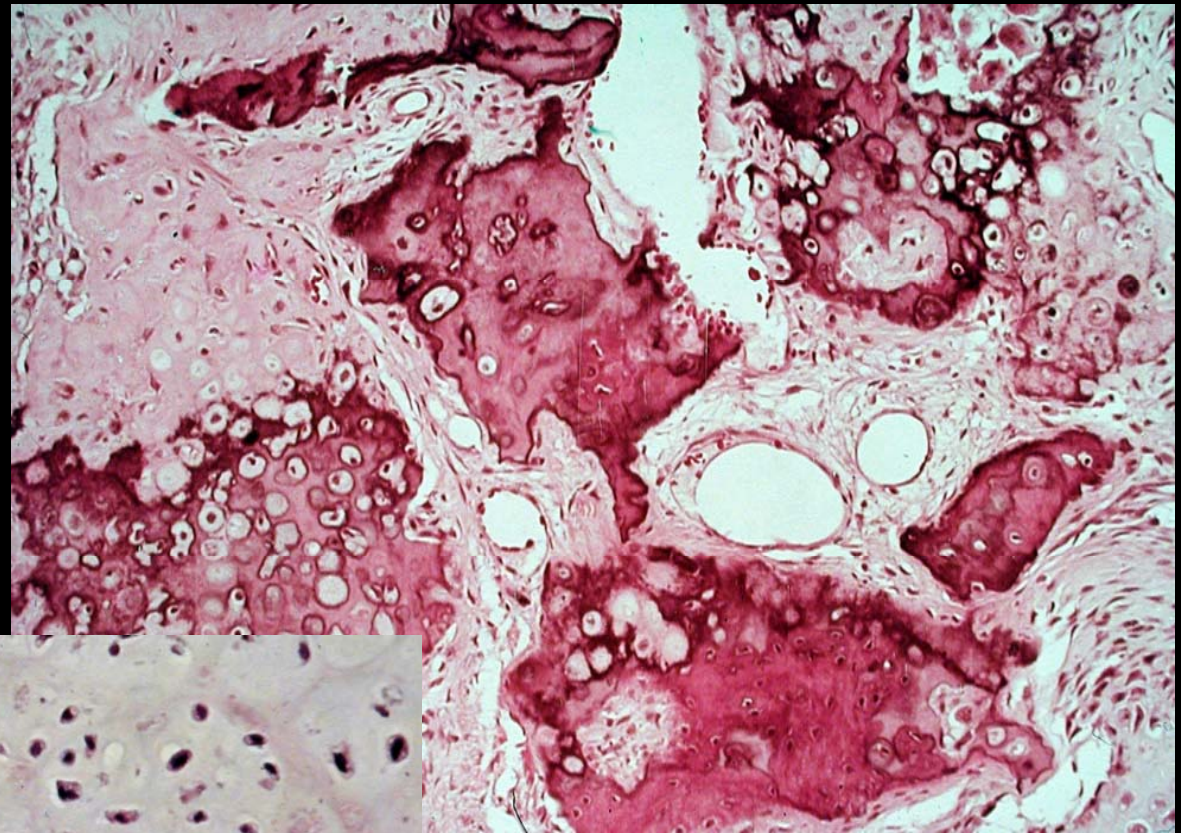


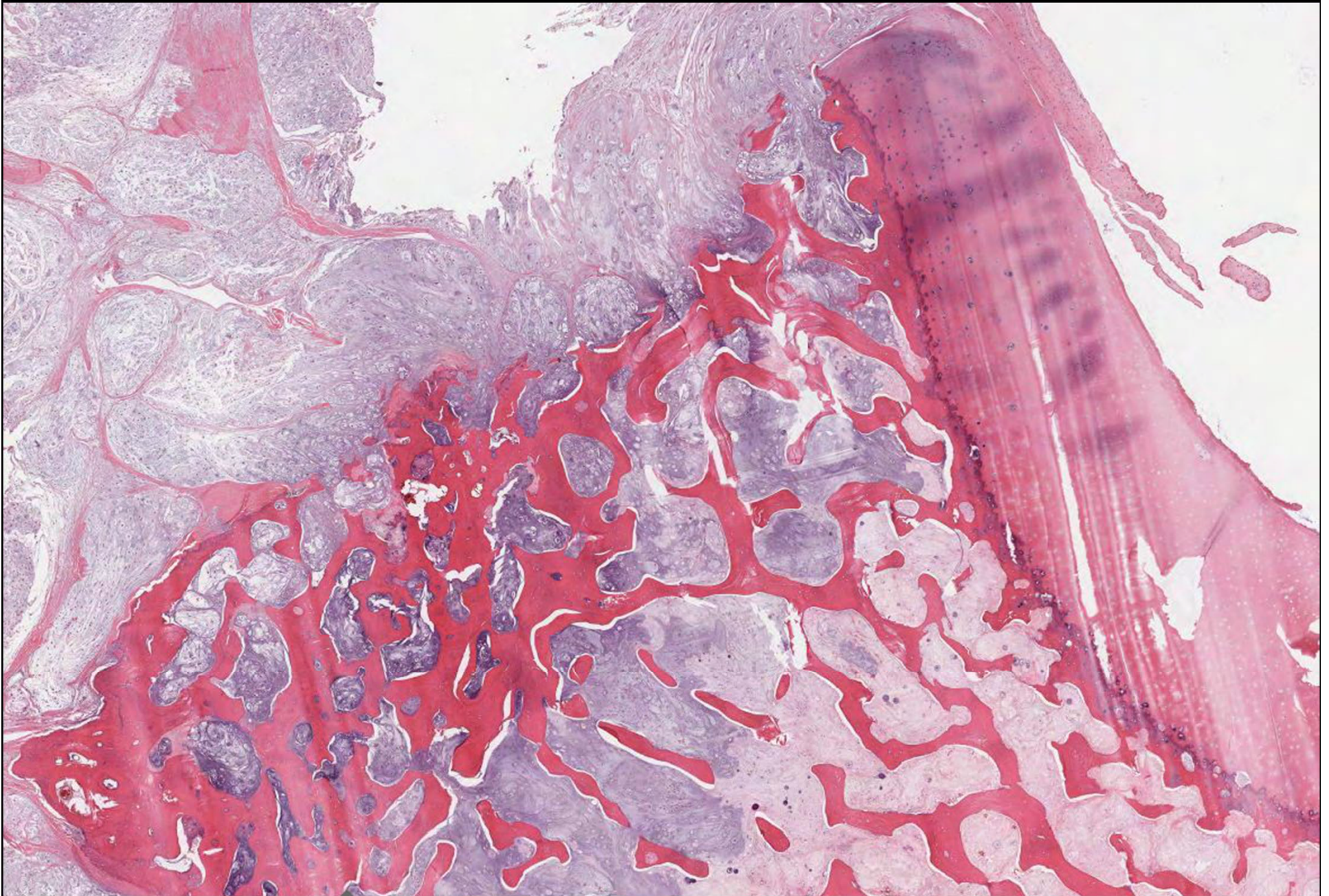
CHS 2

Matrix calcification

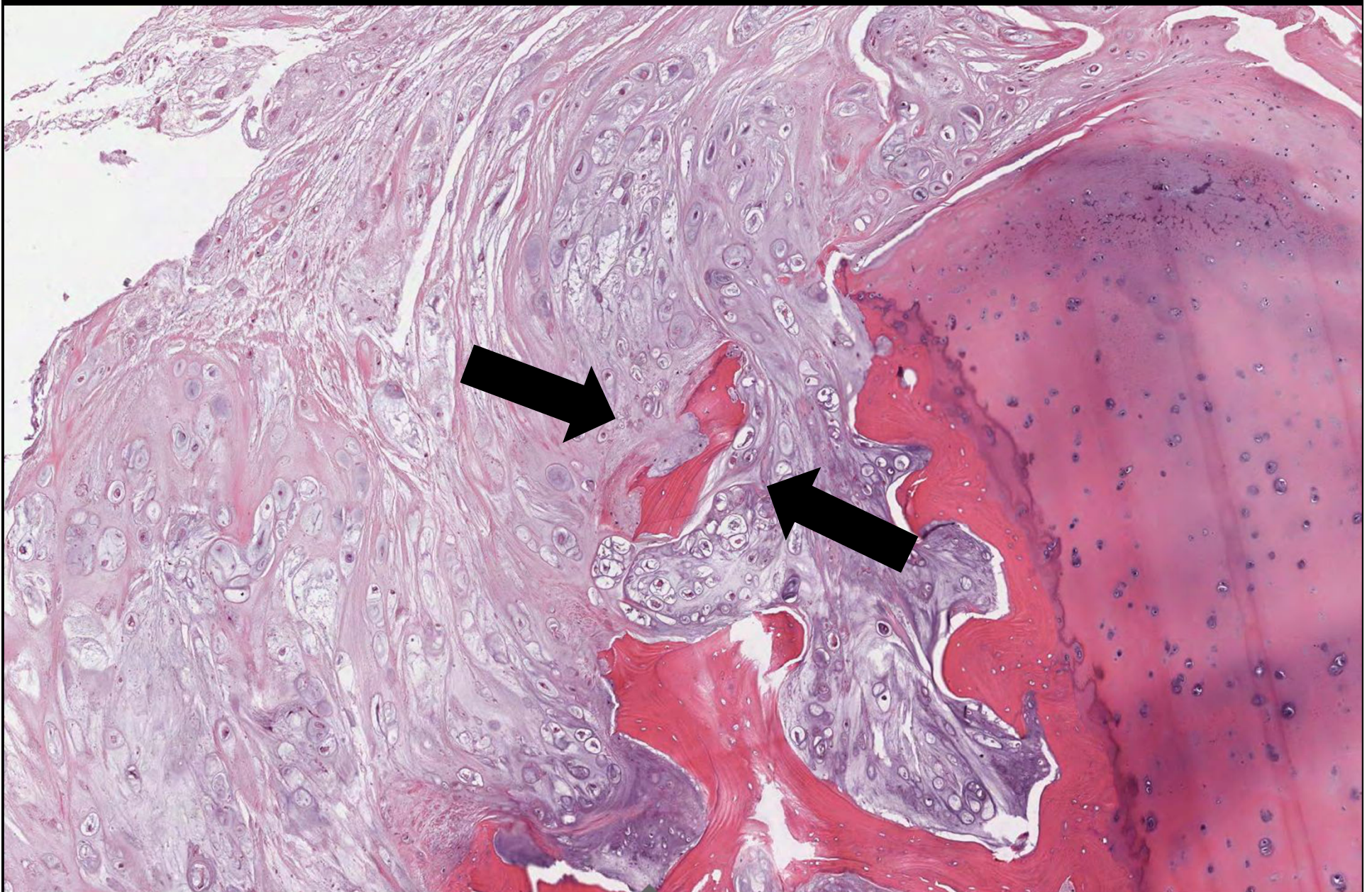
Fibrous bands separating
chondroid lobules.

More atypical nuclei

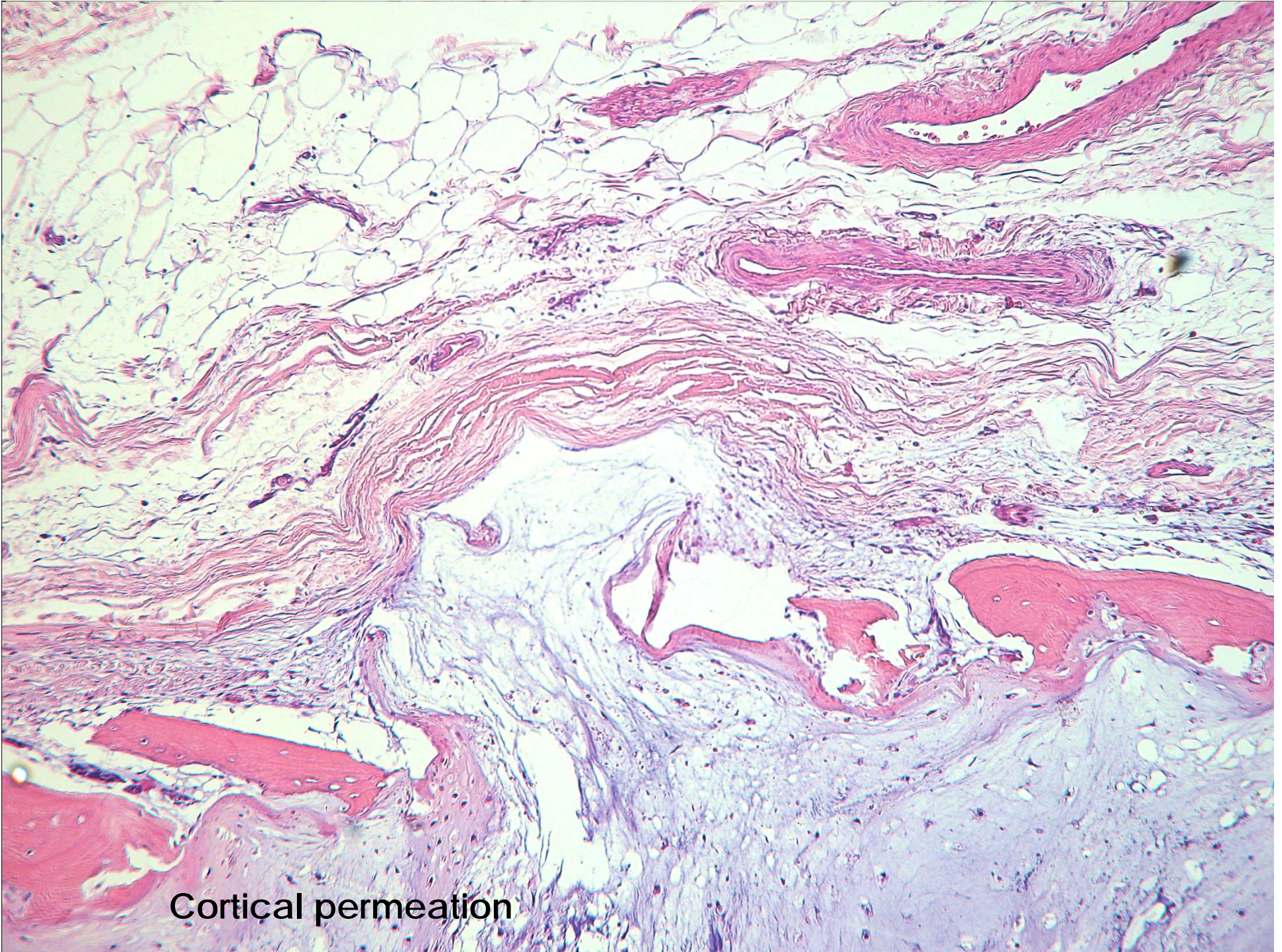




Permeation of marrow spaces

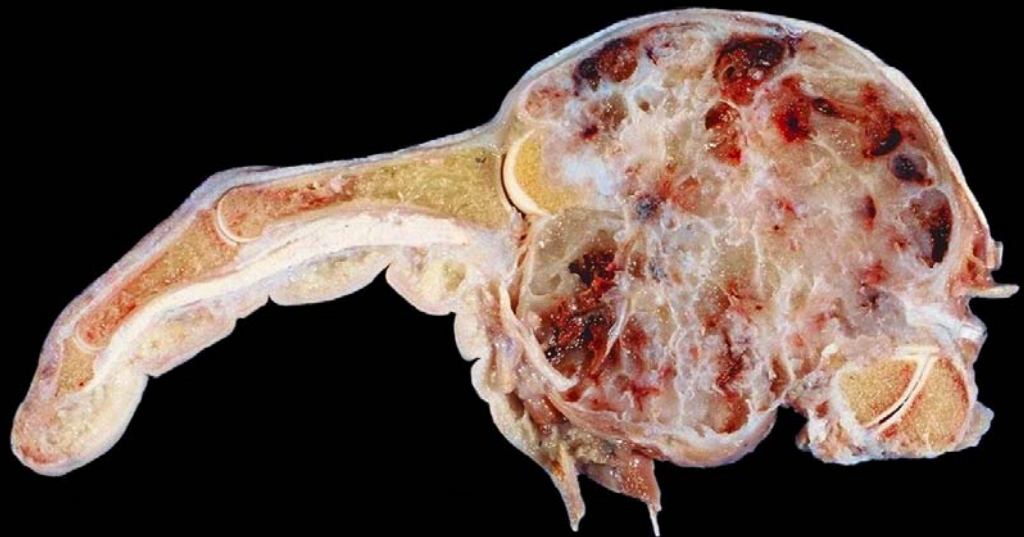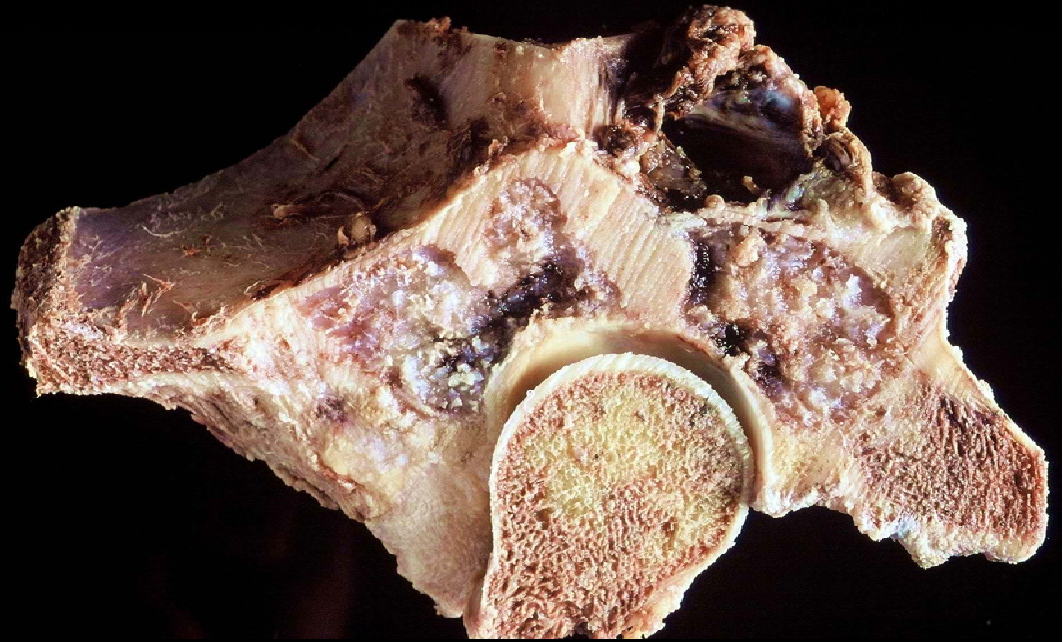

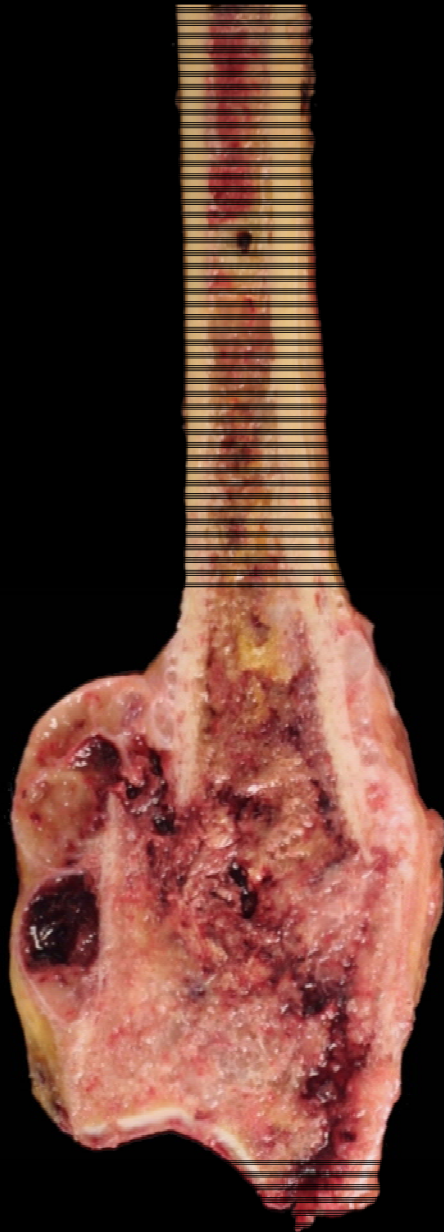
Entrapping of mature trabeculae fragments



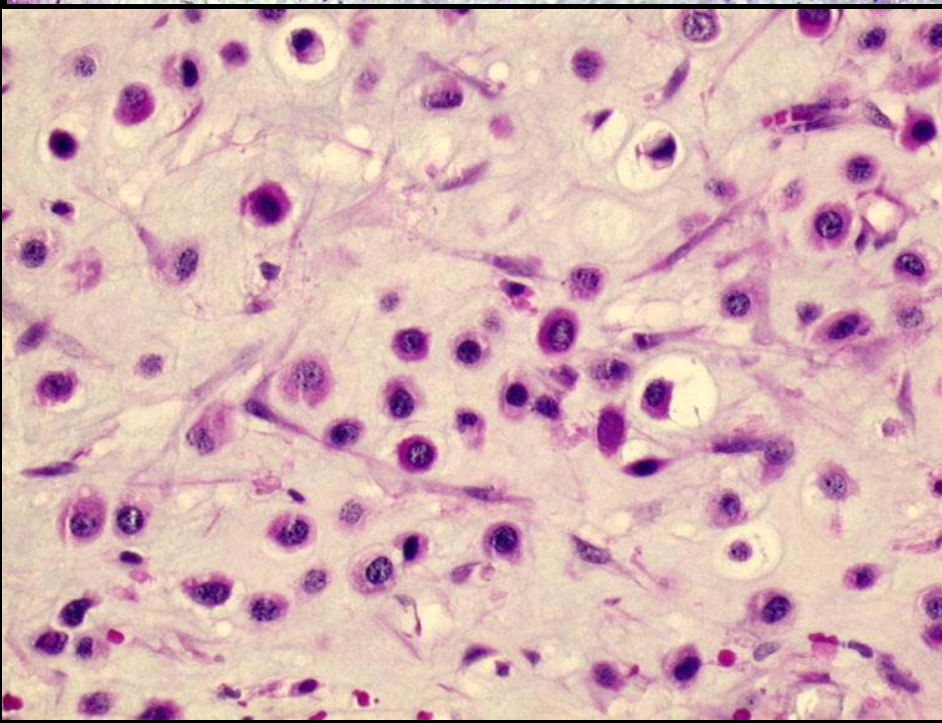
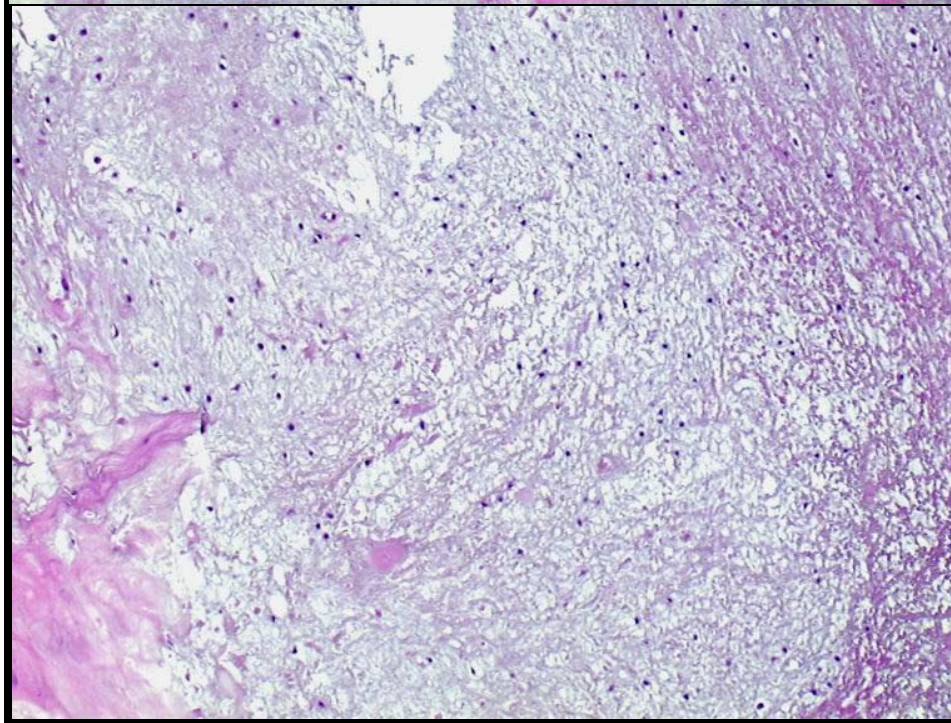
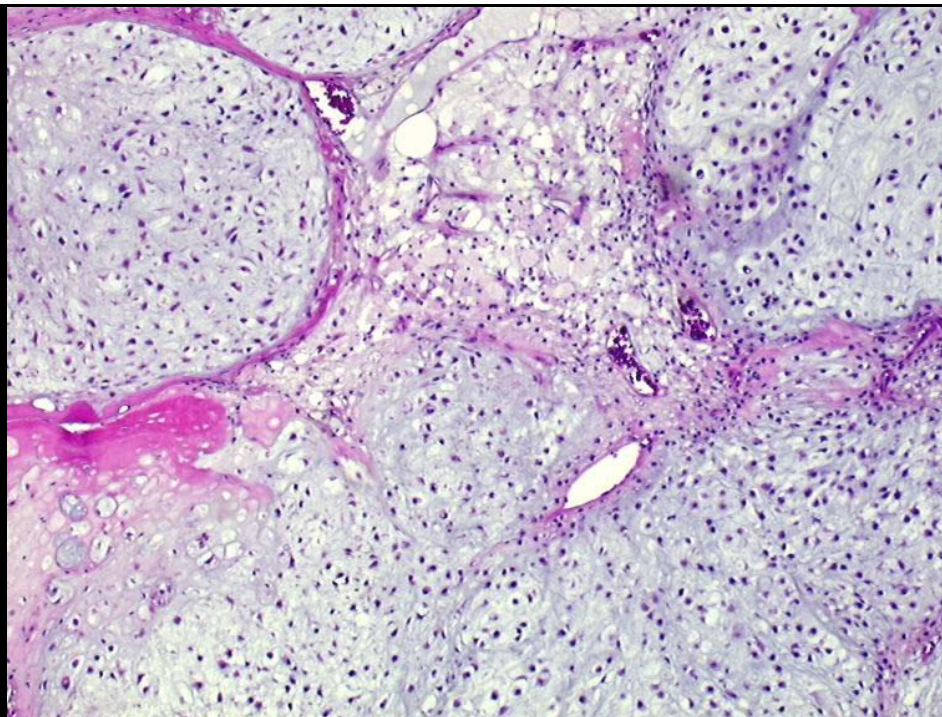
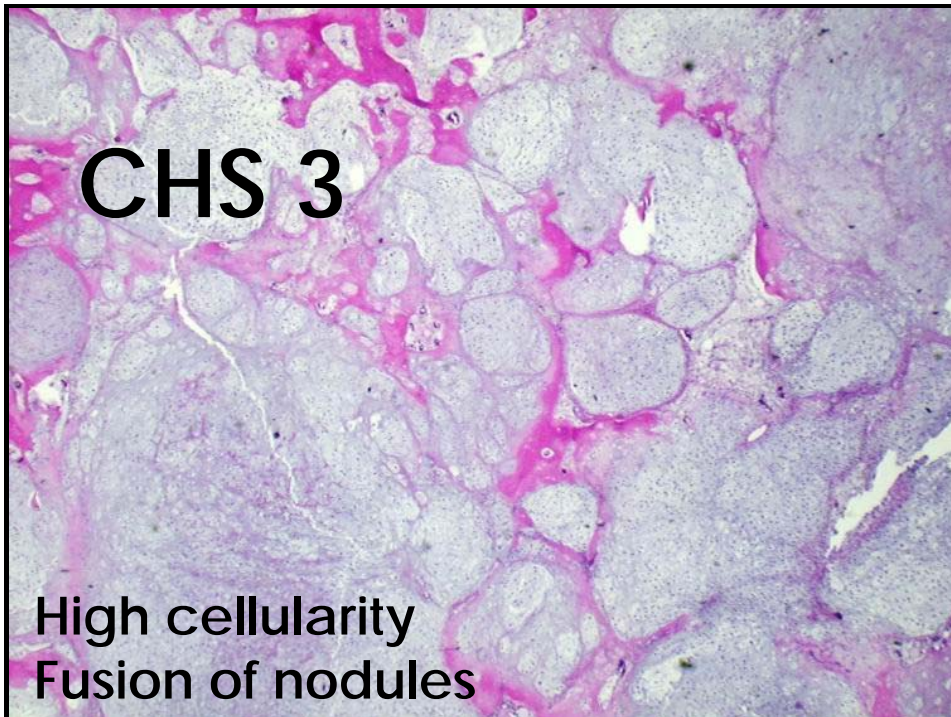
Cortical permeation

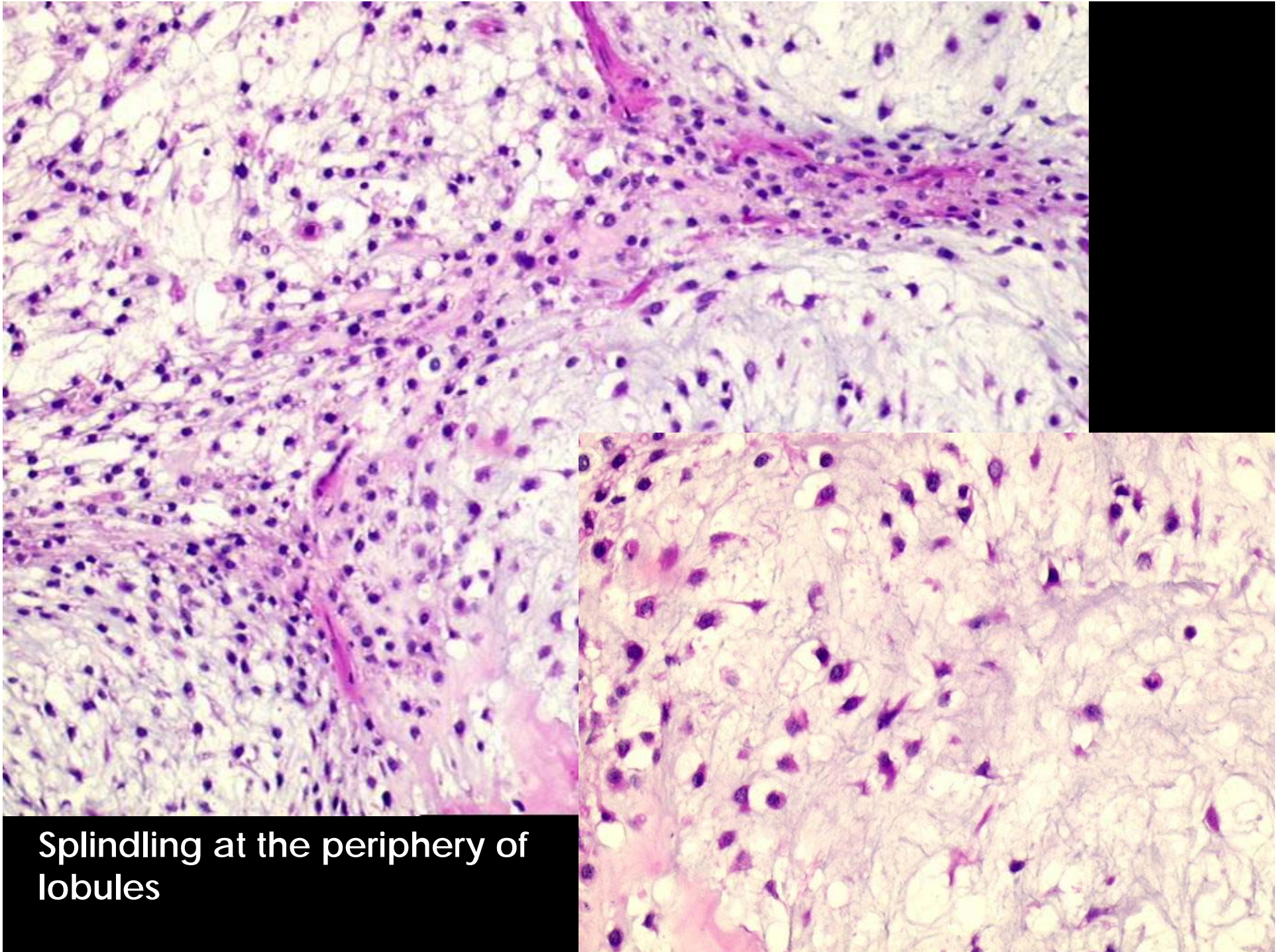CHONDROSARCOMA, GRADE 3



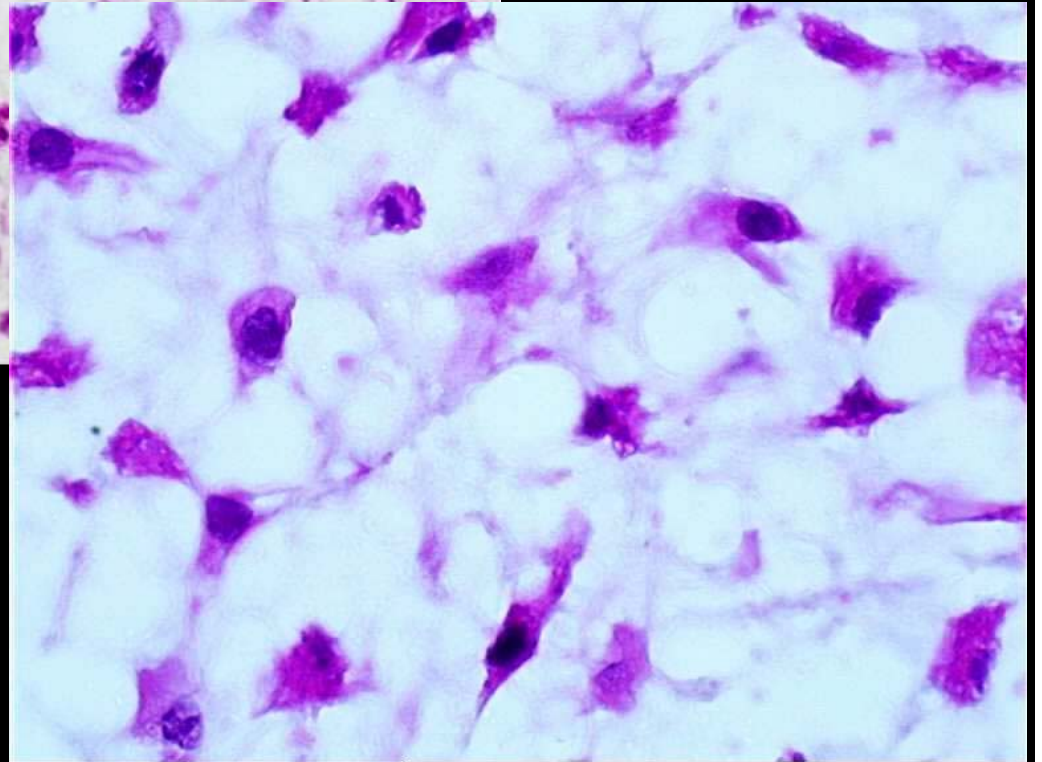
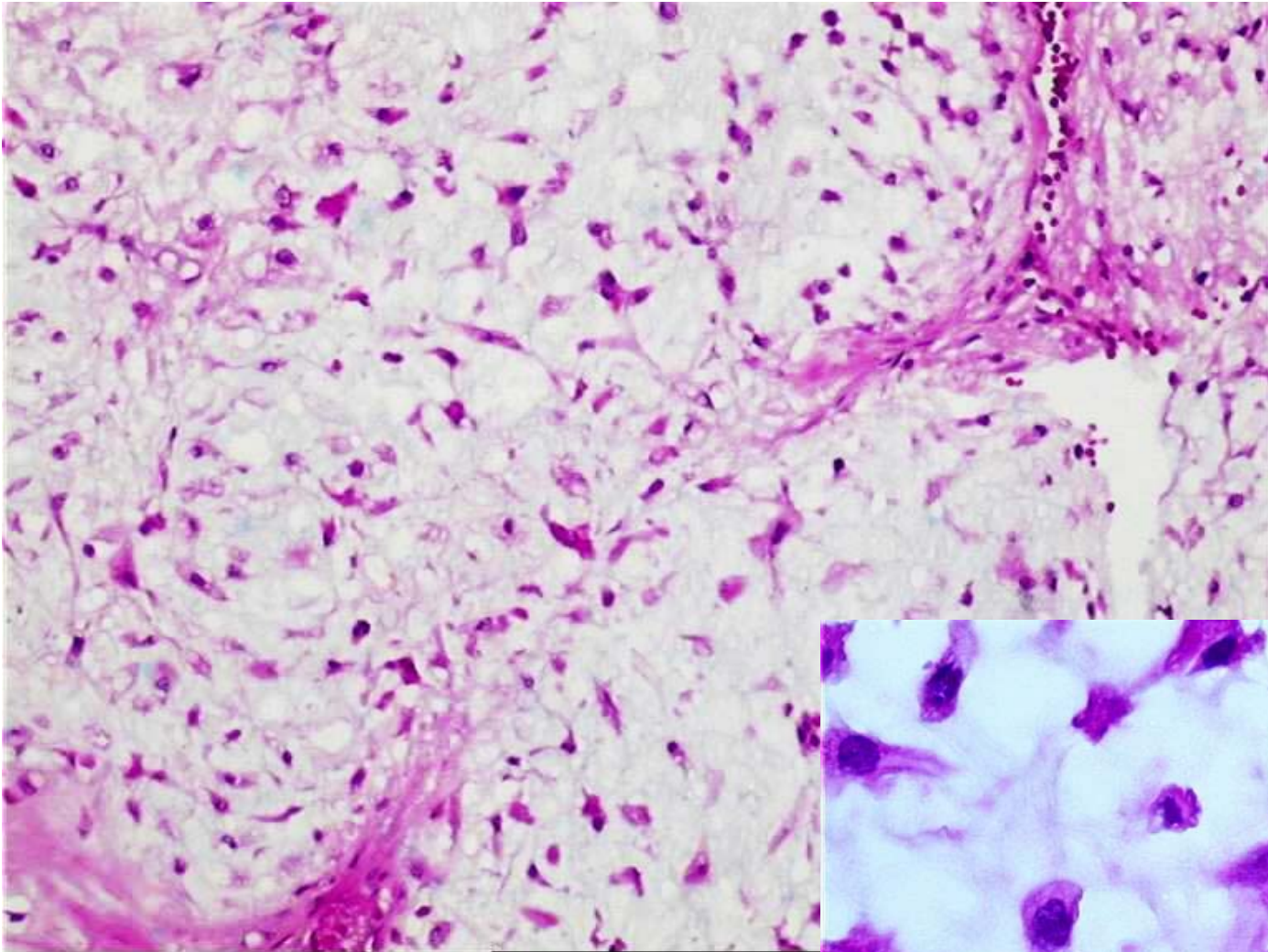
CHS 3

High cellularity
Fusion of nodules

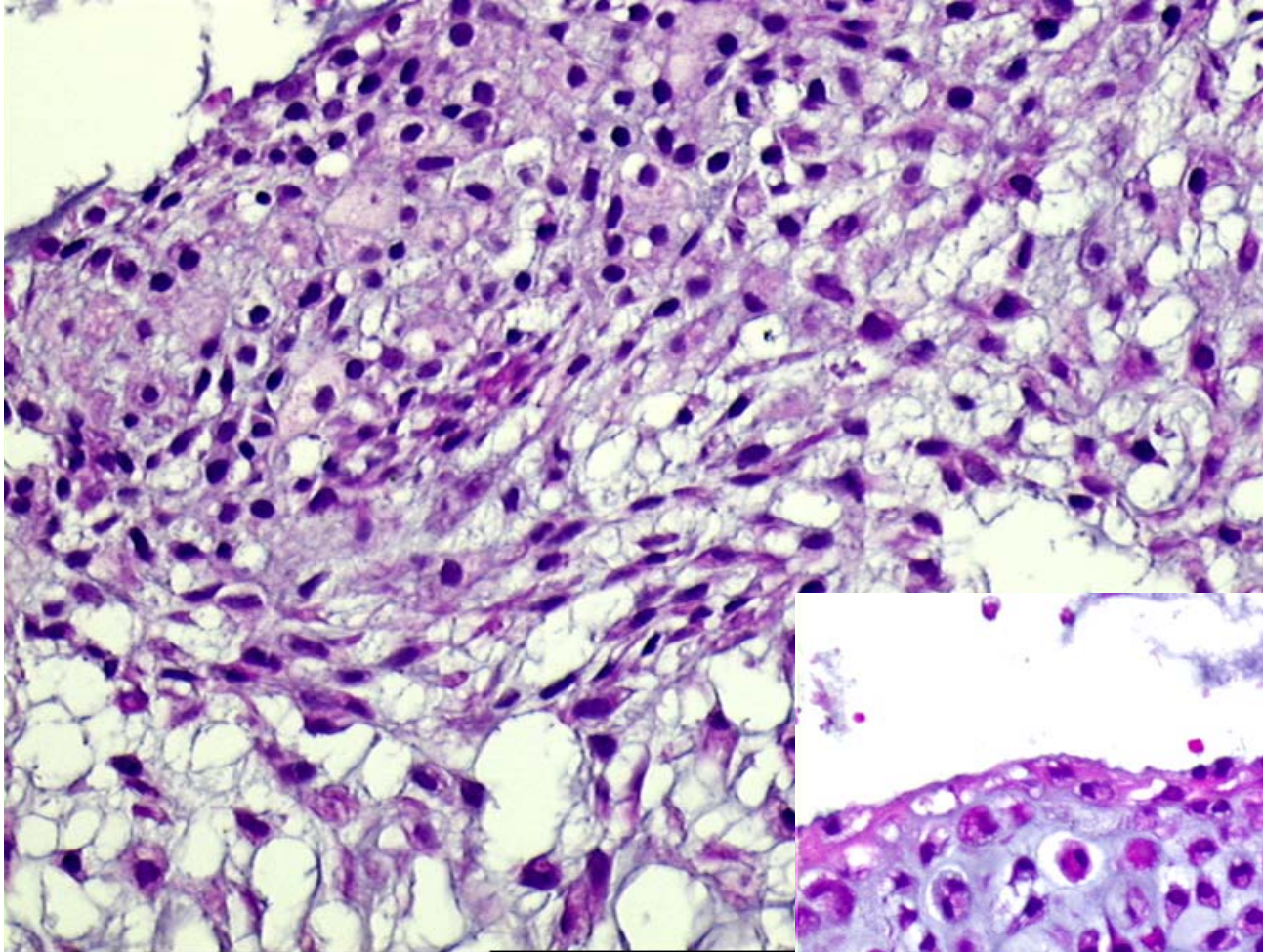




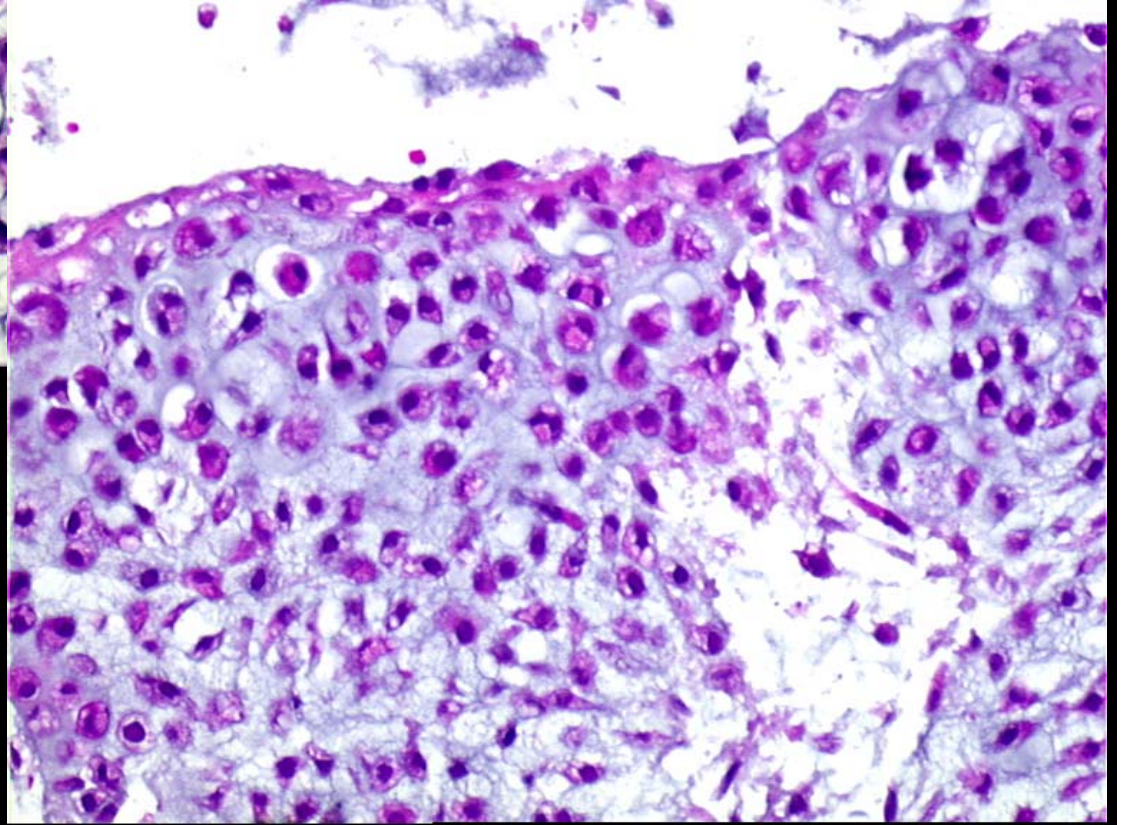
Splindling at the periphery of lobules

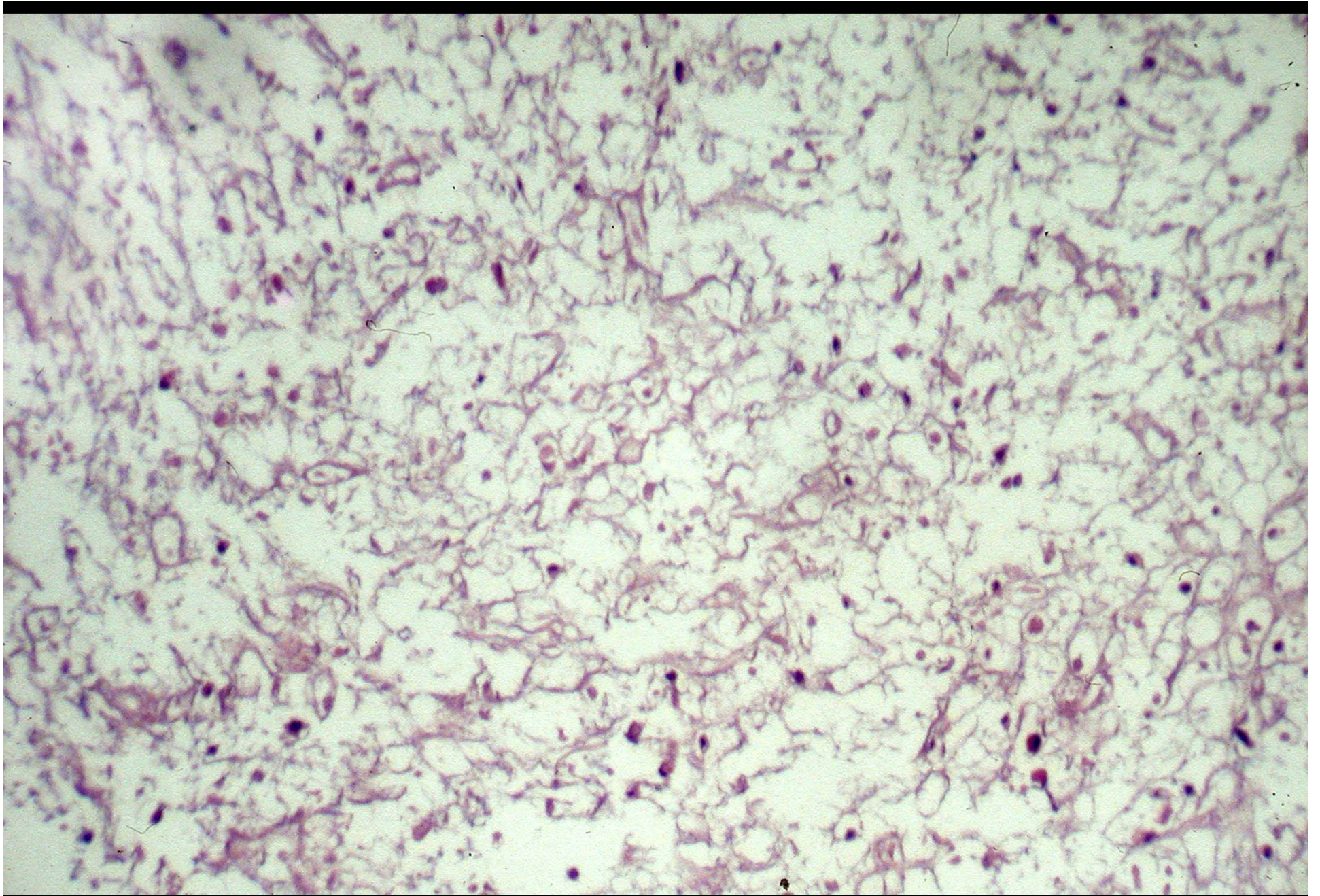


Loss of lacunar pattern
Nuclear atypia



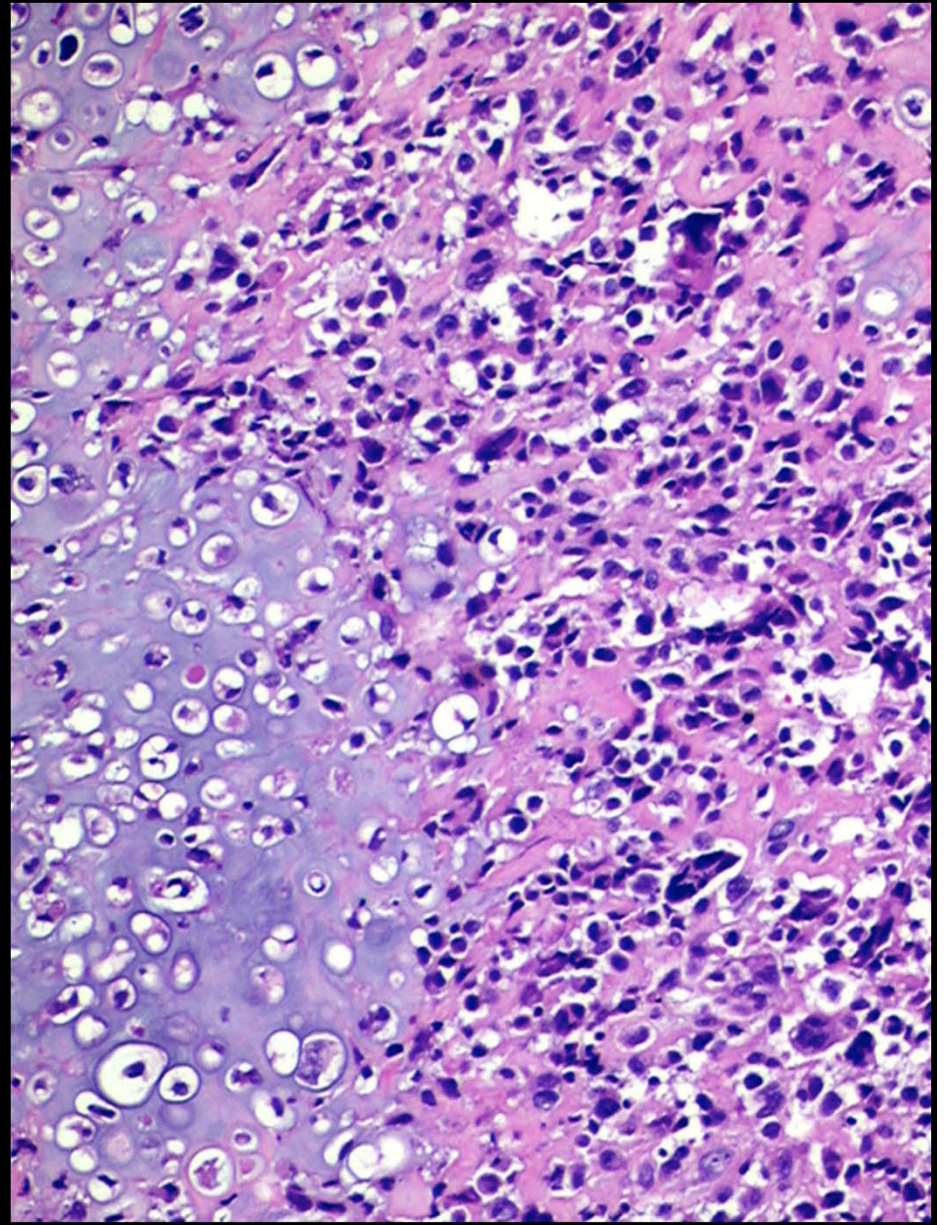
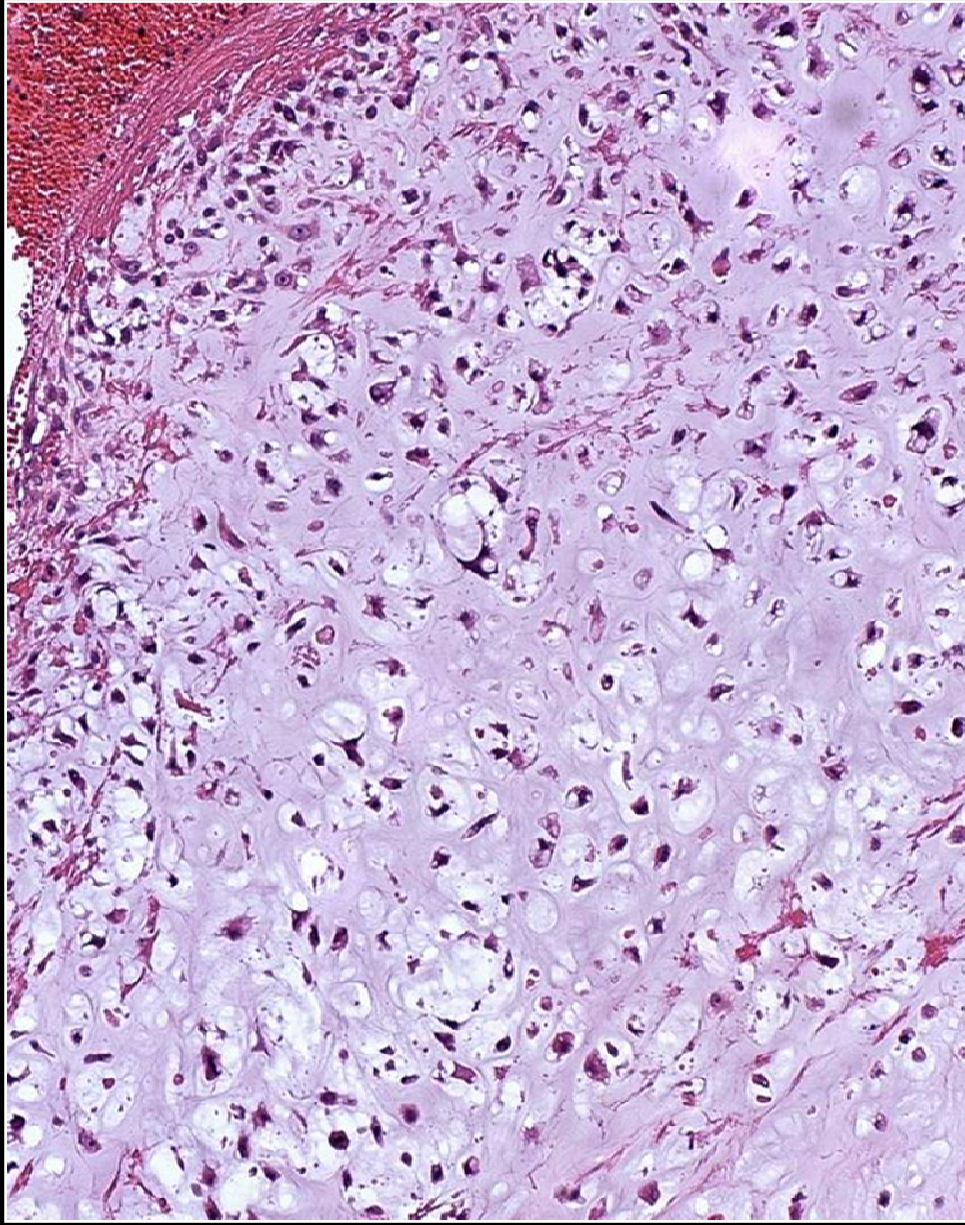
Neoplastic myxoid
=>2 mitosis / 10 HPF

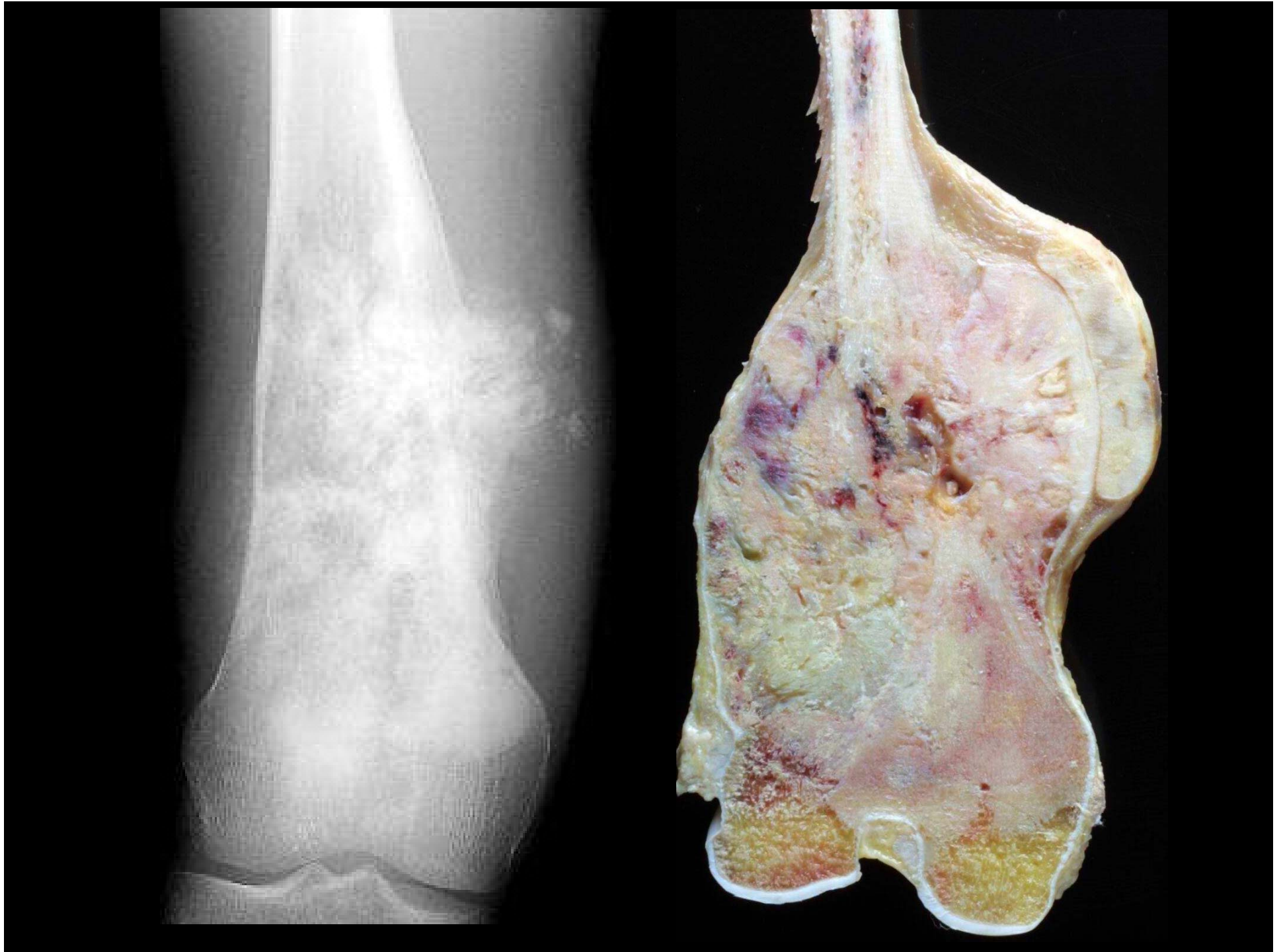




Degenerative myxoid

**Very important atypias, frequent mitoses:
DD CHONDROBLASTIC OSTEOSARCOMA**





ANCILLARY TECHNIQUES

IMMUNOHISTOCHEMISTRY

S100, SOX9 +

GENETICS

AMARY MF ET AL.

IDH1 AND IDH2 MUTATIONS ARE FREQUENT EVENTS IN CENTRAL CHONDROSARCOMA AND CENTRAL AND PERIOSTEAL CHONDROMAS BUT NOT IN OTHER MESENCHYMAL TUMOURS.

J PATHOL. 2011 JUL;224(3):334-43.



ELSEVIER

Contents lists available at ScienceDirect

Pathology - Research and Practice

journal homepage: www.elsevier.com



The utility of SATB2 immunohistochemical expression in distinguishing between osteosarcomas and their malignant bone tumor mimickers, such as Ewing sarcomas and chondrosarcomas

Isidro Machado ^{a,*}, Samuel Navarro ^b, Piero Picci ^c, Antonio Llombart-Bosch ^b



Results

SATB2 immunohistochemical expression in bone tumors

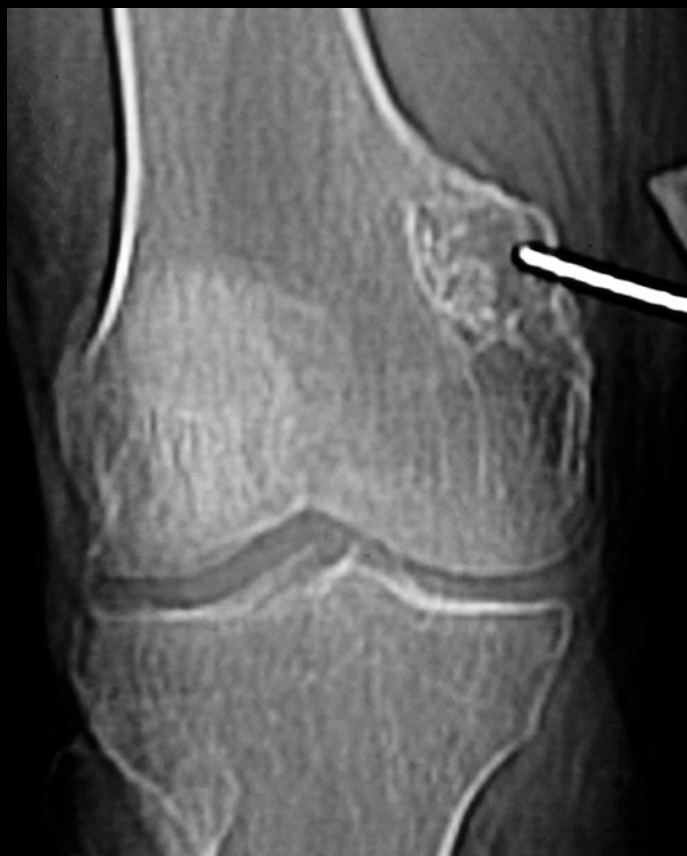SATB2	Total	Positives	Negatives
Ewing sarcoma	371	5 (1.3%)	366 (98.7%)
Osteosarcomas	42	38 (90.4%)	4 (9.6%)
Chondrosarcomas	30	14 (46.6%)	16 (43.4%)
Total	443	57	386

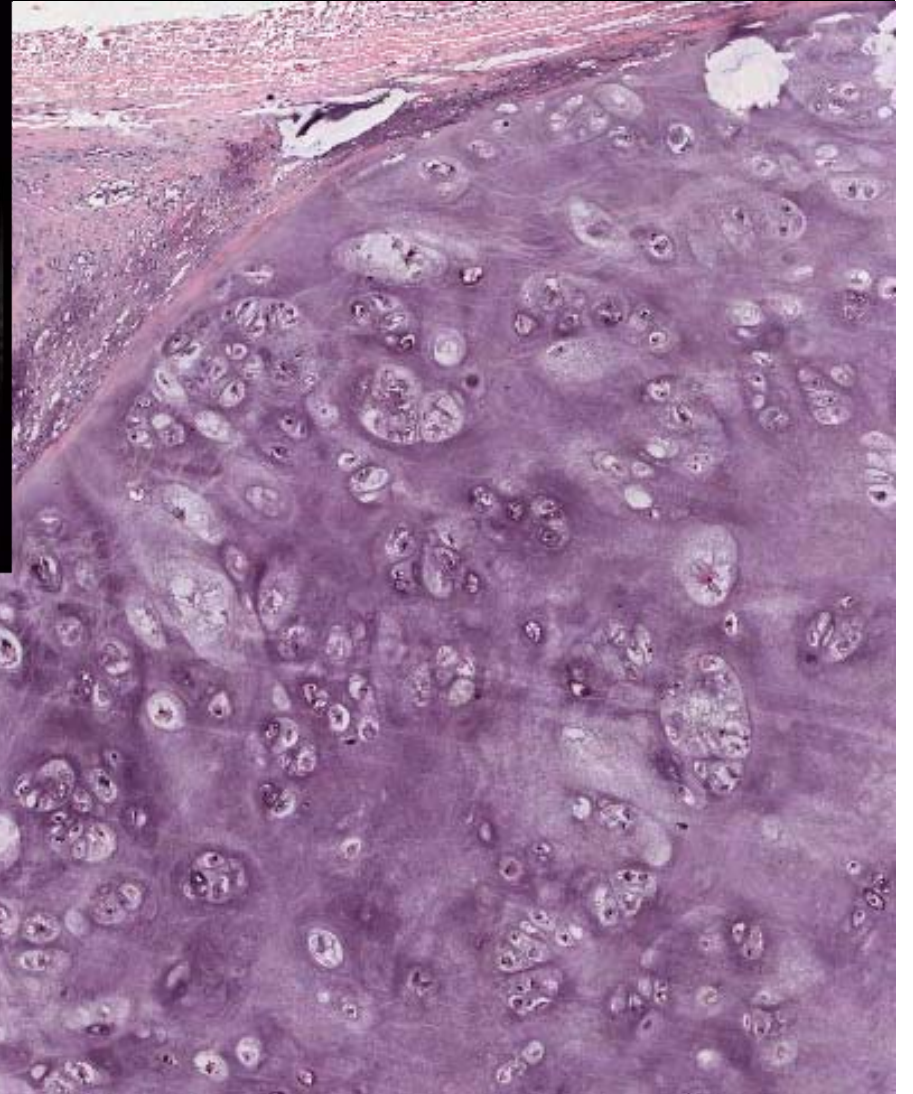
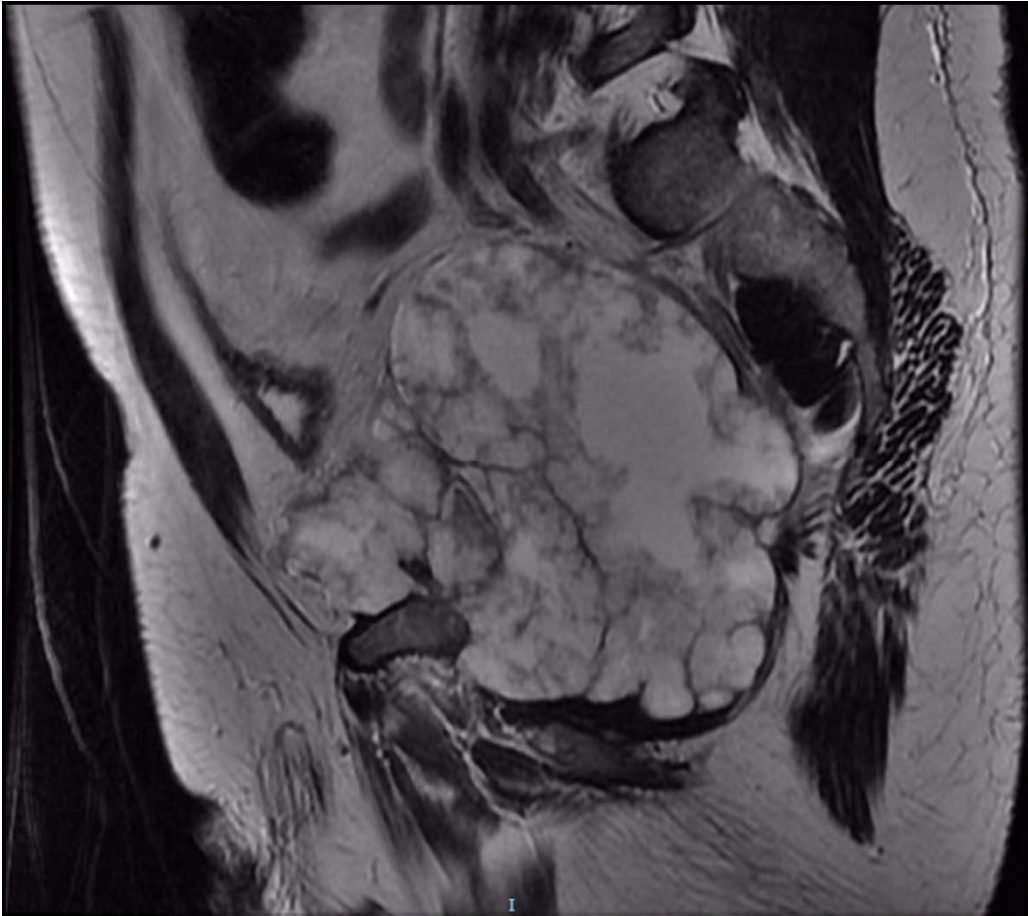
SATB2 immunohistochemical expression in chondrosarcomas

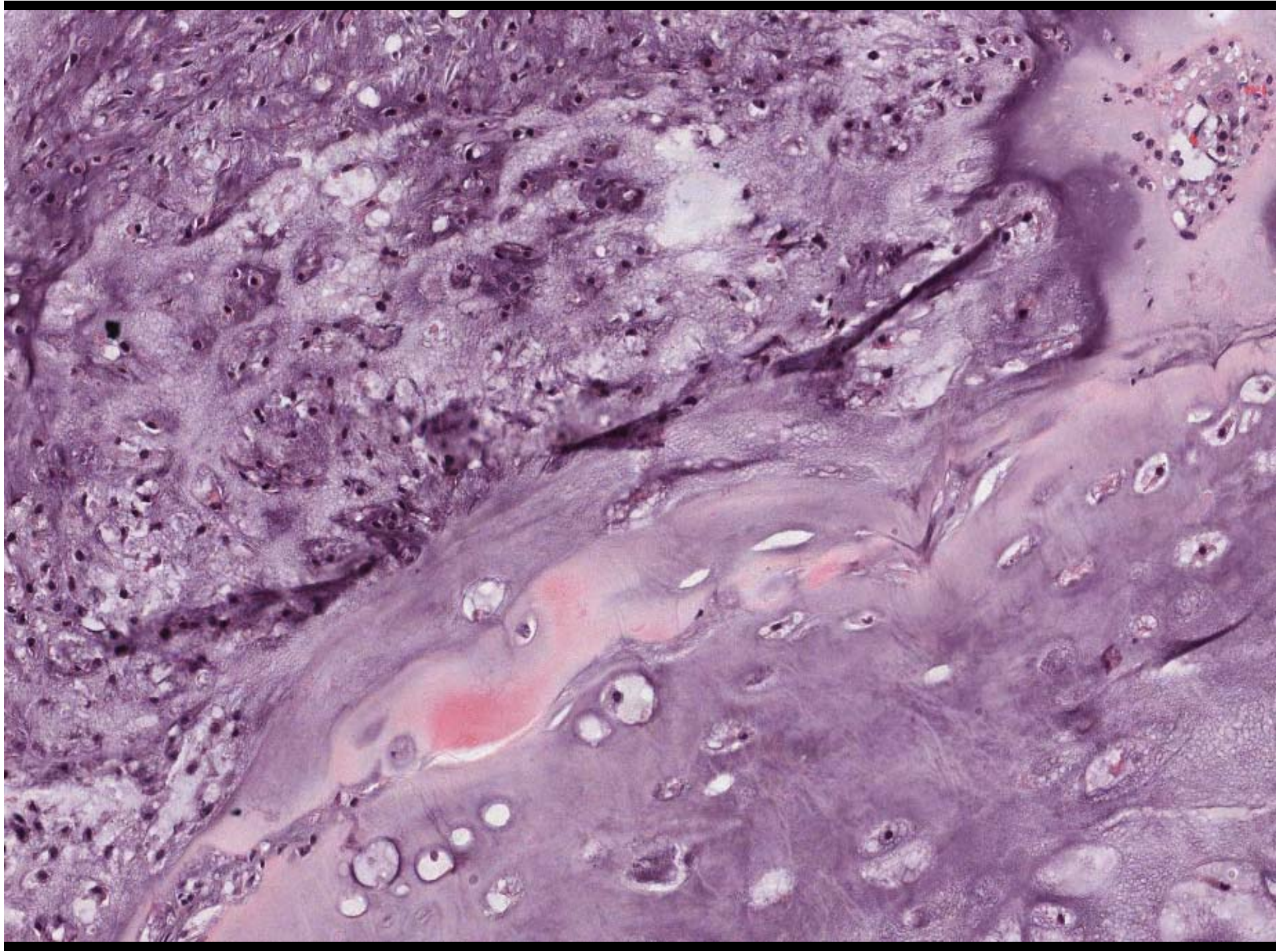
SATB2 Chondrosarcomas	Total	Positives	Negatives
Grade 1	12	1 (8.3%)	11 (91.7%)
Grade 2	9	5 (55.6%)	4 (44.4%)
Grade 3	10	8 (80%)	2 (20%)
Total	31	14 (46.6%)	17 (53.4%)

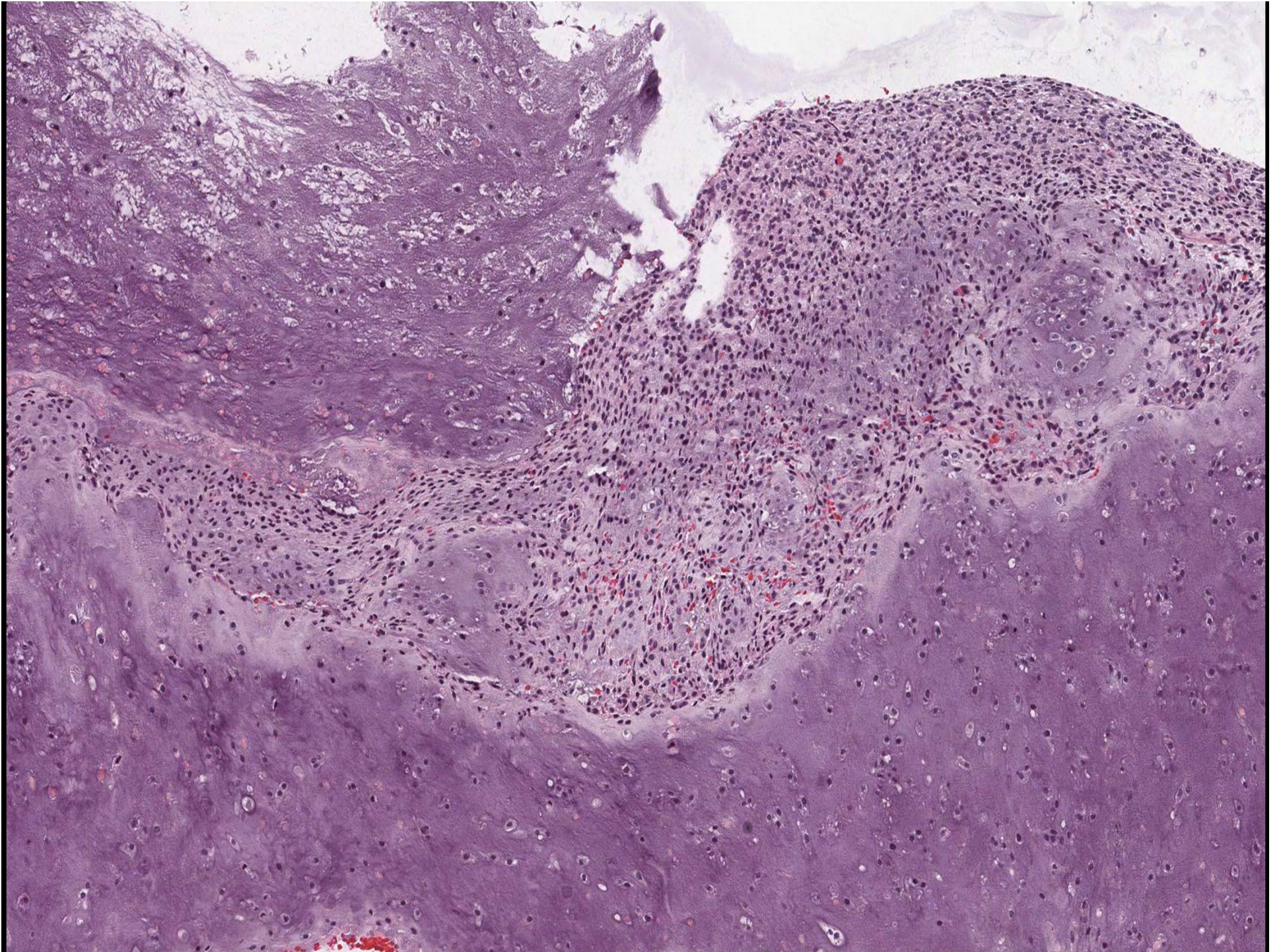


CORE NEEDLE BIOPSY / FNB









CHS CONVENTIONAL – TREATMENT

- EMINENTLY SURGICAL
- CHONDROSARCOMA IS RESISTENT TO
RXT Y QT.

CHS CONVENTIONAL - PROGNOSIS

DIRECTLY RELATED TO HISTOLOGICAL GRADE

GOOD FOR

- LOW-GRADE TUMORS.
- OVER 40Y AGE
- APENDICULAR


POOR PROGNOSTIC FACTORS:

- HIGH-GRADE TUMORS
- AXIAL/PELVIC TUMOR LOCATION.
- INADEQUATE RESECTION



THANK YOU

شكرا لك، شكرا







CONDROSARCOMA I

Histología

- Permeación de espacios medulares.
- Contacto de neoplasia con trabéculas nativas.
- Atrapamiento de trabéculas nativas.
- Lóbulos condroides separados por bandas fibrosas.
- Reabsorción endostal.
- Permeación de Havers
- Degeneración mixoide
- Necrosis
- Atipía celular picnosis nuclear
- Ki 67 +

CS 2

- Celularidad mas importante
- Patron lacunar retenido
- Nucleos de tamaño variado,
- Citoplasma abundante
- Sin atipia importante

CS 3

DIAGNOSTICO HISTOLOGICO

ALTA CELULARIDAD

CÉLULAS ATÍPICAS

PERDIDA DEL ASPECTO LACUNAR

MITOSIS OCASIONALES (2-5/10HPF)

TU C/ALTO NO. DE MITOSIS – SUGIERE OS
CONDROBLASTICO O CS
DESDIFERENCIADO.

AREAS DE “MATRIZ MIXOIDE NEOPLASICA”

CS SECUNDARIO

OSTEOCONDROMA – 1% (RISCO)

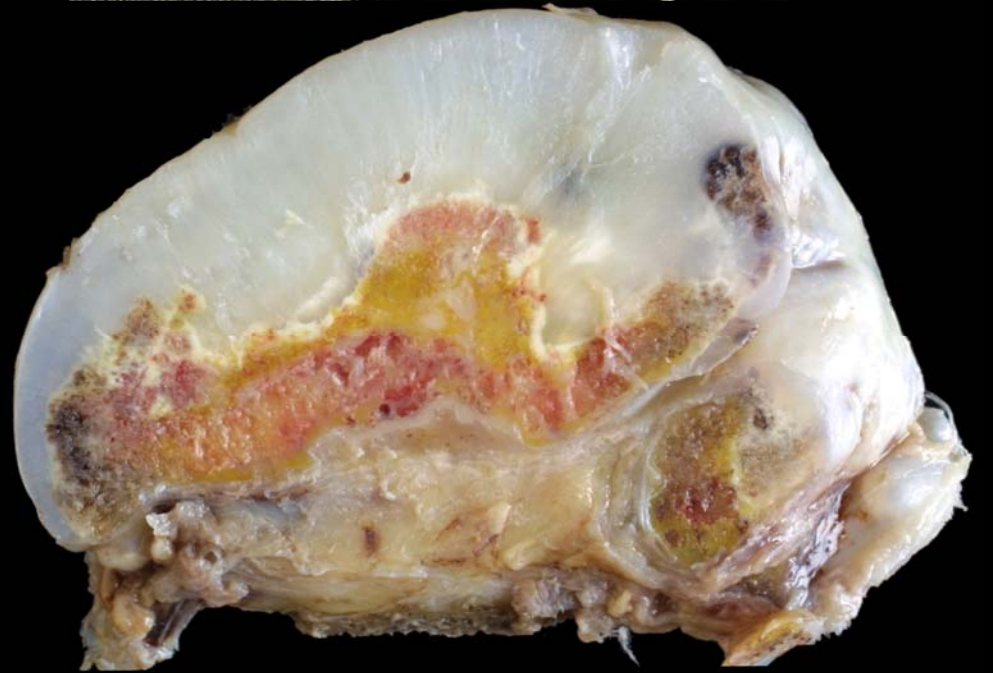
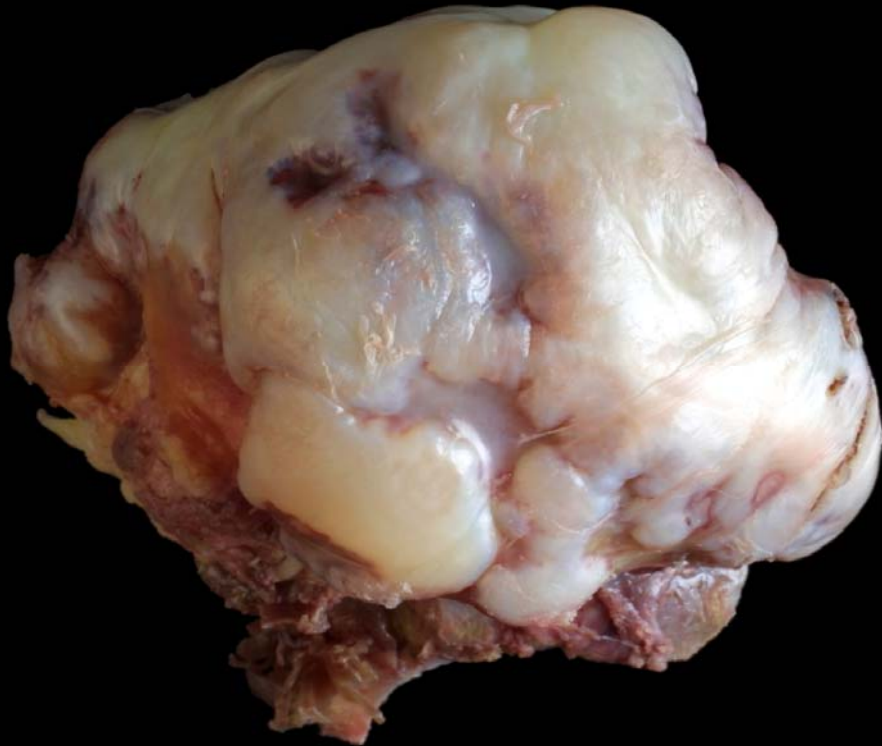
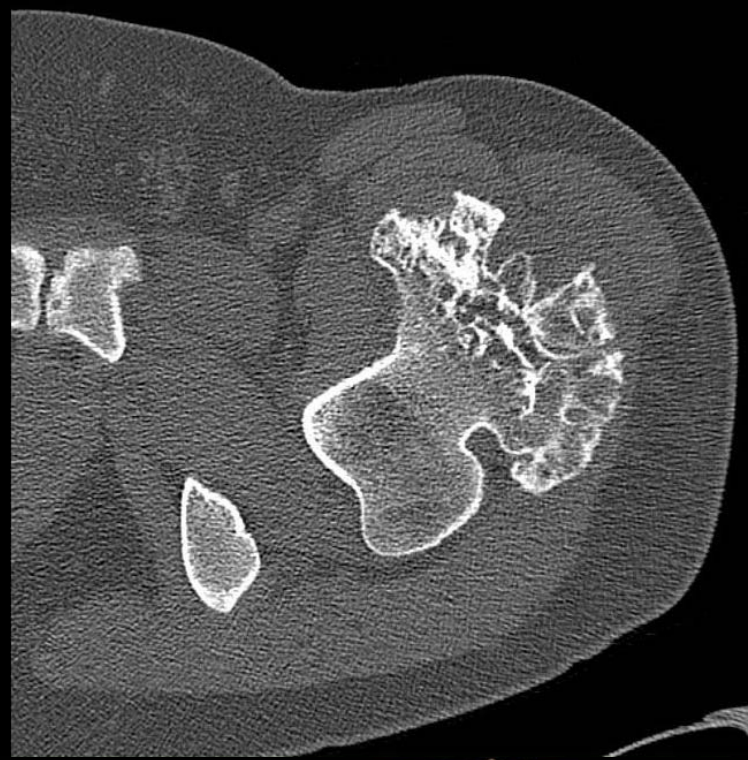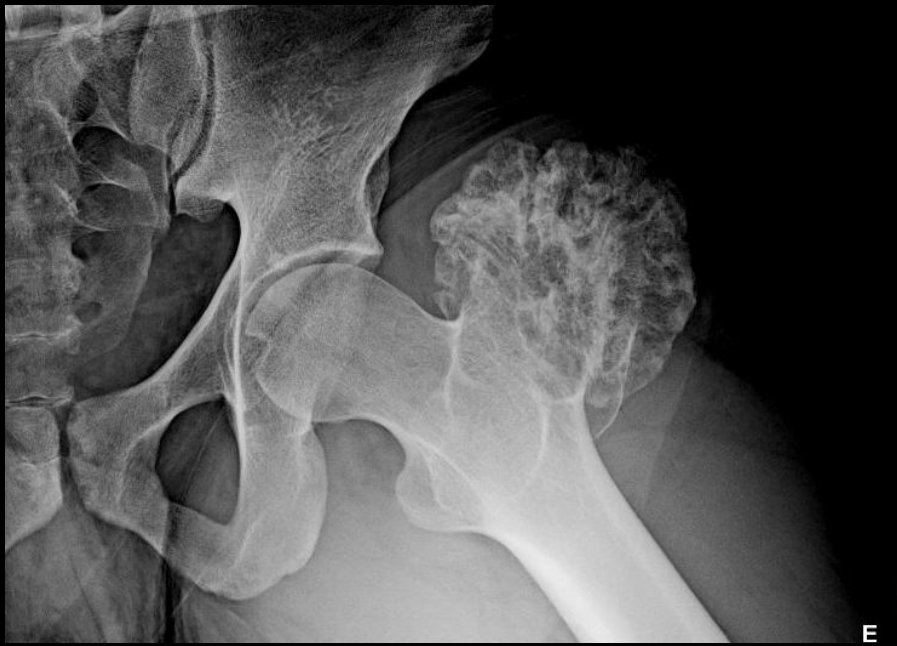OSTEOCONDROMATOSIS (EXOSTOSIS
MULTIPLE HEREDITARIA) -10%

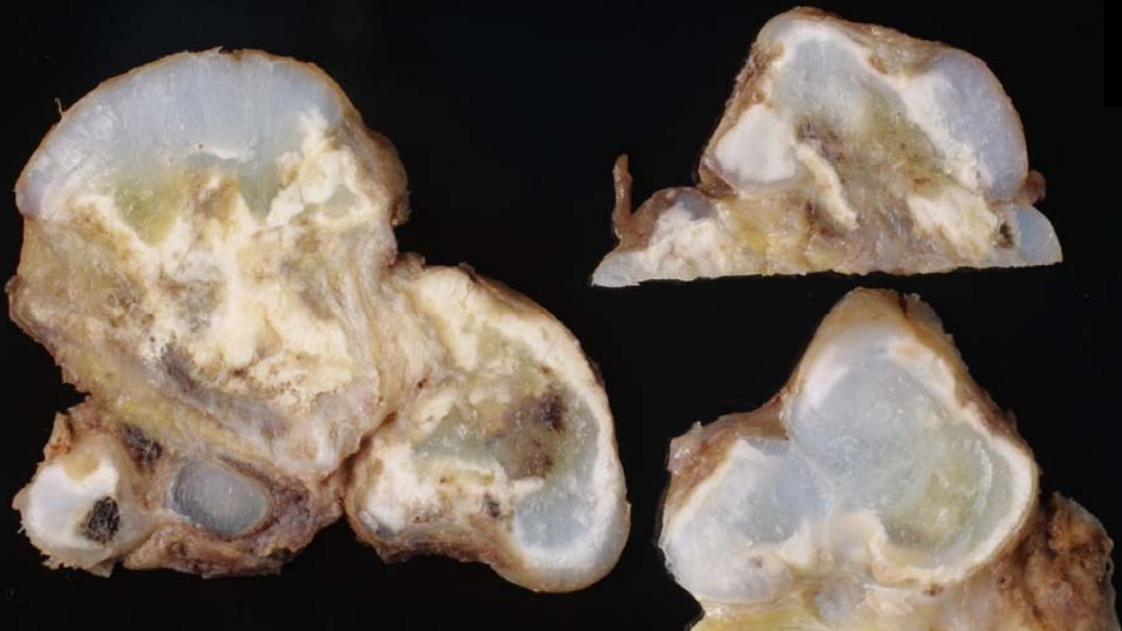
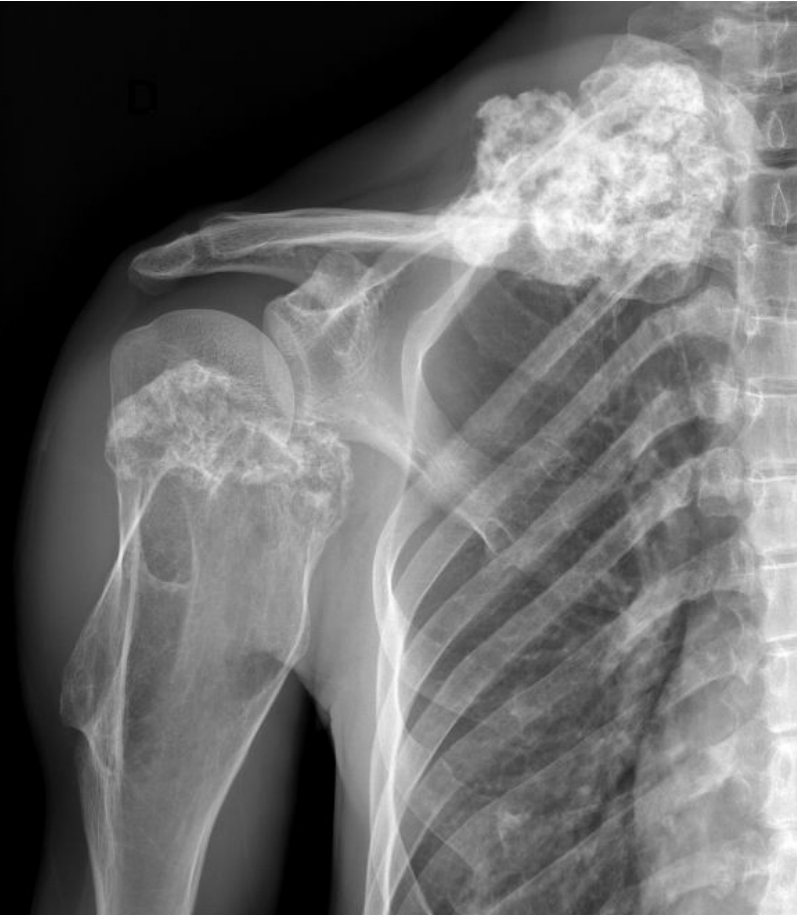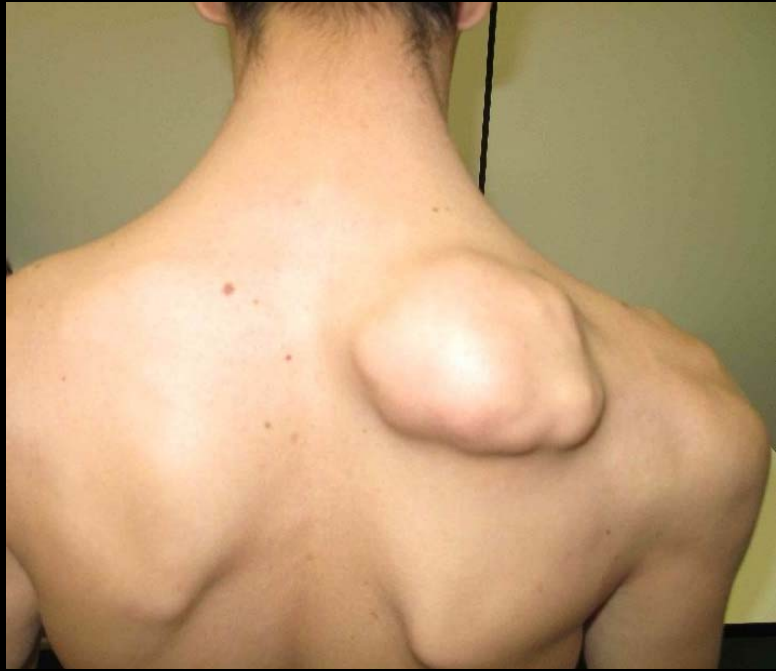ENCONDROMATOSIS MULTIPLA (MOLESTIAS
DE OLLIER, MAFFUCCI) – 15-30%

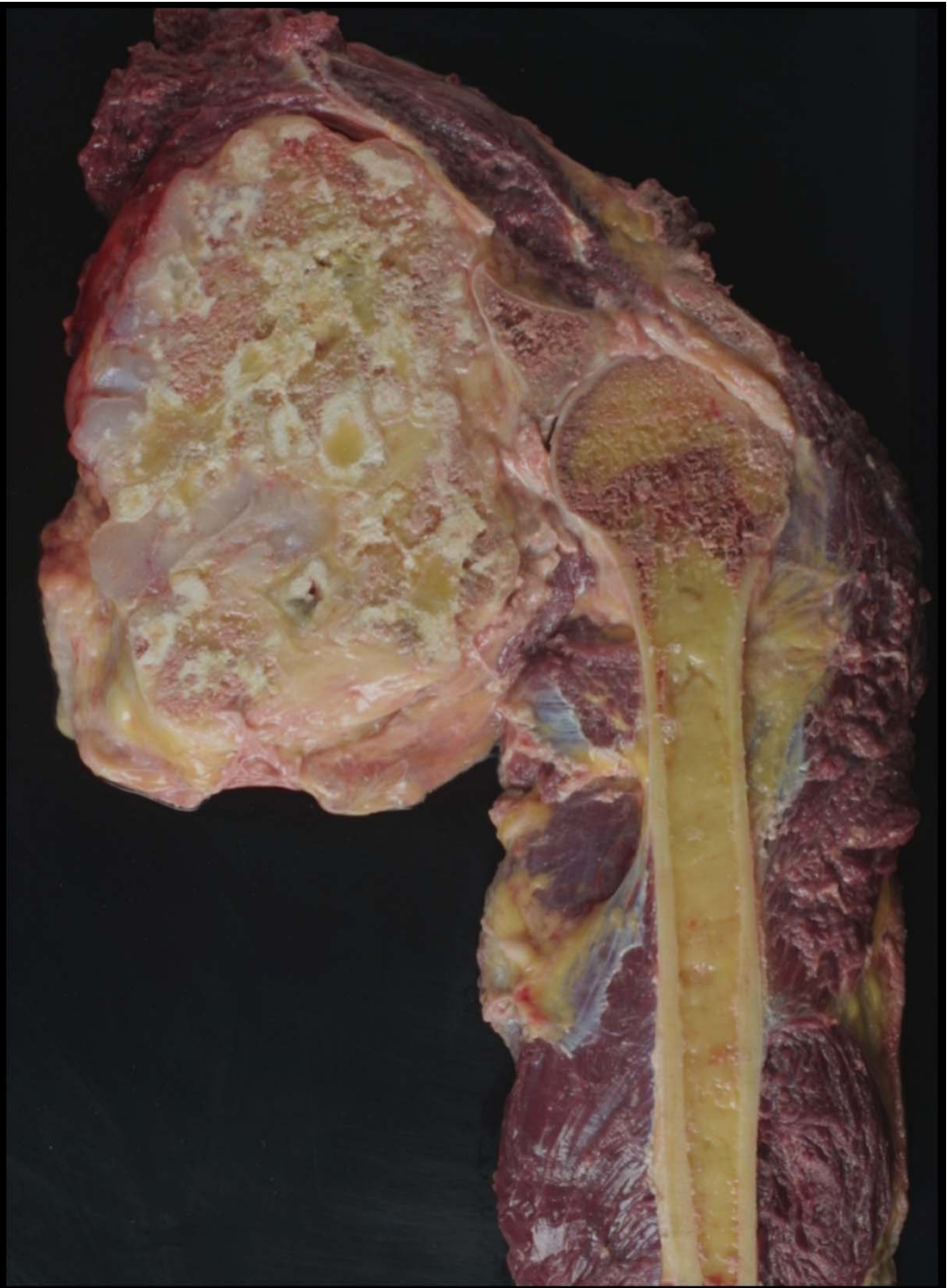
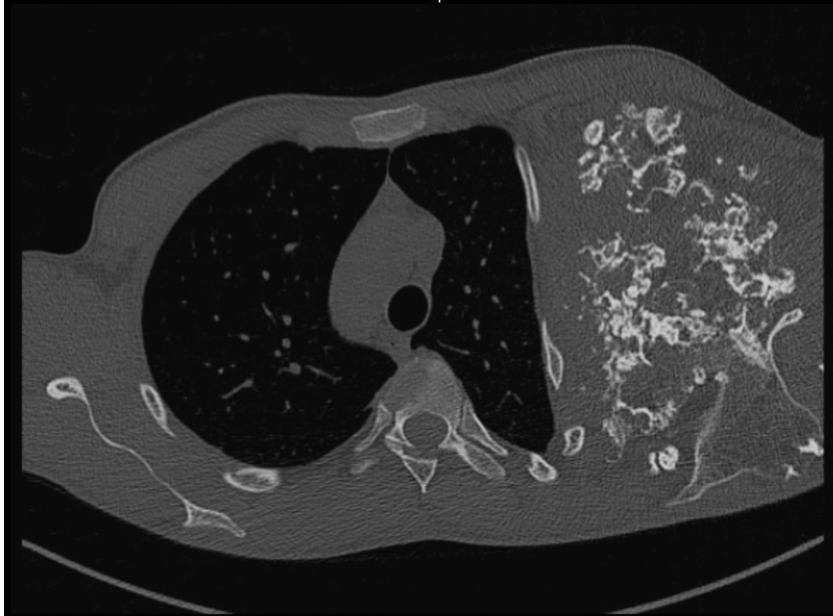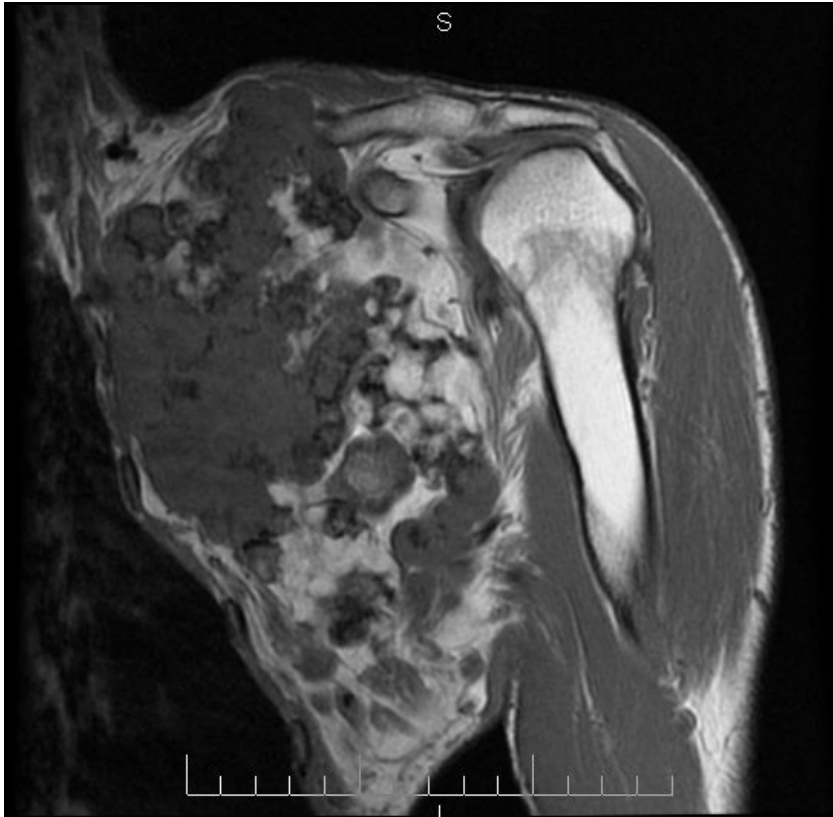
CS SECUNDARIO EN OSTEOCONDROMA/OSTEOCONDROM ATOSIS

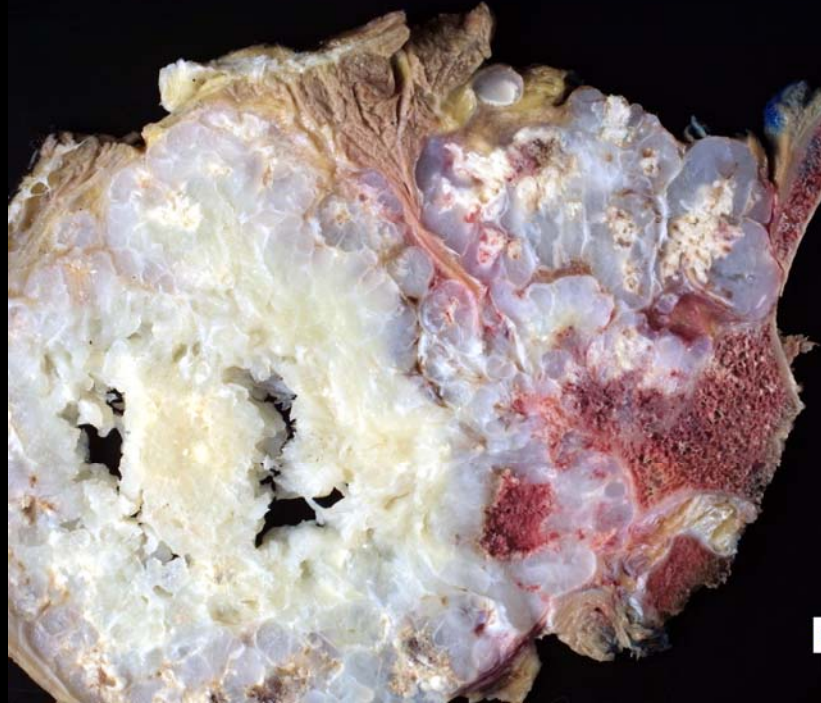
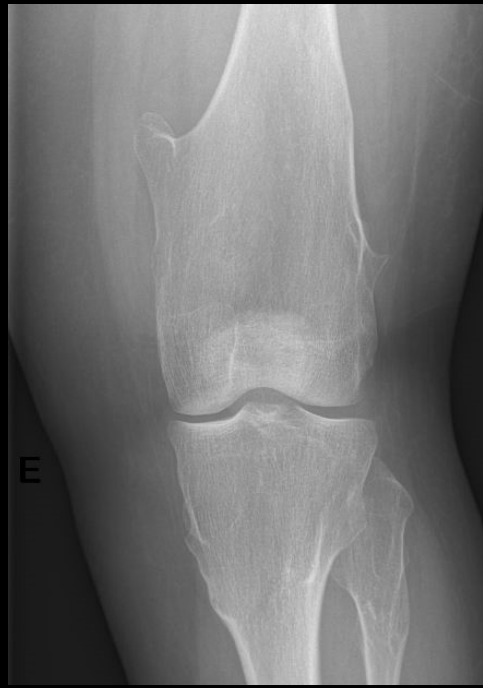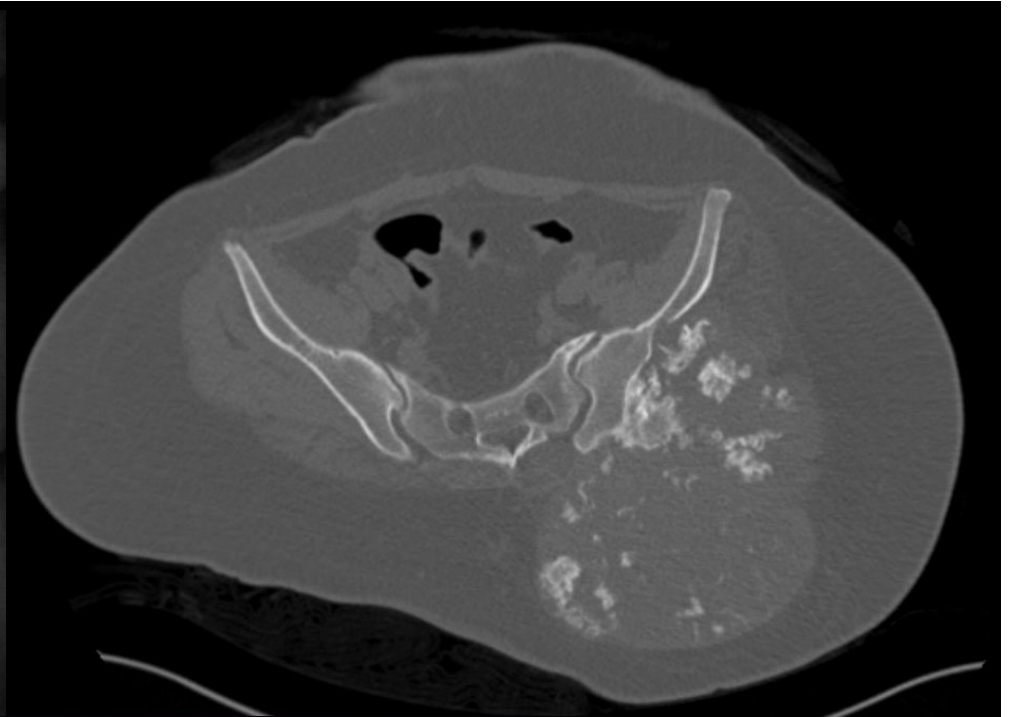
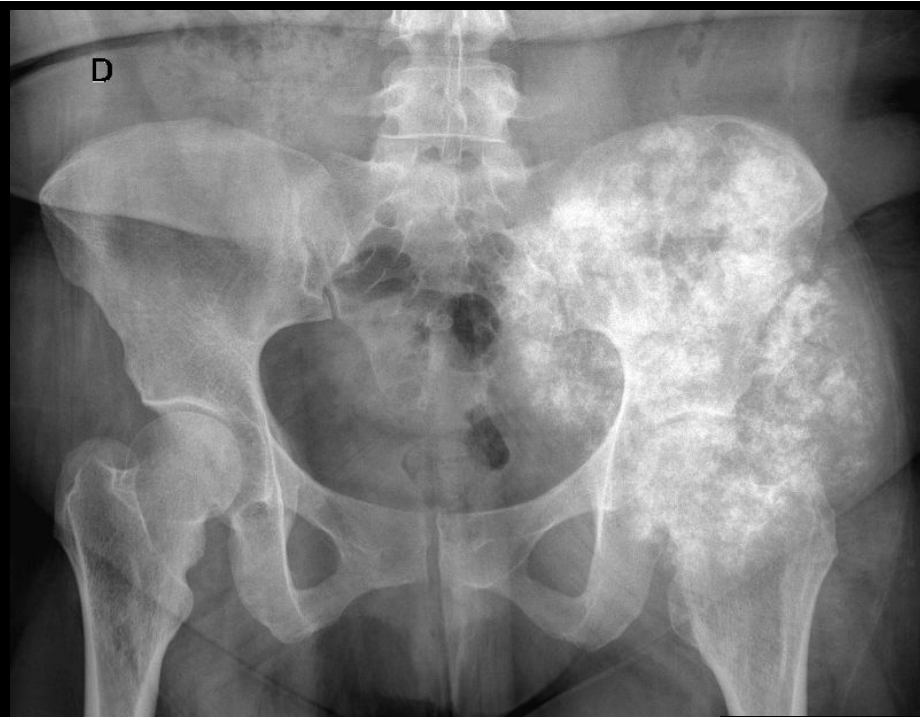CAPA CARTILAGINOSA >2 CM DE ESPESOR,
EN UN ESQUELETO ADULTO

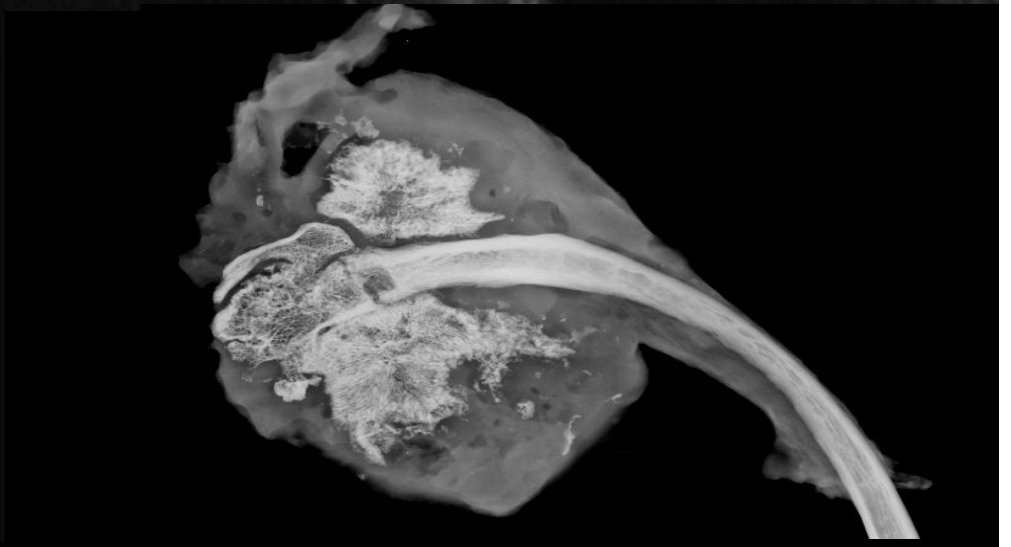
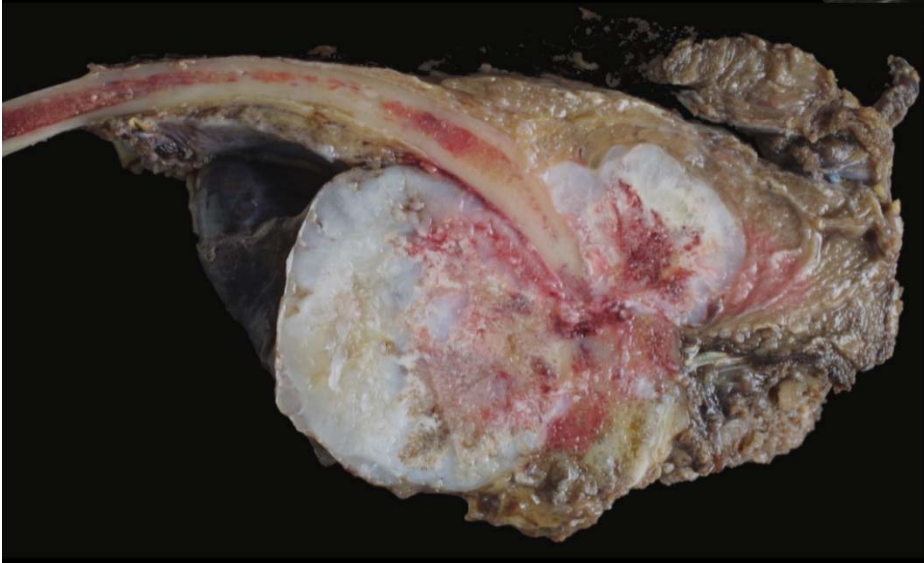
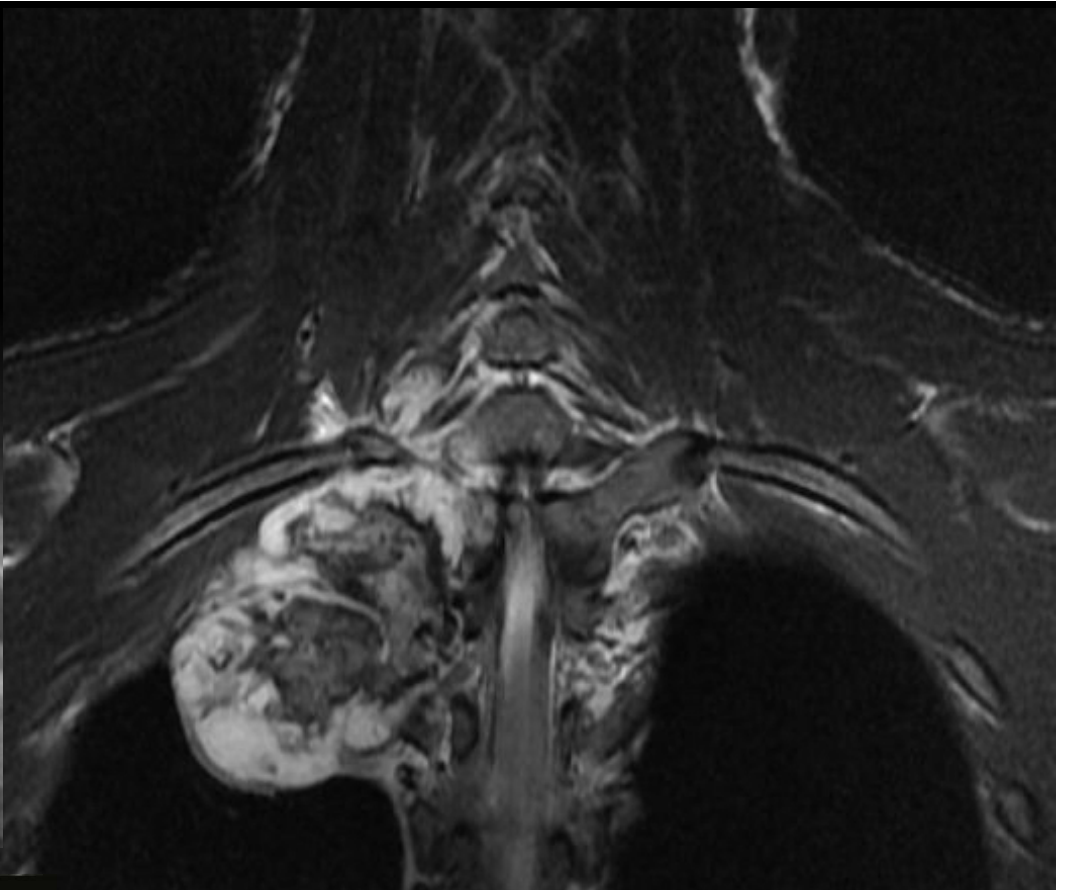
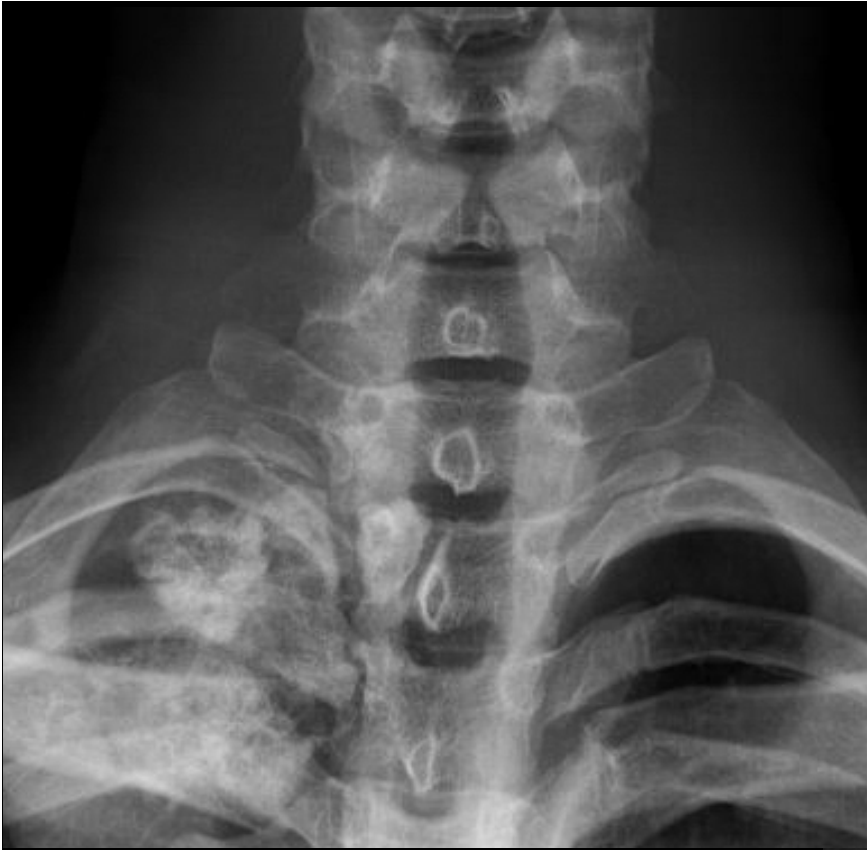BAJO GRADO

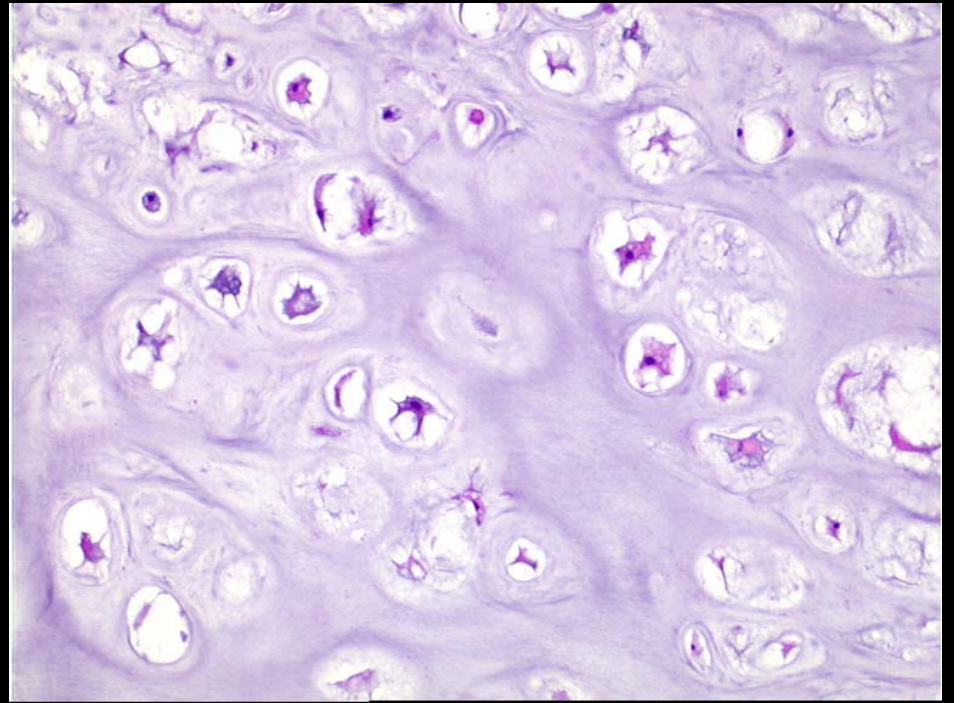
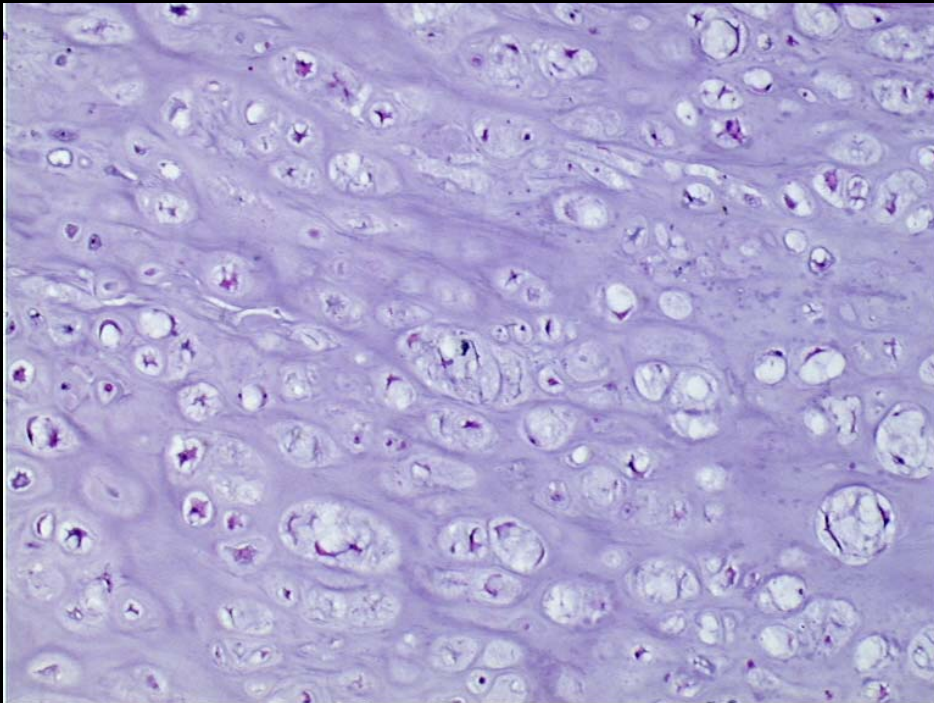
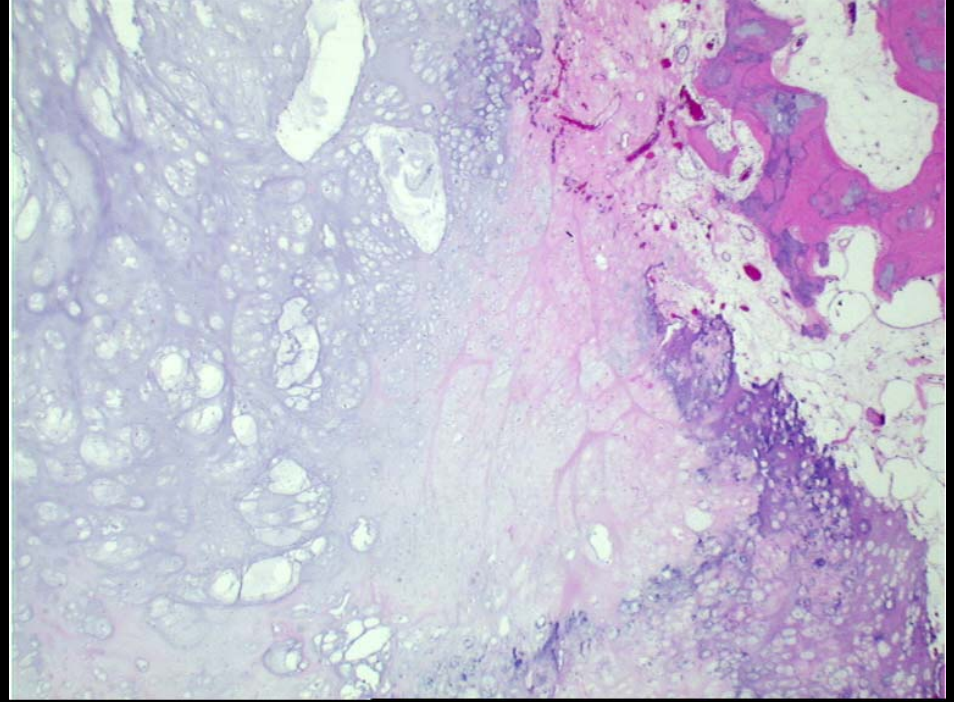
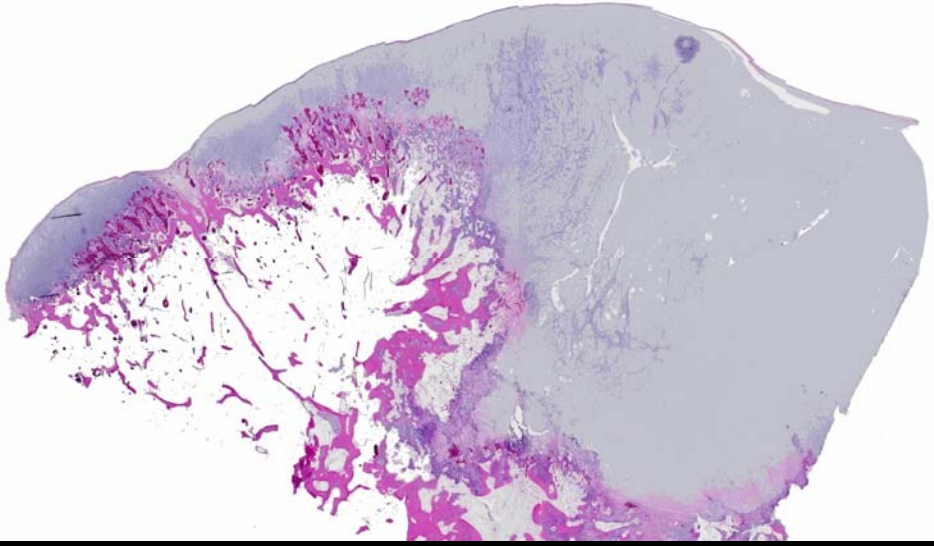


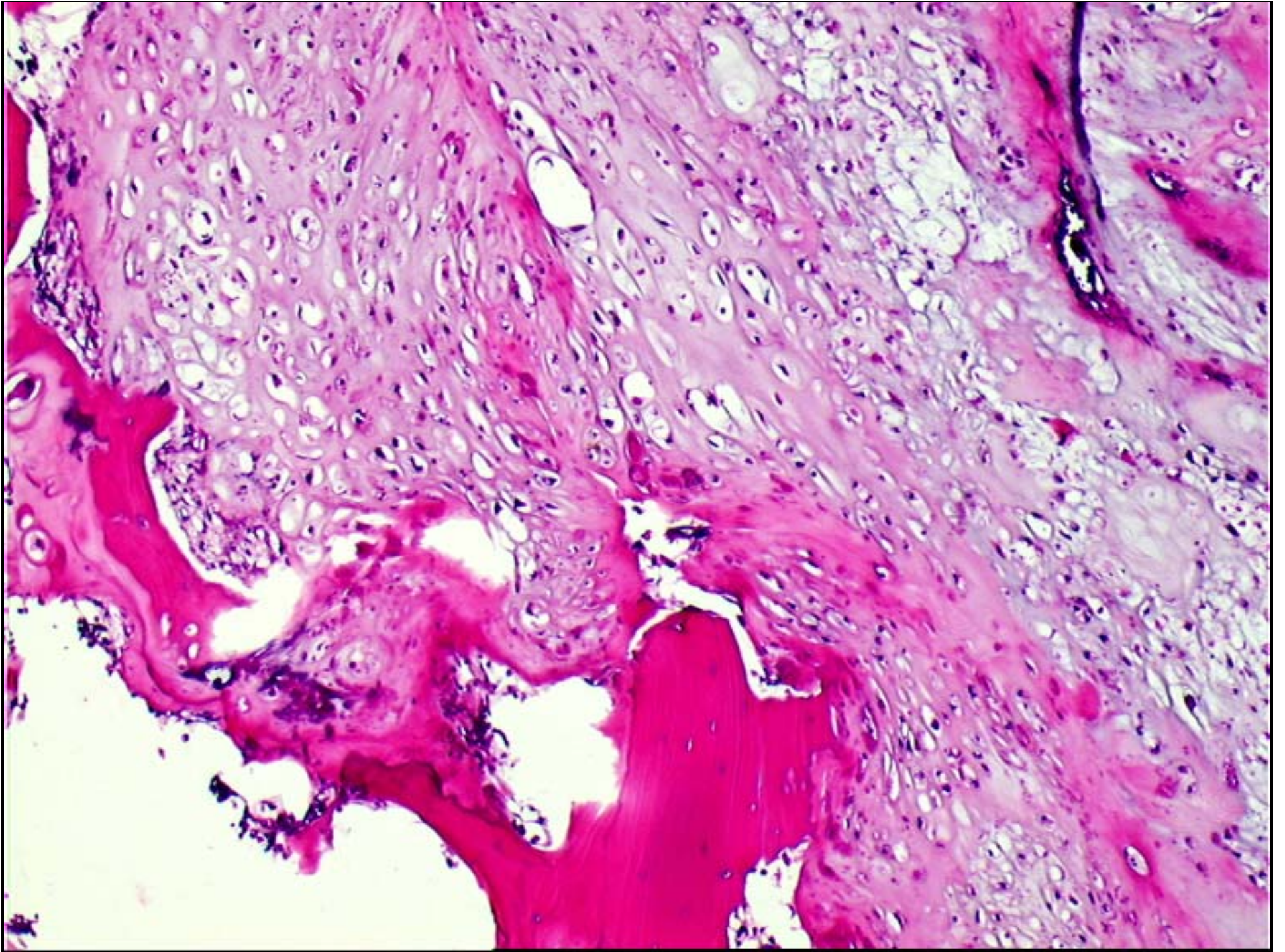










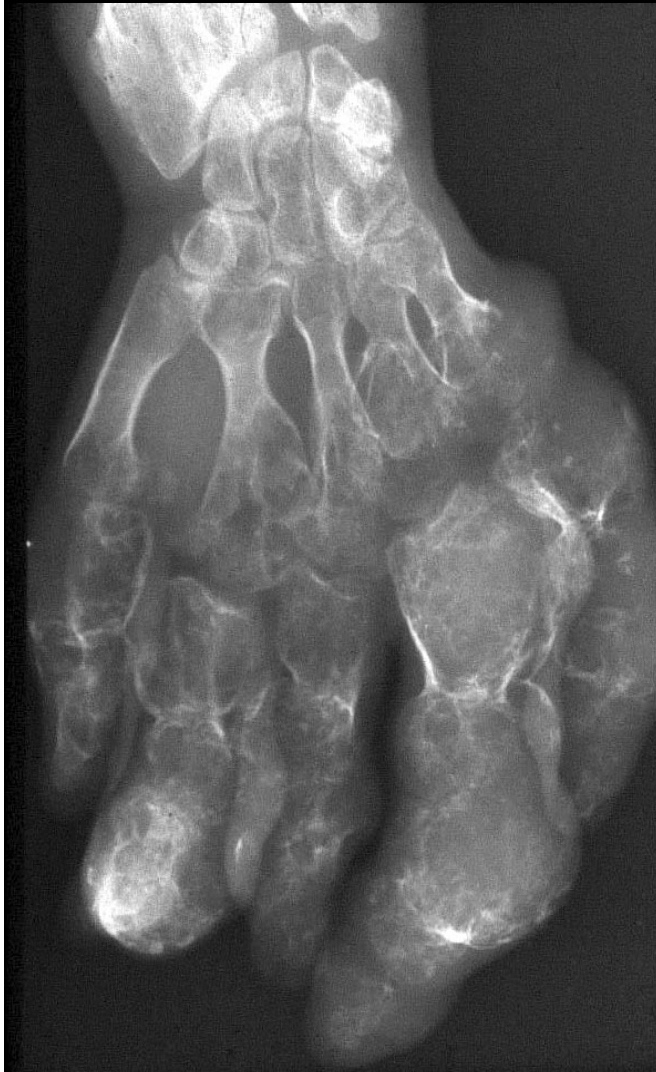

CS SECUNDARIO EN ENCONDROMATOSIS

DOLOR, CRECIMIENTO, FRACTURA PATOLOGICA
HUESOS LARGOS O ESQUELETO AXIAL

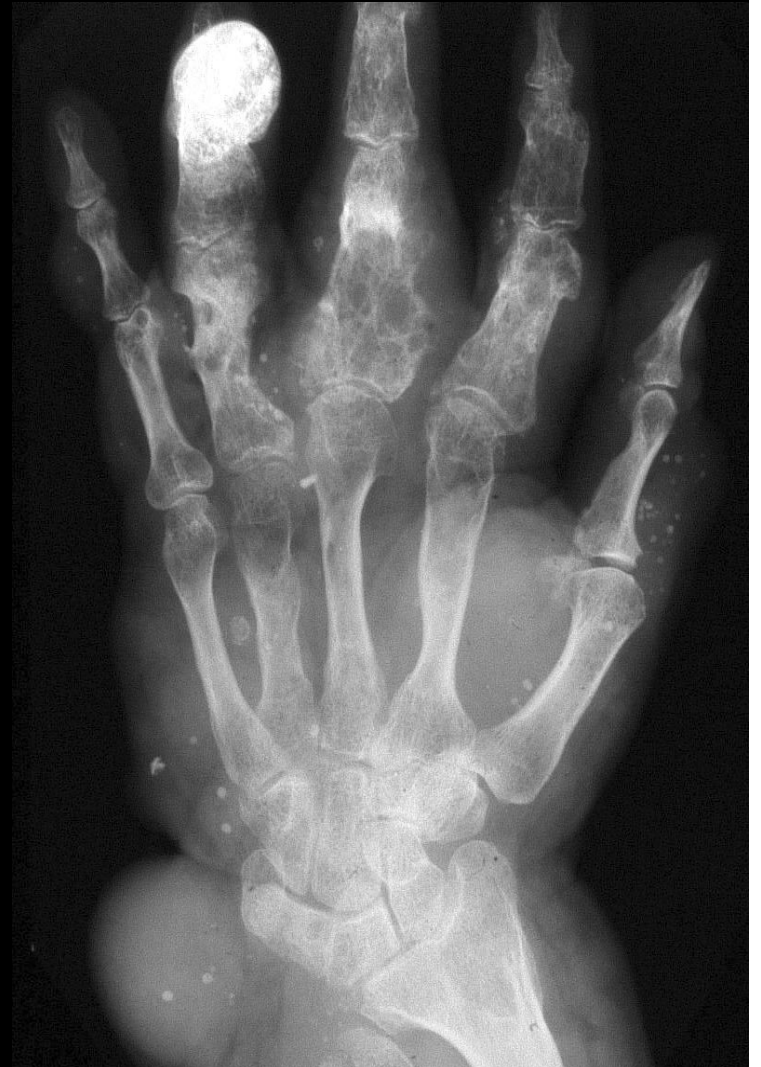MONOFOCAL, EN GENERAL. MULTIFOCAL EN HASTA
30%.

MULTIPLE ENCHONDROMATOSIS



OLLIER

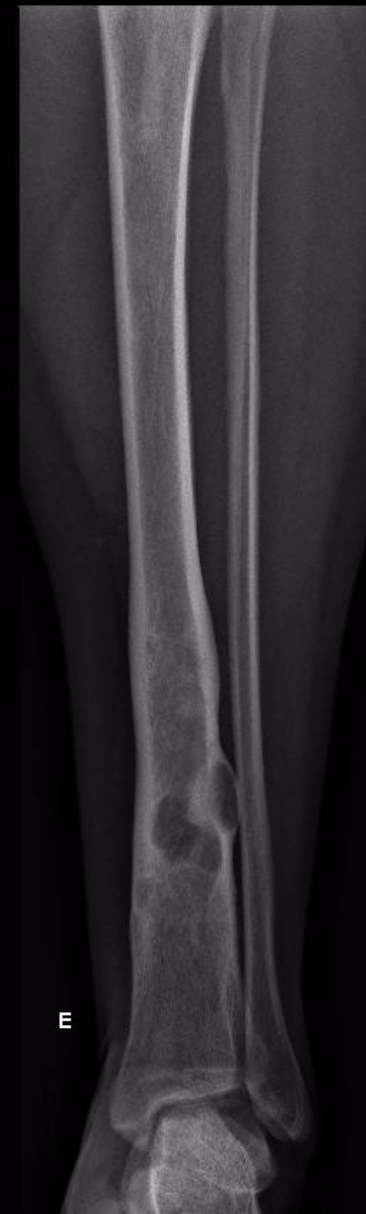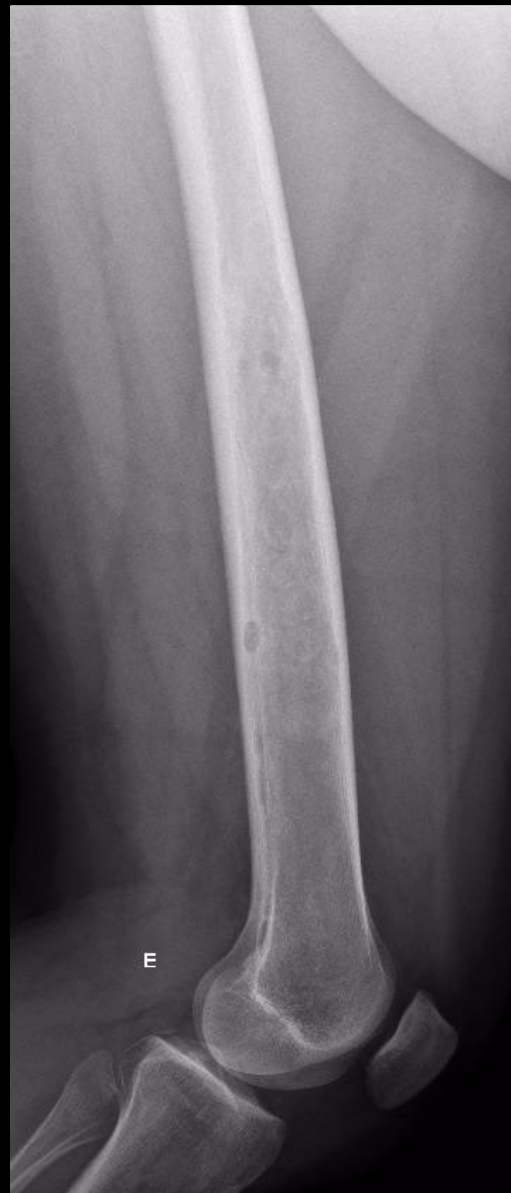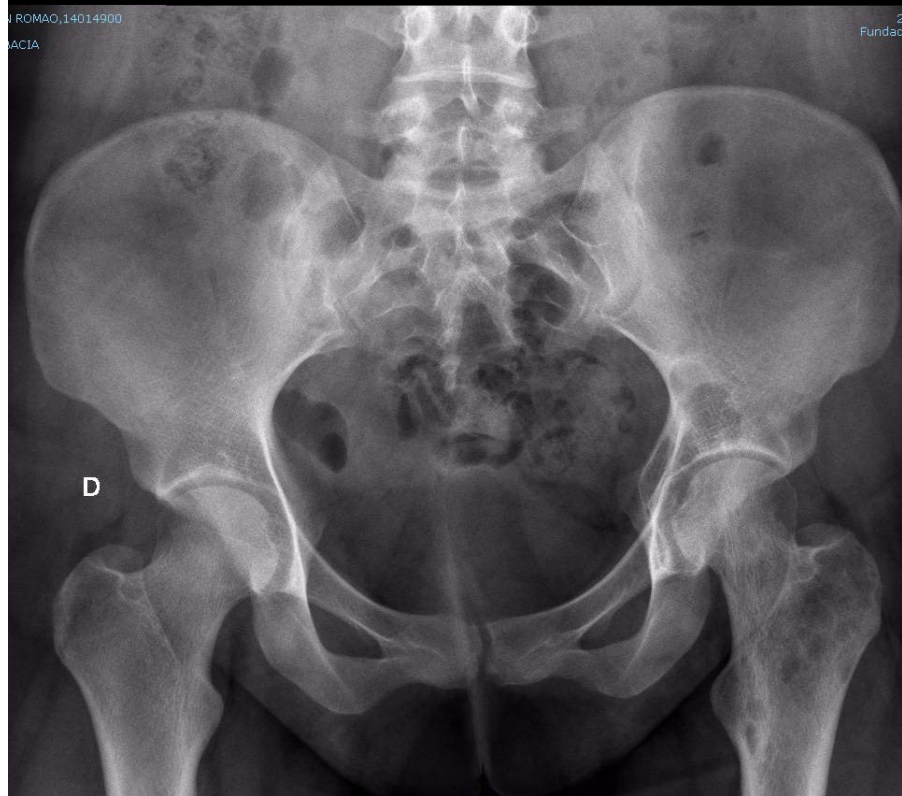
MAFFUCCI

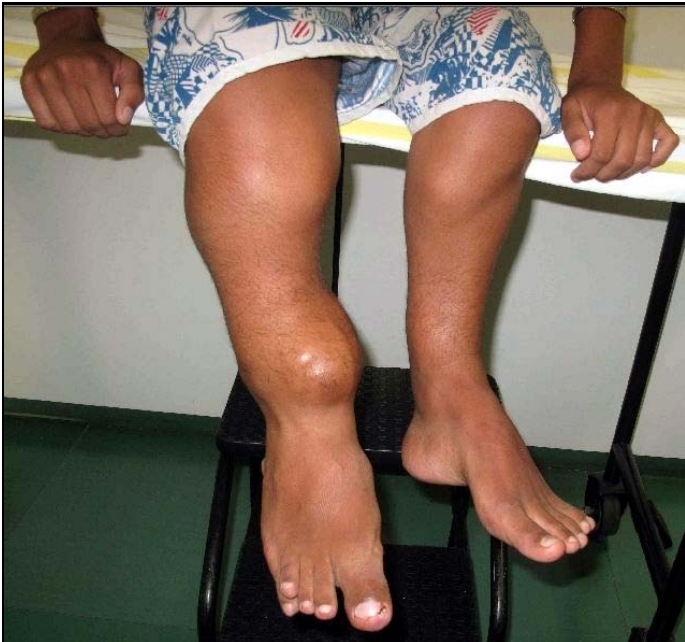

ENCHONDROMATOSIS

UNILATERAL OR BILATERAL.
MALIGNIZATION RISK: 25%

ENCHONDROMATOSIS - UNILATERAL

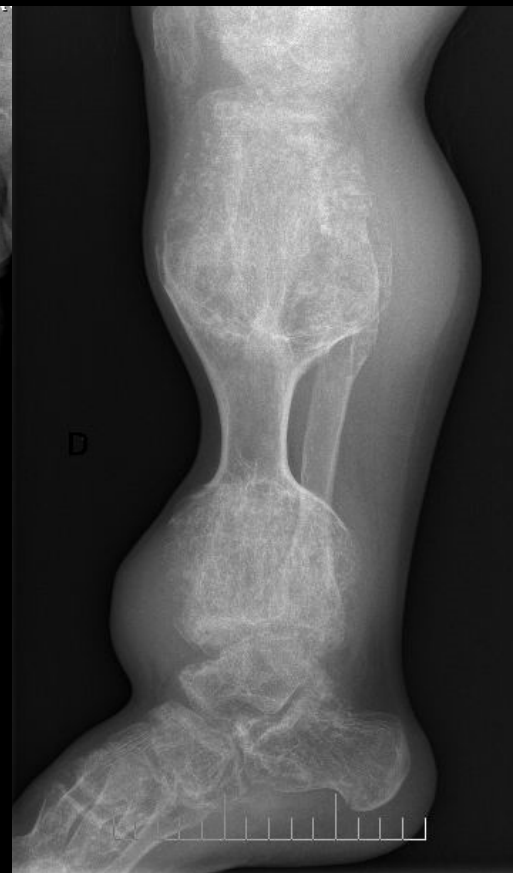
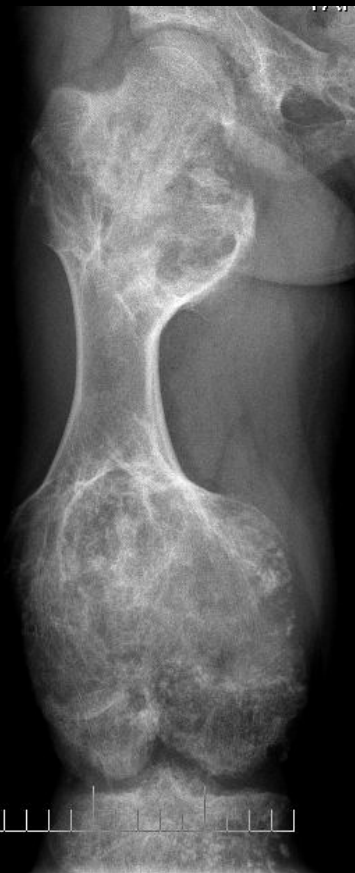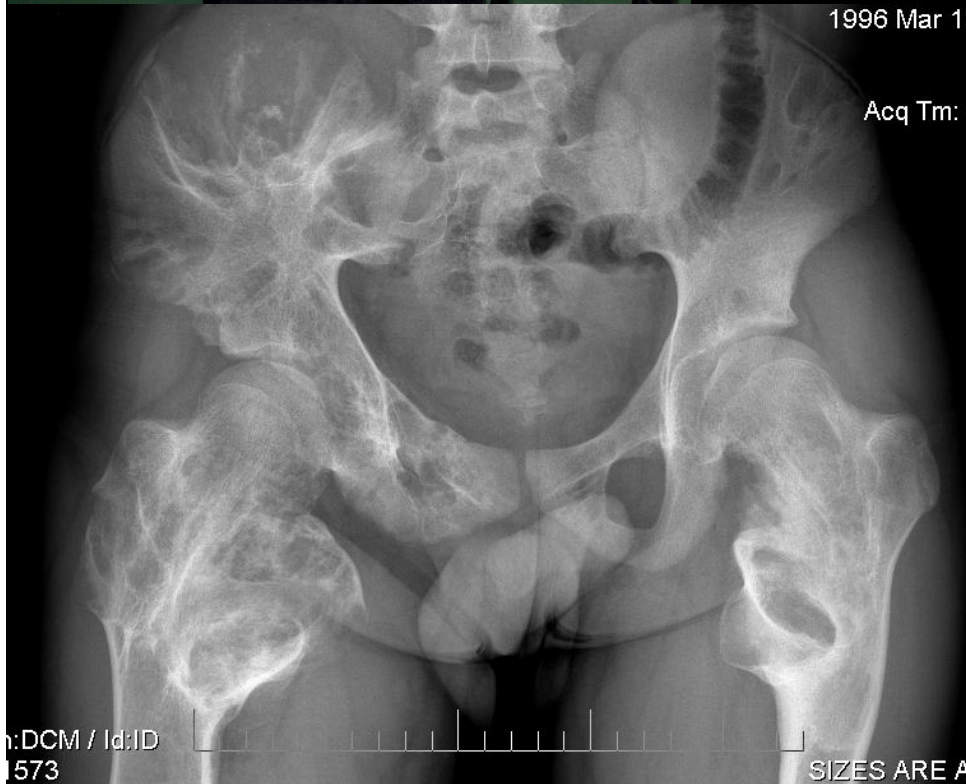




ENCHONDROMATOSIS

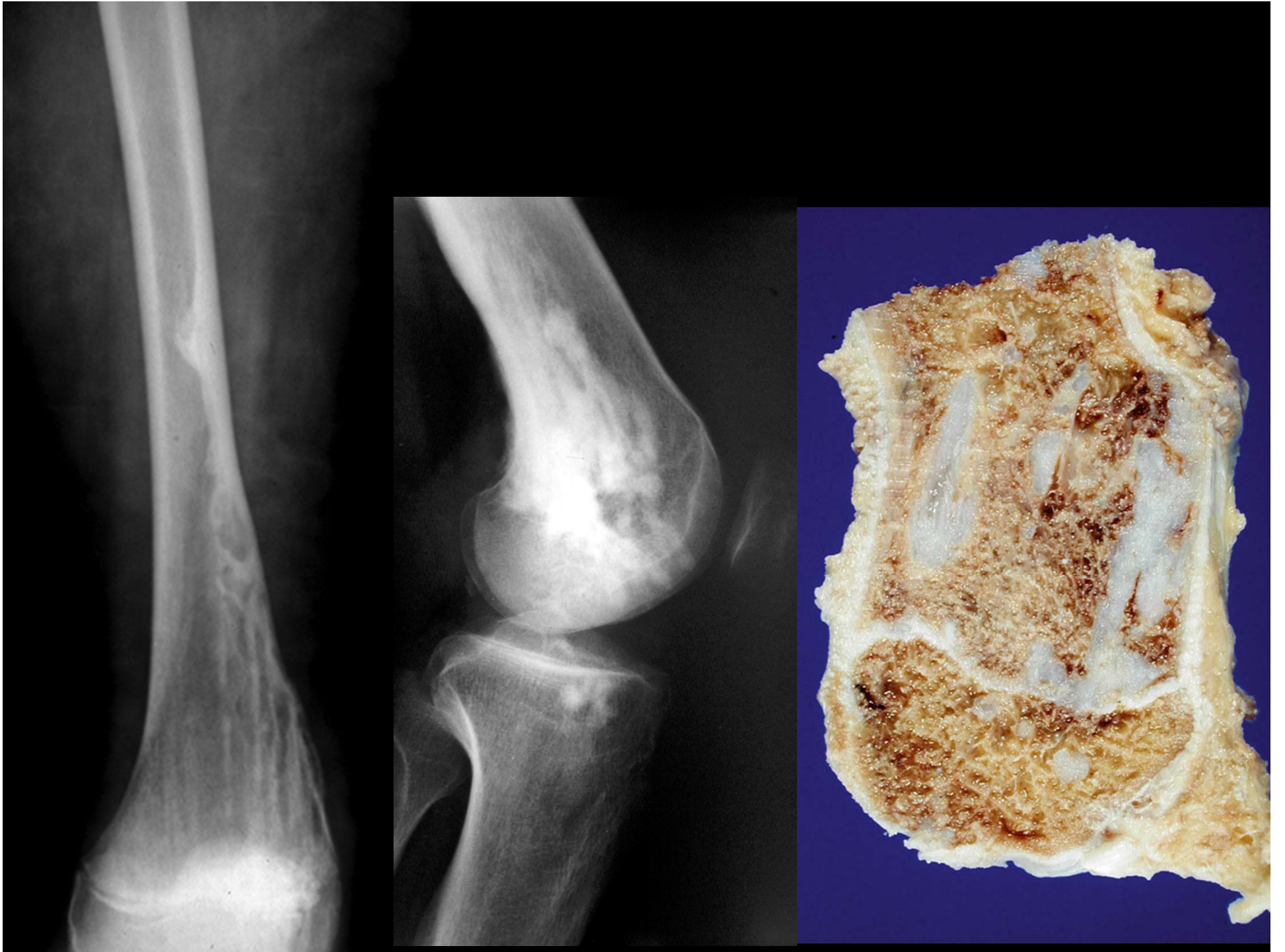1996 Mar 13

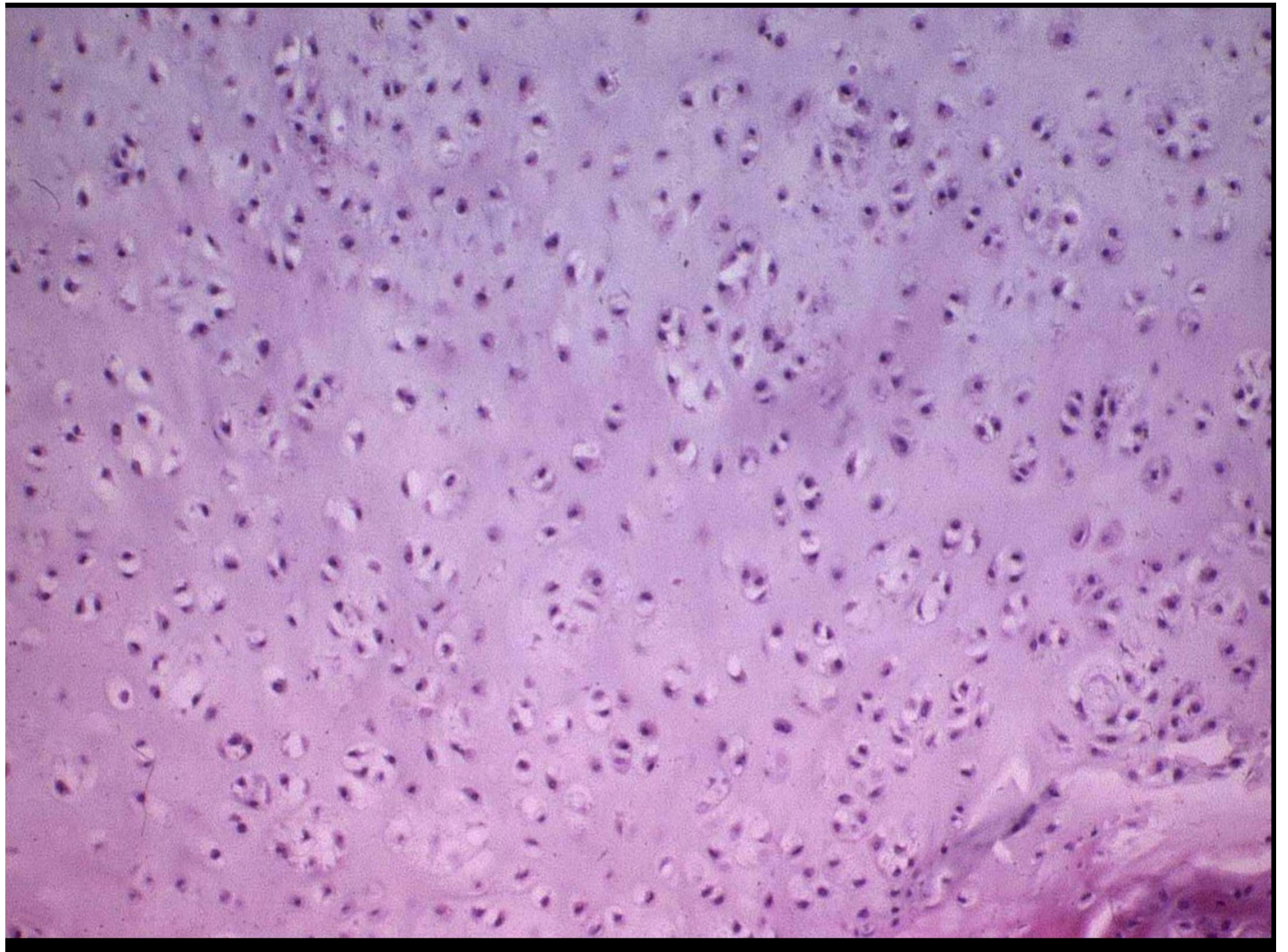
Acq Tm: 1

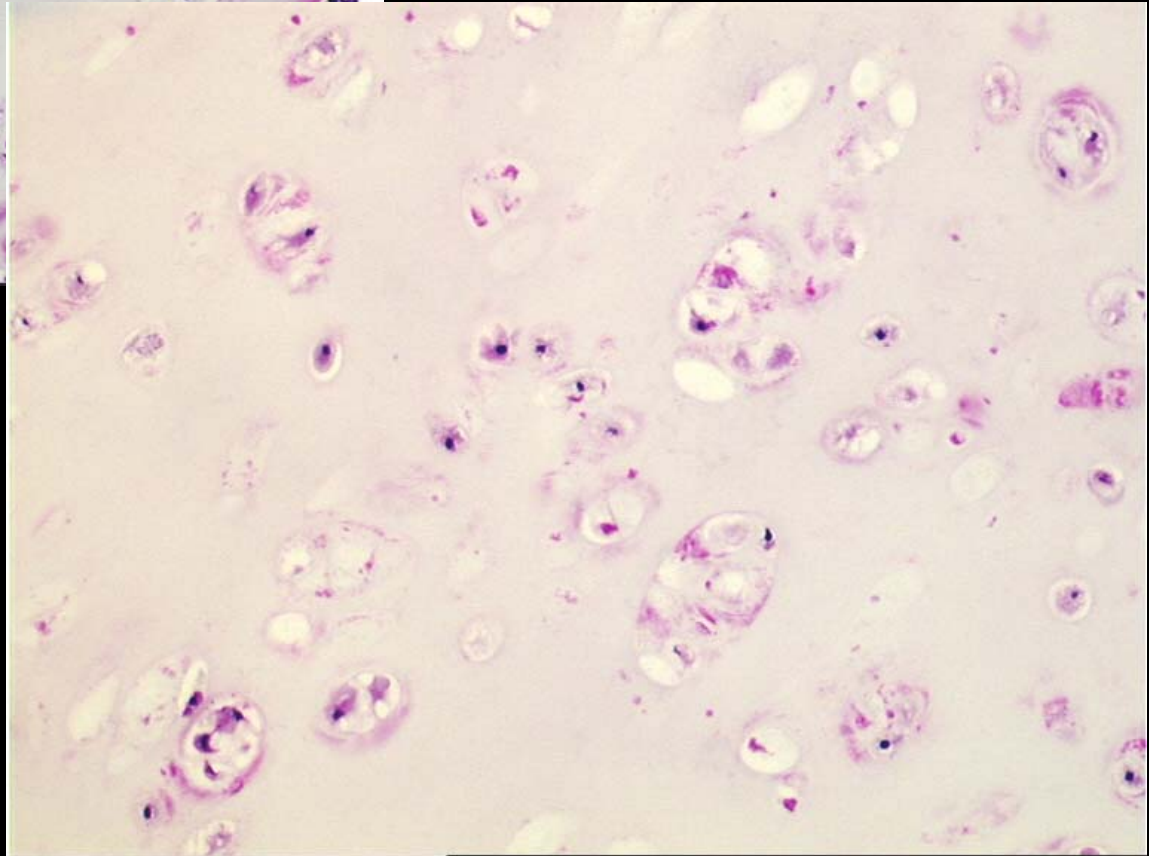
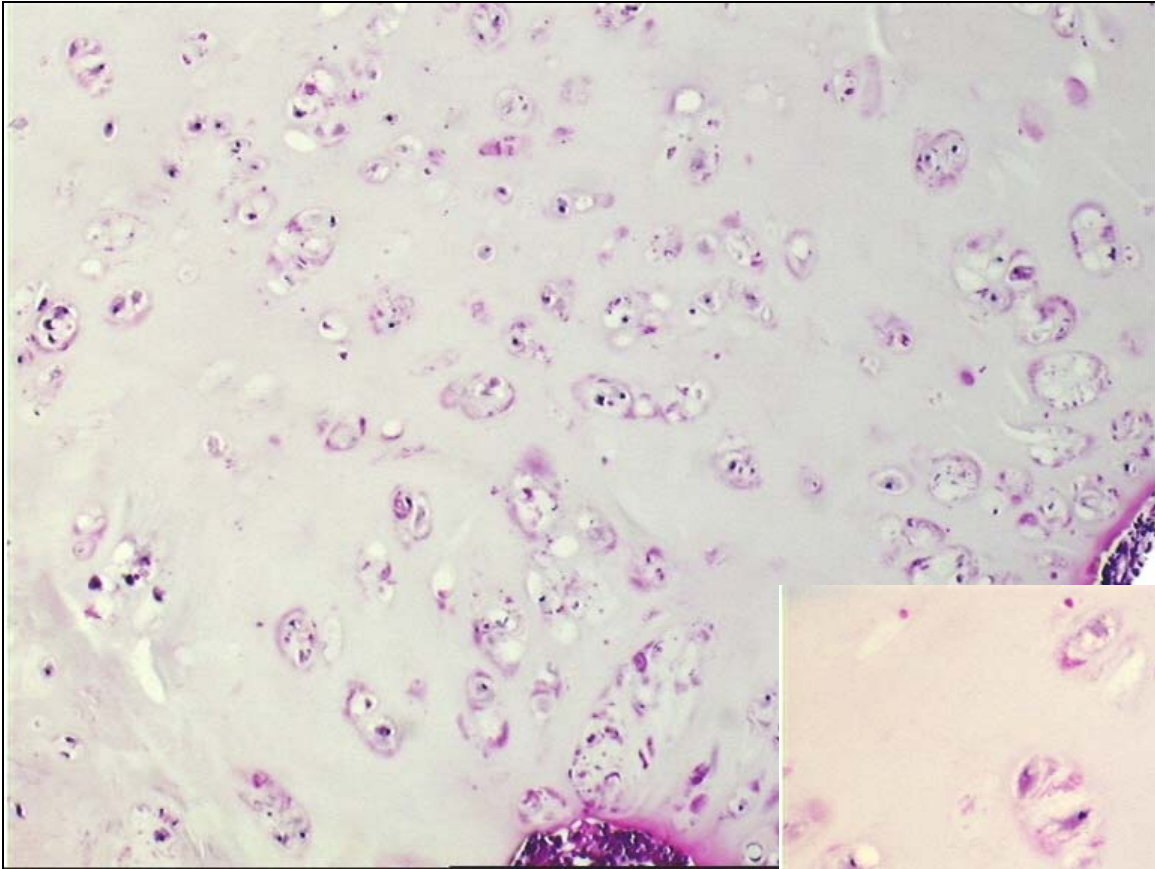


h:DCM / Id:ID
1573

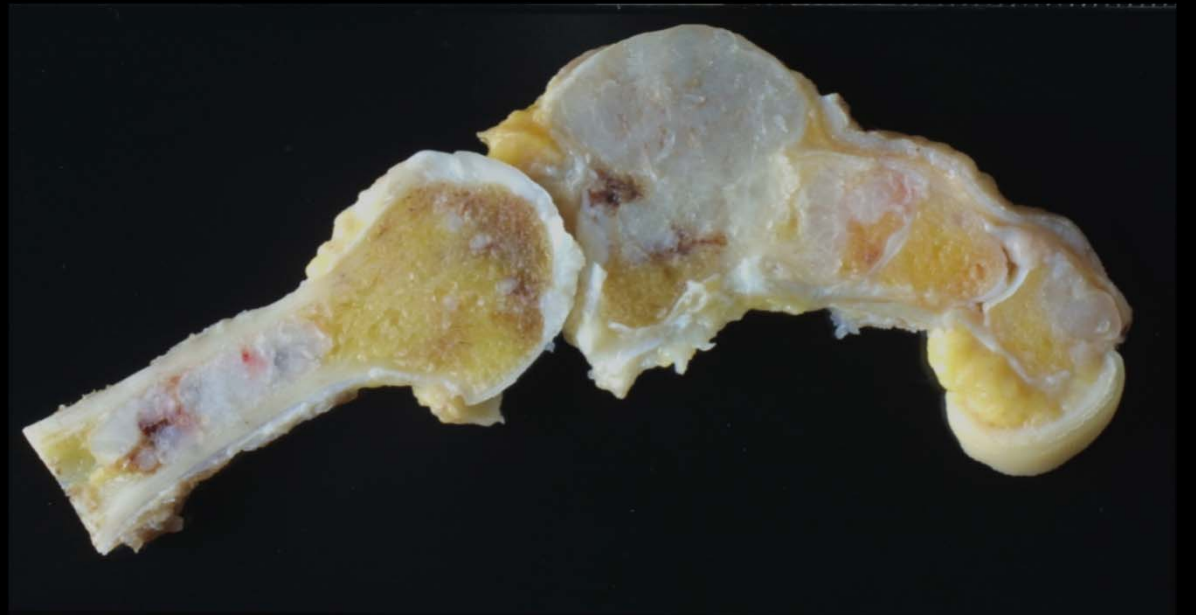
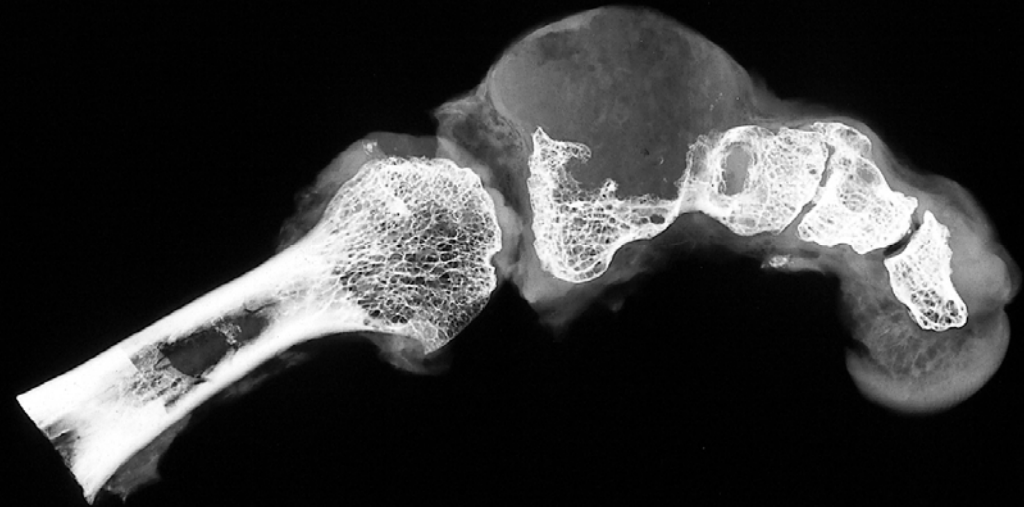
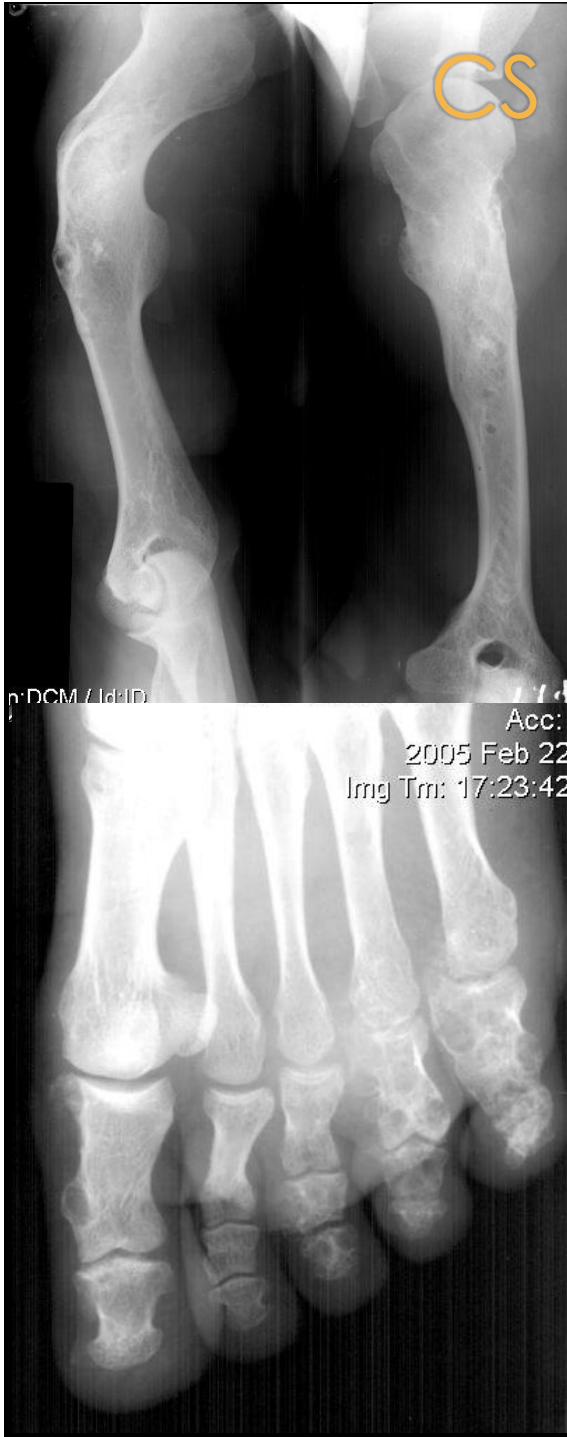SIZES ARE AI

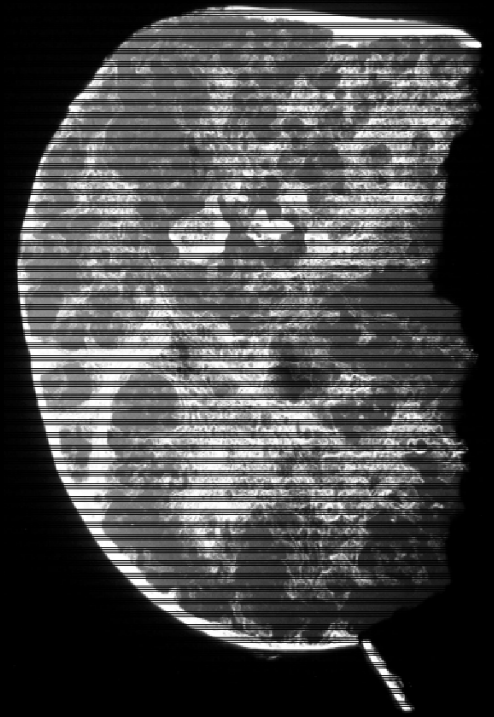
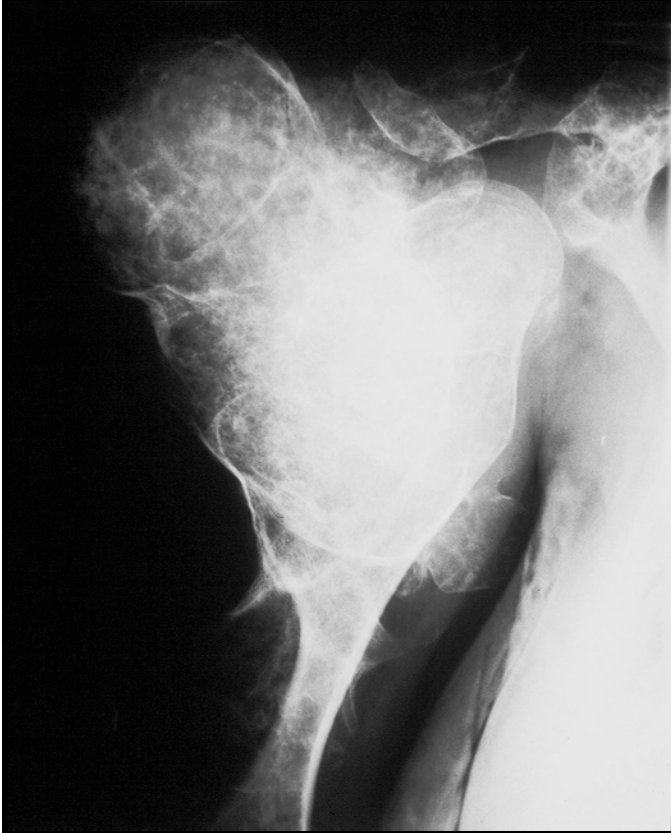
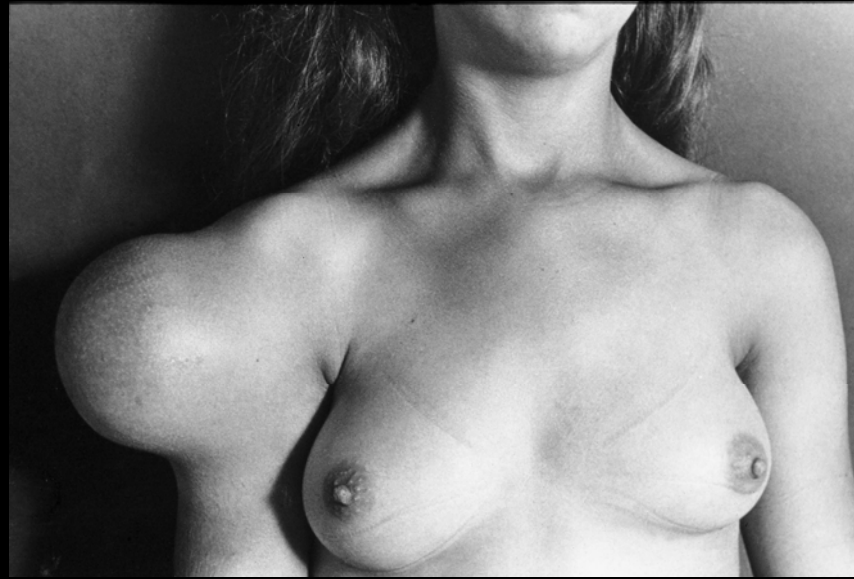
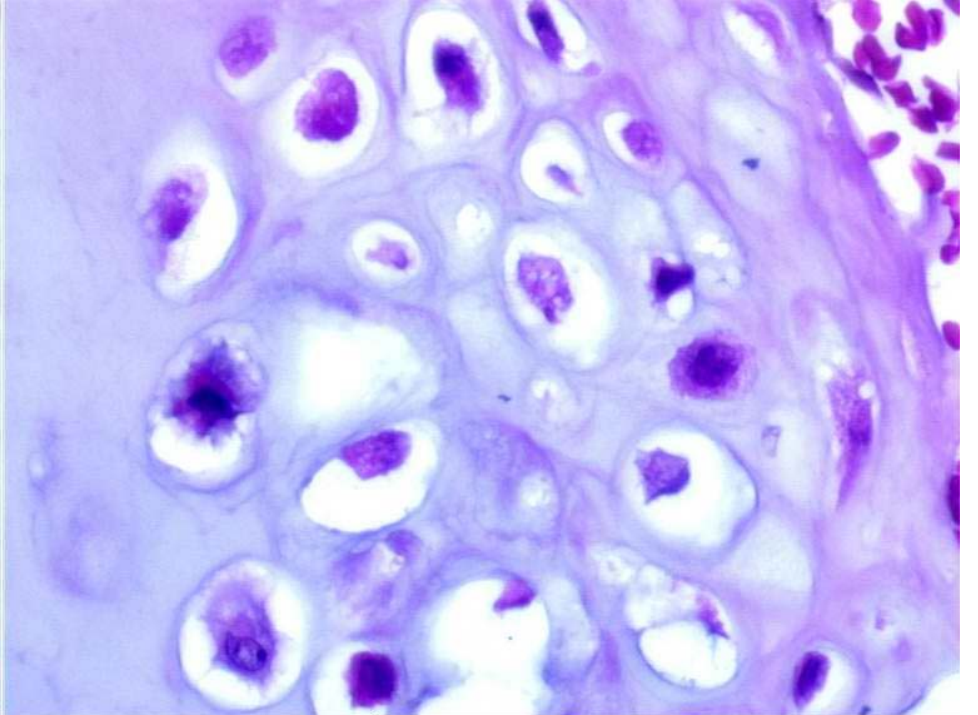
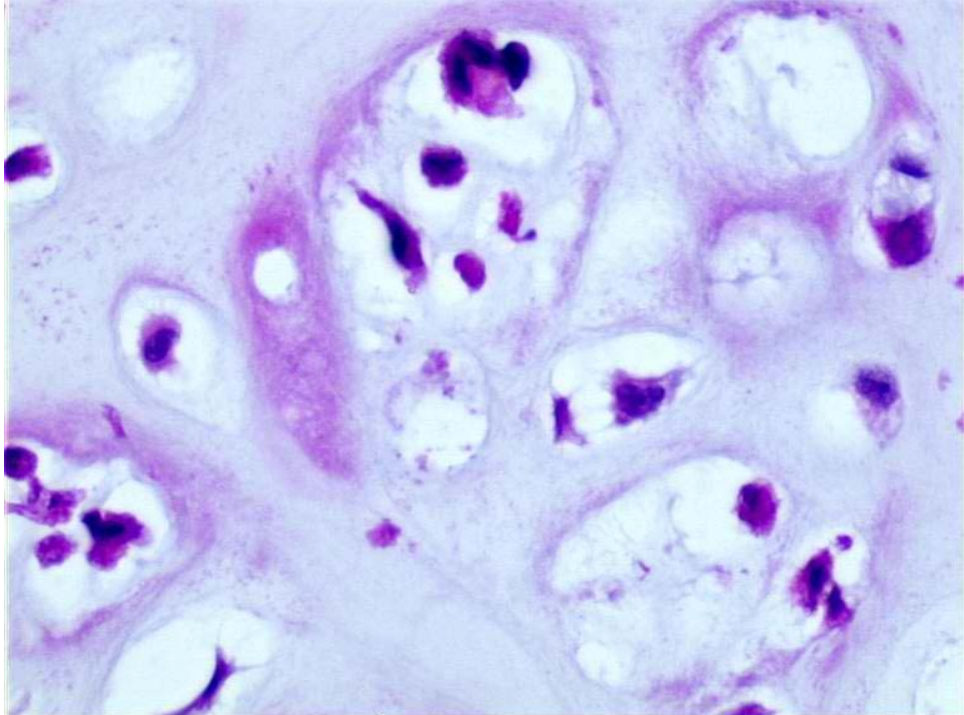
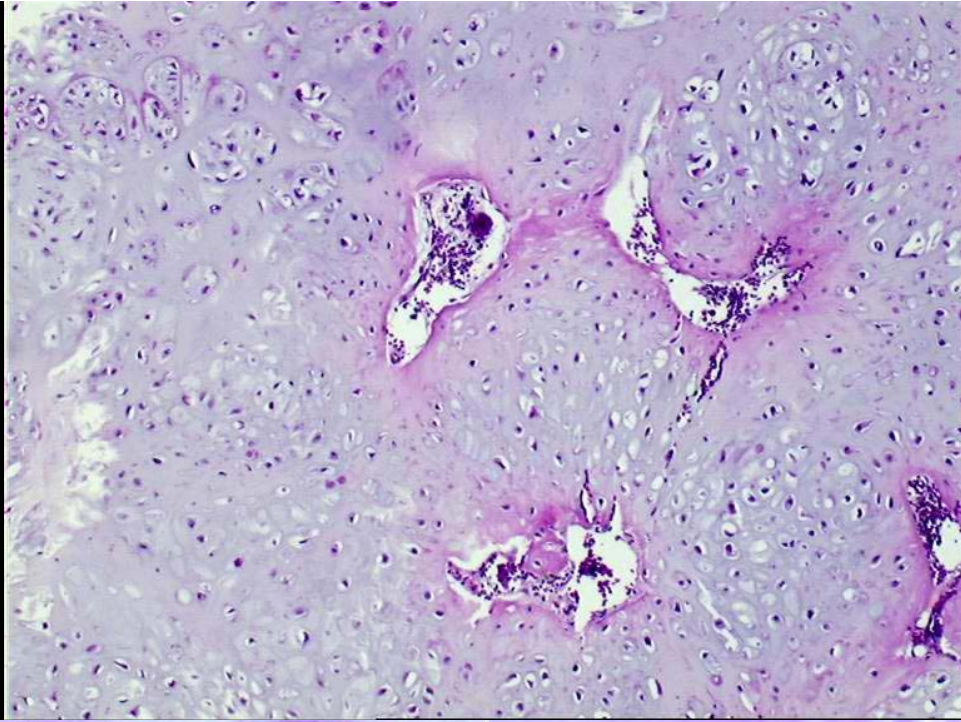




CS 2ARIO. EN ENCONDROMATOSIS







CHONDROSARCOMA

- CONTACTS CORTICAL
- ENDOSTEAL RESORPTION
- CORTICAL THICKENING
(PERMEATION OF DUCTS
OF HAVERS)
- CORTICAL EXPANSION

